



## Maternal serum eye drops to treat bilateral neurotrophic keratopathy in congenital corneal anesthesia: Case report and literature review

Giuseppe Giannaccare<sup>a,\*</sup>, Andrea Lucisano<sup>a</sup>, Marco Pellegrini<sup>b,c,d</sup>, Gianfranco Scuteri<sup>a</sup>,  
Alessandra Mancini<sup>a</sup>, Cristina Malaventura<sup>e</sup>, Massimo Busin<sup>b,c,d</sup>, Vincenzo Scoria<sup>a</sup>

<sup>a</sup> Department of Ophthalmology, University Magna Graecia of Catanzaro, Catanzaro, Italy

<sup>b</sup> Department of Ophthalmology, Ospedali Privati Forlì "Villa Igea", Forlì, Italy

<sup>c</sup> Istituto Internazionale per la Ricerca e Formazione in Oftalmologia (IRFO), Forlì, Italy

<sup>d</sup> Department of Morphology, Surgery and Experimental Medicine, University of Ferrara, Ferrara, Italy

<sup>e</sup> Department of Medical Sciences, Pediatric Section, University of Ferrara, Ferrara, Italy

### ARTICLE INFO

#### Keywords:

Congenital corneal anesthesia  
Neurotrophic keratopathy  
Serum eye drops  
Blood-derived eye drops

### ABSTRACT

**Purpose:** To report the feasibility and the successful outcomes of a pediatric neurotrophic keratopathy (NK) owing to congenital corneal anesthesia (CCA) treated with allogeneic serum eye drops obtained from the mother as the only therapy.

**Observations:** A 18-month-old girl with generalized pain insensitivity presented with a large epithelial defect in the right eye (RE) and superficial punctate keratopathy (SPK) in the left eye (LE). Corneal sensitivity was completely absent in both eyes (BE). Peripheral serum eye drops obtained from the mother was prescribed and administered every 2 hours in BE. Two weeks after the beginning of treatment, complete healing of the epithelial defect in the RE was obtained, while the severity of the SPK in the LE markedly improved; in parallel, conjunctival hyperemia disappeared in BE. The treatment was continued over the course of 3 months with good tolerability and neither signs of recurrence of the epithelial defect nor other complications were noted.

**Conclusions and Importance:** Allogeneic serum eye drops obtained from the mother are effective in treating pediatric NK owing to CCA. This treatment may represent a readily available and inexpensive option when topical nerve growth factor is unavailable or corneal neurotization is not feasible.

### 1. Introduction

Congenital corneal anesthesia (CCA) represents an umbrella term that includes a group of rare ocular surface disorders sharing the common spectrum of a deficiency of the trigeminal nervous pathway. This condition can be limited to the cornea, or be part of a more complex neurological syndrome affecting also other nervous pathways; sometimes, it may occur in association with multiple somatic abnormalities and congenital insensitivity to pain.<sup>1,2</sup> The impairment of corneal sensory innervation can be devastating as it triggers a detrimental loop with a decrease or absence of the trophic support to the cornea and an aberrant reduction of blinking and tear production, thus leading to damage to corneal epithelial cells, which are burdened by deficiency in spontaneous healing.<sup>3</sup> If not promptly recognized, this condition may rapidly progress towards a frank neurotrophic keratopathy (NK), leading to corneal ulceration and even perforation in more severe stages.<sup>4</sup>

Conventional therapy is based on supportive measures including tear substitutes, antibiotics, ointments and contact lenses aiming at preventing the progression of corneal damage and promoting epithelial healing. Surgical procedures like tarsorrhaphy, conjunctival flaps and amniotic membrane transplantation are usually reserved to refractory cases since they carry visual and aesthetic concerns. Tectonic or optical keratoplasty has poor outcomes due to the lack of innervation that is crucial for ensuring the postoperative epithelialization of the corneal graft.<sup>5</sup>

Two medical approaches with specific target on the root pathology are represented by the topical application of: i) nerve growth factor (NGF) and ii) blood derived eye drops. Although the efficacy in the setting of NK has been reported in a recent clinical trial,<sup>6</sup> NGF is approved and reimbursed only in patients older than 18-year-old, a recent case series focused on pediatric NK cases provided only modest support for this use.<sup>7</sup> Blood derived eye drops can be obtained from

\* Corresponding author. University of Magna Graecia, Viale Europa, 88100, Germaneto, Catanzaro, Italy.

E-mail address: [giuseppe.giannaccare@unicz.it](mailto:giuseppe.giannaccare@unicz.it) (G. Giannaccare).

<https://doi.org/10.1016/j.ajoc.2022.101446>

Received 21 June 2021; Received in revised form 15 February 2022; Accepted 16 February 2022

Available online 18 February 2022

2451-9936/© 2022 The Authors.

Published by Elsevier Inc.

This is an open access article under the CC BY-NC-ND license

(<http://creativecommons.org/licenses/by-nc-nd/4.0/>).

patients themselves (autologous products) or from donors (allogeneic), and represent an inexpensive and readily available option that delivers high contents of neurotrophic growth factors onto the ocular surface.<sup>8</sup>

The present report describes the feasibility and the successful outcomes of allogeneic serum eye drops obtained from the mother used as the only treatment in a case of bilateral NK in a child affected by CCA. Furthermore, we discuss the existing literature on pediatric NK owing to CCA, and review the armamentarium of current therapeutic options.

## 2. Case report

An 18-month-old girl suffering from generalized pain insensitivity presented to our attention with a 1-year history of intense redness in both eyes (BE). Before presentation, the child had undergone various ophthalmological examinations elsewhere, but a definite diagnosis had not been reached and topical antibiotics had been prescribed without success. Upon presentation, a diffuse conjunctival hyperemia was visible in BE; a large epithelial defect was present in the right eye (RE) (Fig. 1 Part A) and a diffuse superficial punctate keratopathy (SPK) in the left eye (LE). Visual acuity evaluation as well as accurate slit lamp examination were not possible due to lack of collaboration of the child. Cochet-Bonnet esthesiometry showed a complete lack of corneal sensitivity in BE. Once reached the diagnosis of CCA with bilateral NK (stage II in the RE and stage I in the LE according to Mackie classification),<sup>9</sup> all ongoing therapies were withdrawn and unpreserved tear substitutes were prescribed 4 times daily (washout period). Two weeks later, conjunctival hyperemia was less intense but the clinical feature remained approximately unchanged in BE. We explored the possibility of prescribing NGF eye drops that have been recently used with success in other similar pediatric cases,<sup>9,10</sup> but it was not possible to prescribe the drug and receive its reimbursement due to local regulatory issues. Therefore, we opted for the preparation and dispensation of allogeneic peripheral blood serum (PBS) eye drops obtained from the mother who was ABO-identical to the child. In order to avoid the risk of transmitting blood-borne diseases, mother's blood was tested for hepatitis and human immunodeficiency viruses before initiation of therapy. Maternal eye drops were prepared following a protocol described previously,<sup>11</sup> and prescribed according to the posology of 1 drop every 2 hours. Parents reported a good tolerability of the treatment, and as soon as 2 weeks after the beginning of the therapy, conjunctival hyperemia disappeared in BE with a complete healing of epithelial defect in RE and a significant reduction of the severity of SPK in LE. Once reached the NK healing, a dense corneal opacity involving the visual axis was noted (Fig. 1 Part B). Currently, 3 months after the beginning of PBS therapy, the child is continuing to use serum eye drops with good tolerability, the corneal healing is maintained in BE and the corneal opacity is becoming

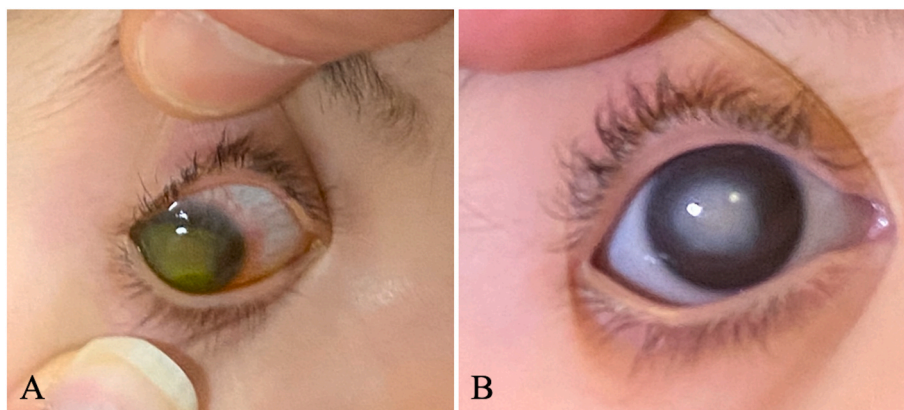
progressively slightly clearer in RE.

## 3. Discussion

Pediatric NK represents a real therapeutic challenge due to the lack of response to conventional treatment and the poor long-term anatomical and functional prognosis; furthermore, only off-label therapies are available to treat such condition in an effective way.<sup>10,11</sup> The onset of NK in the pediatric age adds also a further risk of severe amblyopia. Recent advances both in medical and surgical interventions have made corneal reinnervation and restoration of vision more easily attainable in pediatric patients.<sup>12</sup> Among novel medical therapies, contrasting results are reported for pediatric use of topical NGF. On one hand, various case reports showed the successful outcomes of this treatment in pediatric NK owing to different etiologies.<sup>10,13-17</sup> On the other hand, a recent case series (9 eyes of 8 pediatric patients) provided modest support for the efficacy of NGF in this setting, reporting an improvement of corneal ulcer stage in 5 eyes and best-corrected visual acuity in 2 eyes.<sup>7</sup> However, in our case it was not possible to use this drug and obtain its reimbursement due to local regulatory issues. Among new surgical procedures, the recent introduction of corneal neurotization opens new perspective in the treatment of (pediatric) NK.<sup>18-22</sup>

This technique can be performed according to various techniques (direct or indirect), and different nerves (mainly sural or great auricular nerve) can be used. The new endoscopic technique introduced for a less invasive approach appear particularly attractive for the pediatric setting. However, since the technique involves the graft of donor nerves from the patient him/herself or alternatively their transfer from a territory to another one, a systemic impairment of nervous pathways other than trigeminal nerve should be rule out before approaching to this kind of surgery. In our case, the child underwent genetic testing and the option of surgery has not been considered until the report is available.

The case reported herein shows the successful application of allogeneic PBS eye drops obtained from the mother as the only therapy in a pediatric case of bilateral NK owing to CCA. Maternal serum eye drops have been recently used with positive outcomes in the management of pediatric persistent epithelial defects owing to various ocular surface diseases.<sup>23</sup> In this retrospective case series by Kalthorn et al., 5 eyes of 4 patients with persistent corneal epithelial defects were treated with maternal serum drops. One patient of the series (patient #1) was affected by bilateral palsies of V and VII cranial nerves secondary to pontine tegmental cap dysplasia. Due to corneal anesthesia, the child experienced corneal ulcerations that were treated with contact lens and permanent lateral tarsorrhaphy. Once the healing was reached and the cornea presented bilateral scars with diffuse punctate epithelial erosions in BE, maternal serum eye drop was added to the existing regimen.



**Fig. 1.** Part A, Photograph showing a corneal epithelial defect stained with fluorescein (stage II neurotrophic keratopathy) in a child with congenital corneal anesthesia. Part B, After 2 weeks of treatment with allogeneic serum eye drops obtained from the mother, conjunctival hyperemia disappeared and the epithelial defect healed; however, a dense corneal opacity was detected.

There are two main aspects that differentiate our case from that one from Kalthorn et al.: i) maternal serum eye drop was used as the only therapy and not added to the existing treatment; ii) the cornea presented a large epithelial defect (Fig. 1 Part A) that healed with success thanks to the use of maternal serum (Fig. 1 Part B).

Our case confirms that allogeneic PBS obtained from the mother is well tolerated and effective also in the management of CCA, allowing the healing of recalcitrant NK. Therefore, maternal serum represents a readily available product useful to treat these challenging cases, particularly when the use of NGF is precluded by regulatory issues. Furthermore, unlike NGF that is approved and reimbursed (in adults) only for a single course of 2 months, PBS eye drops can be used for longer periods and various courses of therapy can be repeated, if needed.

Nowadays, several centers are moving towards allogeneic blood derived eye drops as they circumvent many of the issues associated with collecting autologous blood from patients with absolute or relative contraindications.<sup>24</sup> For instance, the use of autologous serum may be challenging in pediatric cases due to logistic issues that make difficult phlebotomy for collecting the blood. Another advantage of using such therapy in the pediatric population is that maternal serum eye drops are usually perceived by the parents as a highly acceptable option. However, it should be pointed out that the use of allogeneic sources also brings the questions of quality control and product consistency and this aspect has to be weighted with the benefits of the treatment.

#### 4. Conclusions

In conclusion, allogeneic PBS eye drops obtained from the mother allowed the healing of NK in a child affected by NK owing to CCA. This is a readily available and inexpensive product that can represent a feasible and effective option when NGF eye drops are not available and corneal neurotization is not feasible.

#### Intellectual property

We confirm that we have given due consideration to the protection of intellectual property associated with this work and that there are no impediments to publication, including the timing of publication, with respect to intellectual property. In so doing we confirm that we have followed the regulations of our institutions concerning intellectual property.

#### Research ethics

We further confirm that any aspect of the work covered in this manuscript that has involved human patients has been conducted with the ethical approval of all relevant bodies and that such approvals are acknowledged within the manuscript.

Written consent to publish potentially identifying information, such as details or the case and photographs, was obtained from the patient(s) or their legal guardian(s).

#### Patient consent

The patient's parent consented to publication of the case.

#### Authorship

All authors attest that they meet the current ICMJE criteria for Authorship.

#### Funding

No funding or grant support.

#### Declaration of competing interest

The authors declare no conflict of interest.

#### Acknowledgements

None.

#### References

- Ramaesh K, Stokes J, Henry E, Dutton GN, Dhillon B. Congenital corneal anesthesia. *Surv Ophthalmol.* 2007;52:50–60.
- Ramappa M, Chaurasia S, Chakrabarti S, Kaur I. Congenital corneal anesthesia. *J AAPOS.* 2014;18:427–432.
- Mantelli F, Nardella C, Tiberi E, Sacchetti M, Bruscolini A, Lambiasi A. Congenital corneal anesthesia and neurotrophic keratitis: diagnosis and management. *BioMed Res Int.* 2015;2015:805876.
- Versura P, Giannaccare G, Pellegrini M, Sebastiani S, Campos EC. Neurotrophic keratitis: current challenges and future prospects. *Eye Brain.* 2018;10:37–45.
- Dua H, Said DG, Messmer EM, et al. Neurotrophic keratopathy. *Prog Retin Eye Res.* 2018;66:107–131.
- Pflugfelder SC, Massaro-Giordano M, Perez VL, et al. Topical recombinant human nerve growth factor (Cenergermin) for neurotrophic keratopathy: a multicenter randomized vehicle-controlled pivotal trial. *Ophthalmology.* 2020;127:14–26.
- Hatcher JB, Soifer M, Morales NG, Farooq AV, Perez VL, Shieh C. Aftermarket effects of cenergermin for neuropathic keratopathy in pediatric patients. *Ocul Surf.* 2021;21:52–57.
- Giannaccare G, Versura P, Buzzi M, Primavera L, Pellegrini M, Campos EC. Blood derived eye drops for the treatment of cornea and ocular surface diseases. *Transfus Apher Sci.* 2017;56:595–604.
- Mackie IA. Neuroparalytic keratitis. In: Frauenfelder F, Roy FH, Meyer SM, eds. *Current Ocular Therapy.* Philadelphia: WB Saunders; 1995:452–454.
- Fausto R, Ceccuzzi R, Micheletti E, et al. A case report of paediatric neurotrophic keratopathy in pontine tegmental cap dysplasia treated with cenergermin eye drops. *Medicine.* 2020;99, e20816.
- Leto MG, Toro ME, Indemini PE, et al. Pediatric use of recombinant human nerve growth factor 20 µg/mL eye drops (Cenergermin) for bilateral neurotrophic keratopathy in congenital corneal anaesthesia. *Cornea.* 2021;40:228–231.
- Scelfo C, Mantagos IS. Neurotrophic keratopathy in pediatric patients. *Semin Ophthalmol.* 2021;36:289–295.
- Pedrotti E, Bonetto J, Cozzini T, Fasolo A, Marchini G. Cenergermin in pediatric neurotrophic keratopathy. *Cornea.* 2019;38:1450–1452.
- Papadopoulos K, Besgen V, Sekundo W. Successful treatment of a pediatric neurotrophic keratopathy with cenergermin. *Cornea.* 2021;40:516–518.
- Leto MG, Toro ME, Indemini PE, et al. Pediatric use of recombinant human nerve growth factor 20 µg/mL eye drops (cenergermin) for bilateral neurotrophic keratopathy in congenital corneal anaesthesia. *Cornea.* 2021;40:228–231.
- Riva I, Micheletti E, Fausto R, et al. Human recombinant nerve growth factor (Cenergermin) in a patient affected by primary congenital glaucoma with neurotrophic keratopathy. *Eur J Ophthalmol.* 2021. <https://doi.org/10.1177/1120672121999344>.
- Vaidyanathan U, Hopping GC, Liu HY, et al. Persistent corneal epithelial defects: a review article. *Med Hypothesis, Discov Innovation (MEHDI) Ophthalmol.* 2019;8:163–176.
- Rollon-Mayordomo A, Mataix-Albert B, Espejo-Arjona F, et al. Neurotrophic keratitis in a pediatric patient with goldenhar syndrome and trigeminal aplasia successfully treated by corneal neurotization. *Ophthalmic Plast Reconstr Surg.* 2021. <https://doi.org/10.1097/IOP.0000000000002086>.
- Fogagnolo P, Giannaccare G, Bolognesi F, et al. Direct versus indirect corneal neurotization for the treatment of neurotrophic keratopathy: a multicentre prospective comparative study. *Am J Ophthalmol.* 2020;220:203–214.
- Giannaccare G, Bolognesi F, Biglioli F, et al. In vivo and ex vivo comprehensive evaluation of corneal reinnervation in eyes neurotized with contralateral supratrochlear and supraorbital nerves. *Cornea.* 2020;39:210–214.
- Giannaccare G, Bolognesi F, Pellegrini M, et al. Corneal neurotization: a game-changing surgical procedure for neurotrophic keratopathy. *Cornea.* 2021. <https://doi.org/10.1097/ICO.0000000000002746>.
- Giannaccare G, Pellegrini M, Bolognesi F, et al. Spotlight on corneal neurotization. *Expet Rev Ophthalmol.* 2021. <https://doi.org/10.1080/17469899.2021.1895751>.
- Kalthorn AJ, Tawse KL, Shah AA, Jung JL, Gregory DG, Mc-Court EA. Maternal serum eye drops in the management of pediatric persistent corneal epithelial defects: a case series. *Cornea.* 2018;37:912–915.
- van der Meer P, Seghatchian J, Marks DC. Quality standards, safety and efficacy of blood-derived serum eye drops: a review. *Transfus Apher Sci.* 2016;54:164–167.