

## Ocular surface status in patients with hemifacial spasm under long-lasting treatment with botulinum A toxin: A comparative fellow eye study

Marco Pellegrini, Costantino Schiavi, Leonardo Taroni, Stefano Sebastiani, Federico Bernabei, Matilde Roda, Fabiana Moscardelli, Giuseppe Giannaccare

**Purpose:** The purpose of this study was to assess the effect of long-lasting botulinum A toxin injections on ocular surface parameters and to further investigate the relationship between these parameters and the duration of the treatment. **Methods:** In this retrospective study, patients with unilateral hemifacial spasm who were receiving botulinum A toxin injections for at least 1 year were analyzed. Healthy contralateral eyes acted as controls. The ocular surface examination included Ocular Surface Disease Index questionnaire, Schirmer test type I, tear film break-up time (TFBUT), tear osmolarity, corneal sensitivity, and corneal fluorescein staining. **Results:** Twenty-six patients (6 males and 20 females; mean age  $76.4 \pm 8.9$  years) were included in the study. The mean duration of the treatment was  $7.2 \pm 5.4$  years, and the mean frequency of injections was of one every  $3.3 \pm 0.4$  months. TFBUT, Schirmer test, and corneal sensitivity were significantly lower in the eye homolateral to hemifacial spasm compared with the contralateral one ( $5.9 \pm 3.2$  vs  $7.5 \pm 4.2$  s,  $P = 0.001$ ;  $6.2 \pm 3.4$  vs  $9.2 \pm 6.6$  mm,  $P = 0.031$ ;  $50.8 \pm 3.7$  mm vs  $52.3 \pm 2.9$  mm,  $P = 0.048$ , respectively). One month after the last injection, TFBUT further decreased from  $5.9 \pm 3.2$  to  $2.3 \pm 1.2$  s ( $P = 0.028$ ). A significant positive correlation was found between the duration of treatment and tear osmolarity ( $\rho = 0.542$ ,  $P = 0.025$ ). **Conclusion:** Patients with hemifacial spasm under long-lasting treatment with serial botulinum A toxin injections showed a reduction in tear film production and stability, as well as corneal sensitivity in the treated eye compared with the contralateral one. Tear film stability further decreased 1 month after the last injection.

**Key words:** Botulinum A toxin, dry eye, hemifacial spasm, ocular surface

Hemifacial spasm is a disorder characterized by involuntary clonic or tonic contractions of the muscles innervated by the facial nerve.<sup>[1]</sup> The disorder generally presents in the fifth or sixth decade of life with brief spasm of the orbicularis oculi, which gradually extend over years to other facial muscles of the affected half of the face. As opposed to blepharospasm, which is usually bilateral and symmetrical, hemifacial spasm is almost always unilateral, and the movements persist during sleep.<sup>[1,2]</sup>

The most common underlying etiology is an aberrant oretatic intracranial blood vessel, commonly the superior or the anterior inferior cerebellar artery, which compresses the facial nerve at the place where it exits the brainstem.<sup>[3,4]</sup> Less frequent causes include mass lesions in the cerebellopontine angle (e.g., Schwannomas, meningiomas, or arteriovenous malformation), trauma, and infections.<sup>[2]</sup>

Local botulinum toxin injection is the gold standard treatment for hemifacial spasm and blepharospasm. It is an exotoxin produced by the bacterium *Clostridium botulinum* that acts by blocking the cholinergic signal transmission at the synaptic junction. The toxin is injected in the orbicularis oculi and/or lower facial muscles resulting in a functional reversible paralysis. The treatment is safe and effective, with reported benefit in 85%–95% of patients;<sup>[5]</sup> however, efficacy is temporary, and repeated applications are required.<sup>[6]</sup>

Previous studies have reported that patients with periorcular facial dystonias may suffer from dry eye disease.<sup>[7,8]</sup> However, to date the literature is inconclusive regarding the effect of the botulinum toxin on the ocular surface system, particularly in case of long-lasting treatment.<sup>[9–13]</sup> Some studies reported increased tear volume,<sup>[14]</sup> whereas others reported no change or even decreased tear volume.<sup>[9,10,15–19]</sup>

The aim of this study was to assess the long-term effect of botulinum toxin A injection treatment on ocular surface parameters in patients with hemifacial spasm, and to further investigate the association between ocular surface alterations and the duration of the treatment.

### Methods

We retrospectively reviewed the medical charts of patients with hemifacial spasm who were receiving botulinum toxin A injections at the Ophthalmology Unit of the S. Orsola-Malpighi University Hospital (Bologna, Italy) in the period between January 2015 and June 2017. All the botulinum injections

This is an open access journal, and articles are distributed under the terms of the Creative Commons Attribution-NonCommercial-ShareAlike 4.0 License, which allows others to remix, tweak, and build upon the work non-commercially, as long as appropriate credit is given and the new creations are licensed under the identical terms.

**For reprints contact:** [reprints@medknow.com](mailto:reprints@medknow.com)

**Cite this article as:** Pellegrini M, Schiavi C, Taroni L, Sebastiani S, Bernabei F, Roda M, *et al.* Ocular surface status in patients with hemifacial spasm under long-lasting treatment with botulinum A toxin: A comparative fellow eye study. *Indian J Ophthalmol* 2019;67:1405-9.

Department of Ophthalmology, S.Orsola-Malpighi University Hospital, University of Bologna, Bologna, Italy

**Correspondence to:** Dr. Marco Pellegrini, Department of Ophthalmology, S.Orsola-Malpighi University Hospital, University of Bologna, Via Palagi 9, 40138 Bologna, Italy. E-mail: [marco.pellegrini@hotmail.it](mailto:marco.pellegrini@hotmail.it)

**Manuscript received:** 06.01.19; **Revision accepted:** 24.04.19

#### Access this article online

##### Website:

[www.ijo.in](http://www.ijo.in)

##### DOI:

10.4103/ijo.IJO\_41\_19

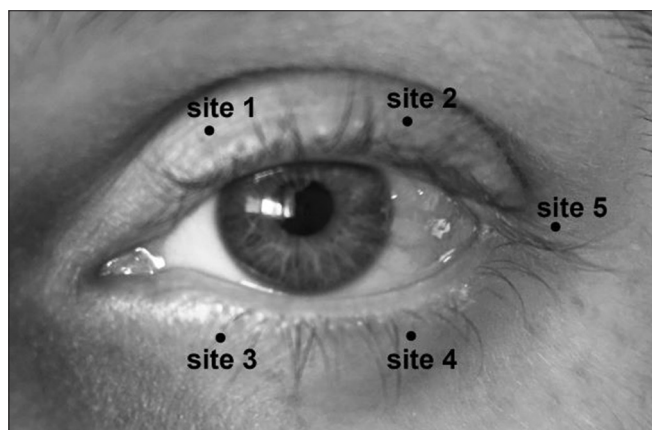
#### Quick Response Code:



were performed at our institution according to the following standardized protocol. Briefly, 100 IU of botulinum neurotoxin A (Botox; Allergan, Inc., Irvine, CA, USA) was diluted with 2 mL of unpreserved sterile saline to obtain a concentration of 5 IU per 0.1 mL. The toxin was injected subcutaneously into the selected sites using an insulin syringe and a 30-gauge needle, as previously described.<sup>[20]</sup> For the first session, all patients received 2.5 IU of botoxin five injection sites: 2–3 mm from the lid margin in the inner and outer thirds of the upper or lower eyelid and 5 mm from the temporal canthus [Fig. 1]. The injection patterns and doses were adjusted in the upcoming sessions according to the effectiveness and side effects of the previous session. In a minority of patients in who the spasm involved the lower part of the face, the zygomaticus major and the depressor angulioris muscles were also injected.

Only patients with unilateral hemifacial spasm under treatment with botulinum toxin for at least 1 year were included in the analysis. Exclusion criteria were as follows: history of any neurologic abnormalities other than hemifacial spasm, use of any topical or systemic drug associated with dry eye disease, diabetes, contact lens-wearing, ocular surgery, and ocular surface diseases. The contralateral nonaffected eyes acted as controls. The study was performed in accordance with the principles of the Declaration of Helsinki and was approved by the local Institutional Review Board.

Ocular surface workup was performed in both eyes before and 1 month after the last botulinum injection. The examination included Ocular Surface Disease Index (OSDI) questionnaire, slit-lamp biomicroscopy, tear osmolarity, corneal sensitivity, tear film break-up time (TFBUT), corneal staining, and Schirmer test type I. Briefly, tear osmolarity was calculated using the TearLab Osmolarity System (TearLab Corporation, San Diego, CA, USA), collecting a 50-nL tear sample from the inferior lateral tear meniscus. Corneal sensitivity was measured with a Cochet-Bonnet esthesiometer (Luneau, Prunay-le-Gillon, France). The TFBUT was measured after instillation of 2  $\mu$ L unpreserved 2% sodium fluorescein. Corneal staining was graded according to the National Eye Institute score as previously described.<sup>[21]</sup> Schirmer test was performed without anesthesia using validated sterile test strips (ContaCare Ophthalmics and Diagnostics, Gujarat, India) kept into the temporal lower conjunctival sac for 5 min.



**Figure 1:** Injection sites of botulinum toxin injection. Sites 1 and 2: inner and outer thirds of the upper lid; sites 3 and 4: inner and outer thirds of the lower lid; site 5: temporal canthus

Dry eye diagnosis was ascertained using TFOS DEWS II criteria.<sup>[22]</sup> Hyaluronic-based tear substitutes were prescribed to patients diagnosed with dry eye disease.

### Statistical analysis

The SPSS statistical software (SPSS Inc, Chicago, IL, USA) was used for data analysis. Values are expressed as mean  $\pm$  standard deviation. Wilcoxon test was used to compare ocular surface parameters between the affected and the contralateral eye. The correlations between the ocular surface parameters and the years of treatment with botulinum neurotoxin A were calculated using Spearman's correlation analysis. A  $P < 0.05$  was considered statistically significant.

### Results

In all, 26 patients with unilateral hemifacial spasm were included in the analysis. The demographic and clinical parameters of patients are reported in Table 1. The duration of the treatment with botulinum A injections ranged from 1 to 17 years, with a mean of  $7.2 \pm 5.4$  years. The mean frequency of treatment was of one injection every  $3.3 \pm 0.4$  months. The mean OSDI was  $12.12 \pm 6.77$ , and 12 patients (46.2% of the total) had pathological OSDI score ( $>13$ ). Eleven patients (42.3%) were diagnosed as having dry eye using TFOS DEWS II criteria. Eight patients (30.8%) were using hyaluronic-based tear substitutes at the time of the analysis.

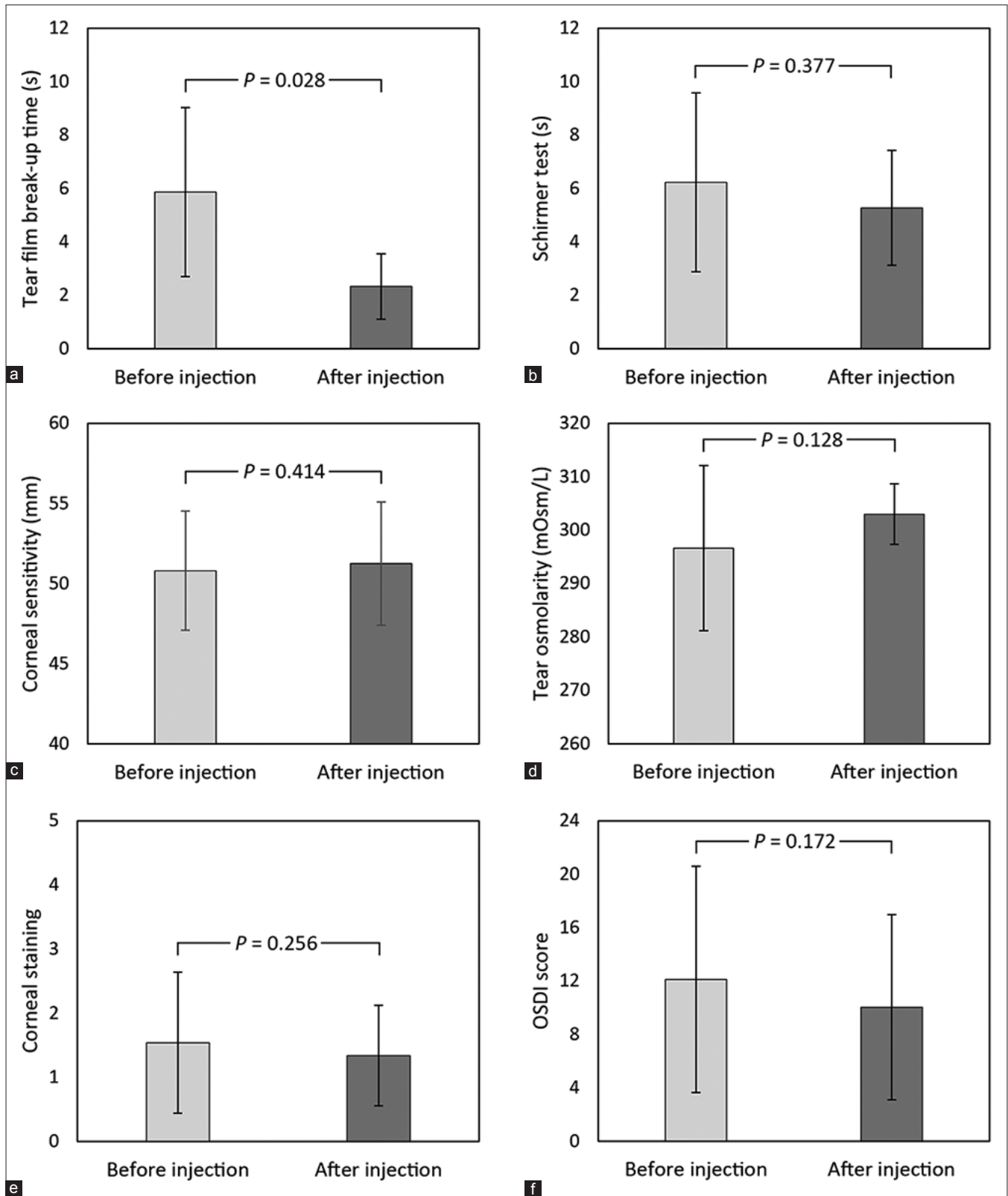
The ocular surface parameters of both homolateral and contralateral eyes before botulinum A toxin injections are reported in Table 2. TFBUT was significantly lower in the homolateral compared with contralateral eye ( $P = 0.001$ ). Similarly, a significant difference between the two eyes was found for Schirmer test and corneal sensitivity ( $P = 0.031$  and  $P = 0.048$ , respectively); conversely, no significant difference was found for tear osmolarity and corneal fluorescein staining ( $P = 0.081$  and  $P = 0.656$ , respectively).

One month after the botulinum injection, in the homolateral eye TFBUT significantly decreased from  $5.9 \pm 3.2$  to  $2.3 \pm 1.2$  s ( $P = 0.028$ ); conversely, no significant changes were observed for Schirmer test, corneal sensitivity, tear osmolarity, corneal fluorescein staining and OSDI score (always  $P > 0.05$ ) [Fig. 2]. In the contralateral eye, none of the ocular surface parameters changed significantly after the injection (always  $P > 0.05$ ).

**Table 1: Demographic and clinical parameters of patients under long-lasting treatment with botulin A toxin injection**

Characteristic	No.
Patients	26
Males	6
Females	20
Age (years)	$76.4 \pm 8.9$
Duration of treatment (years)	$7.2 \pm 5.4$
Frequency of injections (months)	$3.3 \pm 0.4$
OSDI score	$12.1 \pm 8.5$
Dry eye diagnosis	11
Usage of tear substitutes	8

Data are expressed as mean  $\pm$  standard deviation. OSDI=Ocular Surface Disease Index



**Figure 2:** Ocular surface parameters before and 1 month after injection of botulinum toxin: (a) tear film break-up time; (b) Schirmer test; (c) corneal sensitivity; (d) tear osmolarity; (e) corneal staining; (f) OSDI score

Spearman's correlation analysis revealed a significant positive correlation between the duration of treatment and tear osmolarity ( $\rho = 0.542, P = 0.025$ ). In addition, the latter

parameter was also negatively correlated with Schirmer test ( $\rho = -0.442, P = 0.030$ ). No significant correlations were found among the duration of treatment and age, TFBUT, Schirmer

**Table 2: Ocular surface parameters in the eye homolateral to the hemifacial spasm and in the contralateral one**

Characteristic	Homolateral eye	Contralateral eye	P
TFBUT (s)	5.9±3.2	7.5±4.2	0.001
Schirmer test (mm/5')	6.2±3.4	9.2±6.6	0.031
Corneal sensitivity (mm)	50.8±3.7	52.3±2.9	0.048
Tear osmolarity (mOsm/L)	296.6±15.5	294.8±22.4	0.081
Corneal staining (NEI score)	1.5±1.1	1.3±1.0	0.656

Data are expressed as mean±standard deviation, TFBUT=Tear film break-up time; NEI=National Eye Institute

test, corneal sensitivity, corneal fluorescein staining and OSDI score.

## Discussion

Dry eye disease has been recently defined as a “multifactorial disease of the ocular surface accompanied by ocular symptoms in which tear film instability and hyperosmolarity, ocular surface inflammation, and neurosensory abnormalities play etiological roles.”<sup>[23]</sup> There is an increasing body of evidence suggesting an association between dry eye disease and periocular facial dystonias, which include hemifacial spasm and blepharospasm.<sup>[11,17]</sup> On the contrary, previous studies evaluating the effects of botulinum injection on the ocular surface produced conflicting results: two works described a short-term improvement of certain ocular surface parameters after botulinum treatment,<sup>[11,15]</sup> while another study reported a lack of improvement of dry eye disease after injection.<sup>[10]</sup> This inconsistency may result from the diverse techniques used for botulinum toxin injection, and differing dosages and dilutions of BTX. Nevertheless, the recent TFOS DEWS II Iatrogenic Report included the botulinum toxin among the nonsurgical ophthalmic procedures causing iatrogenic dry eye.<sup>[13]</sup>

Furthermore, all these studies examined the ocular surface changes before and after one single botulinum injection, even though hemifacial spasm is a chronic disease requiring multiple repeated applications of the toxin over the years. Thus, the long-term effect of this treatment on the ocular surface status is still unknown.

As opposed to blepharospasm, hemifacial spasm is almost always unilateral, and this feature allowed us to use the contralateral nontreated eyes as controls to evaluate the long-term effect of the toxin on the ocular surface health of the treated eye. We identified clinically significant ocular surface changes in the eye homolateral to the hemifacial spasm under long-lasting treatment with botulinum toxin. In particular, tear film production and stability as well as corneal sensitivity were worse in the treated eye compared with the contralateral one. These alterations were accompanied by significant ocular discomfort symptoms in almost half of the patients. Thus, a significant percentage of patients were classified as affected from dry eye disease. One month after the injection, tear film stability further decreased to even worse values.

However, since all the patients with hemifacial spasm included in the present analysis were under botulinum toxin

treatment, we cannot exclude that the dry eye disease may be caused by the underlying disorder rather than by the treatment itself, and further examination on patients with hemifacial spasm naive to treatment should be conducted to clarify this issue. In fact, forceful eyelid closure and increased blink rate in hemifacial spasm may result in dysfunctional lubricity with consequent blink-related microtrauma and chronic ocular surface inflammation.<sup>[24,25]</sup> As a consequence, Lu *et al.* reported higher levels of proinflammatory cytokines in the tear fluid of patients with blepharospasm.<sup>[15]</sup>

On the other hand, botulinum toxin injection itself may determine significant long-term effects on the ocular surface homeostasis. In fact, the toxin may impair the function of meibomian glands, which receive parasympathetic fibers from the pterygopalatine ganglion and excrete the meibomian oil by the contraction of the muscle of Riolan. Therefore, the pharmacological effect of botulinum toxin on neuromuscular junctions and autonomic cholinergic transmission may suppress the meibomian gland function, resulting in tear film instability and hyperevaporative dry eye.<sup>[9]</sup> In addition, the treatment may cause bulbar exposure and lagophthalmos, and thus contribute to the tear film instability.<sup>[9]</sup> Furthermore, decreased blink rate and/or incomplete blinking caused by botulinum may lead to inadequate lipid distribution and exposure of the inferior ocular surface and increased evaporation. In this study, we detected lower tear film stability in the eye homolateral to the hemifacial spasm, which further decreased after the botulinum injection. The decrease in tear production may be a direct consequence of the pharmacological effect of botulinum toxin. Indeed, the toxin blocks the autonomic cholinergic transmission, and decreased lacrimation is a typical symptom of the systemic manifestation of botulism.<sup>[26]</sup> Two previous studies reported a short-term decrease in tear production after botulinum injection.<sup>[9]</sup> We detected lower Schirmer test values in the eye homolateral to hemifacial spasm compared with the contralateral one. This suggests that long-lasting botulinum toxin treatment in patients with hemifacial spasm may determine chronic impairment of tear production. We did not detect a further significant reduction of Schirmer test after the last injection, but the pathological values of this test already before the injection may have hampered this evaluation.

Corneal sensitivity was lower in the eye homolateral to the hemifacial spasm. A previous study demonstrated lower corneal sensitivity and sub-basal nerve density in patients with blepharospasm, and the authors hypothesized that the afferent arm of the blink reflex may be impaired in blepharospasm.<sup>[27]</sup> Botulinum toxin A is known to inhibit unmyelinated C-fiber nociceptors in the meninges and was proven effective in diminishing photophobia and dry eye symptoms.<sup>[12]</sup> It is unclear whether the reduction in corneal sensitivity was due to an alteration of the afferent neural pathways caused by the disease itself or by the effect of the toxin.

Tear hyperosmolarity is considered one of the core mechanisms of dry eye disease.<sup>[28]</sup> Although tear osmolarity values were within physiological range and did not significantly differ between the two eyes, we found a significant correlation between tear osmolarity and the duration of treatment, with higher osmolarity values recorded in patients who were receiving botulinum injections for several years.

The main limitation of the study is the lack of a control group including patients with hemifacial spasm not receiving toxin injection. As discussed above, this limitation did not allow us to establish whether the ocular surface impairment was related to the hemifacial spasm itself, to the toxin, or to a combination of both mechanisms. However, we believe that it would have been unethical to create a control group by withholding the therapy with botulinum toxin that has proven efficacy and that is able to improve patient's quality of life. Another potential limitation is that the majority of the patients included in the study were females, and the hormone status could influence the ocular surface status, particularly in postmenopausal women.<sup>[29]</sup>

## Conclusion

In conclusion, patients with hemifacial spasm treated with serial botulinum A injections showed a reduction in tear film production and stability, as well as corneal sensitivity in the eye homolateral to the spasm. Tear film stability further decreased 1 month after the last toxin injection. Since dry eye disease may complicate the course of hemifacial spasm under treatment with botulinum toxin, ocular surface work-up should be recommended, and the usage of tear substitutes, aiming at moistening and nourishing the ocular surface, should be considered in the presence of dry eye signs and symptoms.

## Financial support and sponsorship

Nil.

## Conflicts of interest

There are no conflicts of interest.

## References

1. Abbruzzese G, Berardelli A, Defazio G. Hemifacial spasm. *Handb Clin Neurol* 2011;100:675-80.
2. Yalitho TC, Jankovic J. The many faces of hemifacial spasm: Differential diagnosis of unilateral facial spasms. *Mov Disord* 2011;26:1582-92.
3. Campos-Benitez M, Kaufmann AM. Neurovascular compression findings in hemifacial spasm. *J Neurosurg* 2008;109:416-20.
4. Tan EK, Chan LL, Lim SH, Lim WE, Khoo JB, Tan KP. Role of magnetic resonance imaging and magnetic resonance angiography in patients with hemifacial spasm. *Ann Acad Med Singapore* 1999;28:169-73.
5. Jitpimolmarid S, Tiamkao S, Laopaiboon M. Long term results of botulinum toxin type A (Dysport) in the treatment of hemifacial spasm: A report of 175 cases. *J Neurol Neurosurg Psychiatry* 1998;64:751-7.
6. Kenney C, Jankovic J. Botulinum toxin in the treatment of blepharospasm and hemifacial spasm. *J Neural Transm* 2008;115:585-91.
7. Elston JS, Marsden CD, Grandas F, Quinn NP. The significance of ophthalmological symptoms in idiopathic blepharospasm. *Eye (Lond)* 1988;2:435-9.
8. Defazio G, Abbruzzese G, Aniello MS, Di Fede R, Esposito M, Fabbrini G, *et al.* Eye symptoms in relatives of patients with primary adult-onset dystonia. *Mov Disord* 2012;27:305-7.
9. Ho MC, Hsu WC, Hsieh YT. Botulinum toxin type A injection for lateral canthal rhytids: Effect on tear film stability and tear production. *JAMA Ophthalmol* 2014;132:332-7.
10. Horwath-Winter J, Bergloeff J, Floegel I, Haller-Schober EM, Schmut O. Botulinum toxin A treatment in patients suffering from blepharospasm and dry eye. *Br J Ophthalmol* 2003;87:54-6.
11. Park DI, Shin HM, Lee SY, Lew H. Tear production and drainage after botulinum toxin A injection in patients with essential blepharospasm. *Acta Ophthalmol* 2013;91:108-12.
12. Diel RJ, Kroeger ZA, Levitt RC, Sarantopoulos C, Sered H, Martinez-Barrizonte J, *et al.* Botulinum toxin A for the treatment of photophobia and dry eye. *Ophthalmology* 2018;125:139-40.
13. Gomes JAP, Azar DT, Baudouin C, Efron N, Hirayama M, Horwath-Winter J, *et al.* TFOS DEWS II iatrogenic report. *Ocul Surf* 2017;15:511-38.
14. Spiera H, Asbell PA, Simpson DM. Botulinum toxin increases tearing in patients with Sjogren's syndrome: A preliminary report. *J Rheumatol* 1997;24:1842-3.
15. Lu R, Huang R, Li K, Zhang X, Yang H, Quan Y, *et al.* The influence of benign essential blepharospasm on dry eye disease and ocular inflammation. *Am J Ophthalmol* 2014;157:591-7.
16. Kocabeyoglu S, Sekeroglu HT, Mocan MC, Muz E, Sanac AS. Ocular surface alterations in blepharospasm patients treated with botulinum toxin A injection. *Eur J Ophthalmol* 2014;24:830-4.
17. Price J, O'Day J. A comparative study of tear secretion in blepharospasm and hemifacial spasm patients treated with botulinum toxin. *Ophthal Plast Reconstr Surg* 1993;13:67-71.
18. Arat YO, Yen MT. Effect of botulinum toxin type a on tear production after treatment of lateral canthal rhytids. *Ophthal Plast Reconstr Surg* 2007;23:22-4.
19. Matarasso SL. Decreased tear expression with an abnormal Schirmer's test following botulinum toxin type A for the treatment of lateral canthal rhytids. *Dermatol Surg* 2002;28:149-52.
20. Gunes A, Demirci S, Koyuncuoglu HR, Tok L, Tok O. Corneal and tear film changes after botulinum toxin-A in blepharospasm and hemifacial spasm. *Cornea* 2015;34:906-10.
21. Sook C, Park IK. Reliability of 4 clinical grading systems for corneal staining. *Am J Ophthalmol* 2014;157:1097-102.
22. Wolffsohn JS, Arita R, Chalmers R, Djalilian A, Dogru M, Dumbleton K, *et al.* TFOS DEWS II diagnostic methodology report. *Ocul Surf* 2017;15:539-74.
23. Craig JP, Nichols KK, Akpek EK, Caffery B, Dua HS, Joo CK, *et al.* TFOS DEWS II definition and classification report. *Ocul Surf* 2017;15:276-83.
24. Cher I. Blink-related microtrauma: When the ocular surface harms itself. *Clin Exp Ophthalmol* 2003;31:183-90.
25. Giannaccare G, Versura P, Sebastiani S, Fariselli C, Pellegrini M, Campos EC. Dry eye disease in strabismus patients: Does eye deviation harm ocular surface? *Med Hypotheses* 2018;111:15-8.
26. Naumann M, Jost WH, Toyka KV. Botulinum toxin in the treatment of neurological disorders of the autonomic nervous system. *Arch Neurol* 1999;56:914-6.
27. Fayers T, Shaw SR, Hau SC, Ezra DG. Changes in corneal aesthesiometry and the sub-basal nerve plexus in benign essential blepharospasm. *Br J Ophthalmol* 2015;99:1509-13.
28. Bron AJ, De Paiva CS, Chauhan SK, Bonini S, Gabison EE, Jain S, *et al.* TFOS DEWS II pathophysiology report. *Ocul Surf* 2017;15:438-510.
29. Versura P, Giannaccare G, Campos EC. Sex-steroid imbalance in females and dry eye. *Curr Eye Res* 2015;40:162-75.