



ELSEVIER

Contents lists available at [ScienceDirect](https://www.sciencedirect.com)

Trauma Case Reports

journal homepage: www.elsevier.com/locate/tcr

Case Report

Atypical periprosthetic femur fracture on an underestimated atypical femoral pattern. A case report

Gaetano Caruso^{a,b,*}, Nicola Corradi^a, Tommaso Amoroso^a, Ilaria Martini^a, Vincenzo Lorusso^a, Leo Massari^{a,b}^a Orthopedic and Traumatology Unit, Sant'Anna University Hospital of Ferrara, Via Aldo Moro 8, 44124 Cona, Ferrara, Italy^b Department of Neurosciences and Rehabilitation, University of Ferrara, Via Luigi Borsari 46, 44121, Ferrara, Italy

ARTICLE INFO

Keywords:

Atypical periprosthetic femur fracture
Atypical femur fracture
Bisphosphonates therapy
Total hip arthroplasty

ABSTRACT

Case: Atypical fracture patterns, especially to the femur midshaft, have begun emerging since long-term bisphosphonate use was introduced. The same fracture pattern could arise around prosthetic hip implant, but the literature reports few cases regarding atypical periprosthetic femur fracture on previous total hip arthroplasty implant in patients on long-term bisphosphonate therapy. To our knowledge we report here the first case of atypical periprosthetic femur fracture arising after total hip arthroplasty implant on a previously identified but underestimated atypical femur pattern.

Conclusion: Surgeons should never underestimate an atypical femur pattern on x-rays and always relate groin and thigh pain to hip pathology before performing total hip arthroplasty.

Introduction

The atypical femur fracture (AFF) is now a well-defined clinical entity. Its pathogenesis is multifactorial, and includes biological factors such as the use and duration of bisphosphonates, proton pump inhibitors and corticosteroids, and mechanical factors such as a varus femoral neck-shaft angle and physical stress on the lateral cortex of the femur [1,2]. Reports by the American Society for Bone and Mineral Research (ASBMR) task force have established specific diagnostic criteria for atypical femur fracture (Table 1) [3,4]. As an AFF evolves over time, patients typically refer prodromal symptoms including dull or aching pain in the groin or thigh, and radiographs prior to fracture highlight lateral cortical thickening [5].

Similar patterns have been reported around total hip arthroplasty (THA) implants. Nonetheless, periprosthetic atypical femur fracture (PAFF) is not included in ASBMR definition, even if the major AFF features are present [3,4,6–8]. Indeed, few cases of PAFF following total hip arthroplasty (THA) have been reported in literature [8,9], the prevalence of PAFF is still unknown, and there is no consensus regarding its treatment.

We present here a case of PAFF following THA implant with a known previous lateral femur cortex thickening in a female patient with a past medical history of long-term alendronate therapy. To our knowledge, this is the first such case to be reported.

The patient was informed that data concerning the case would be submitted for publication, and she provided consent.

* Corresponding author at: Via Aldo Moro 8, 44124 Cona, Ferrara, Italy.

E-mail address: crstgn@unife.it (G. Caruso).

<https://doi.org/10.1016/j.tcr.2021.100407>

Accepted 6 February 2021

Available online 10 February 2021

2352-6440/© 2021 The Author(s). Published by Elsevier Ltd. This is an open access article under the CC BY-NC-ND license

(<http://creativecommons.org/licenses/by-nc-nd/4.0/>).

Case report

A 76-year-old woman presented to our hospital with an atypical fracture to the left femur shaft in September 2014. The patient complained of experiencing pain in her left thigh for several months, which had worsened in recent weeks; her recent fall had been caused by intense pain. She had been on alendronate therapy for 9 years due an osteoporotic vertebral compression fracture (twelfth dorsal). She also had a history of other significant conditions, namely atrial fibrillation, asthma, hypercholesterolemia and arterial hypertension. X-rays revealed transverse midshaft AFF, according to the ASBMR definition (Fig. 1). Closed reduction and internal fixation by intramedullary nail (Stryker T2, Stryker©, USA) was performed. Post-operative x-ray of the left femur highlighted correct limb length, rotation and alignment, but x-ray of the contralateral femur showed a femoral involvement consisting of lateral cortical thickening and lateral beak of the diaphyseal cortex (Fig. 2). Nuclear bone scintigraphy, performed a few days later, showed an abnormal area of increased bone up-take in the right femur (Fig. 3). Due to the presence of an atypical pattern in the contralateral femur too, we advised the patient to undergo prophylactic nailing of the right femur; however, the patient refused because at the time she felt no pain in her right thigh.

Two months after surgery, the nail was dynamized and full weight-bearing was allowed (Fig. 4). Clinical and radiographic follow-up was performed at 1, 2, 4 and 6 months after surgery. At 4-month follow-up, fracture healing was confirmed radiographically, and the patient was able to walk with full weight-bearing without pain (Fig. 5). At 6-month follow-up the patient reported slight pain in her right thigh, mid-shaft localized, independent from the hip movement and not referred from the joint (Fig. 6). We blamed the AP rather than the mild-moderate hip osteoarthritis so we offered again prophylactic intramedullary nailing fixation. The patient still refused.

The patient was not seen again until December 2018, when she was readmitted to our hospital after falling following sudden right thigh pain. Radiographic examination revealed APFF (type C according to the Vancouver classification) on the previous AP (Fig. 7). The patient told us that in April 2015 she had been to another specialist at a different hospital due to worsening of the pain in her right thigh and hip stiffness, and that in June 2015 she had undergone total right hip arthroplasty (THA) (Fig. 8). After surgery (THA), the pain symptoms had improved, but not completely abated.

We performed an open reduction and internal fixation with a locking plate (Iron lady - Intrauma©, Italy), screws and metallic cerclages (Fig. 9). Blood tests for bone metabolism showed: serum calcium level of 8.5 mg/dl (range 8.6–10.5), phosphorous 6.5 mg/dl (range 2.5–4.5), ALP 180 UI/l (20–120), PTH 171 pg/ml (12–88), and 25-OH vitamin D 20.2 ng/ml (range 20–100); the urinary calcium concentration was 21 mg/die (range 50–400). Teriparatide and oral vitamin D osteoporosis therapy was begun at hospital discharge, and biophysical stimulation with pulsed electromagnetic field (Bostim SPT ® IGEA S.p.A., Italy) was performed for 3 months. Weight-bearing was not allowed until 2-month follow-up, then partial weight-bearing was allowed for the next 4 months. At 6 months, full weight-bearing was allowed, and x-rays confirmed bone healing. 1-year follow-up confirmed APFF union (Fig. 10).

Discussion

AFF represent a clinical challenge. For displaced or incomplete fractures, it is agreed that nailing is the gold standard, but the management of AP (endosteal reaction and focal lateral cortex hypertrophy) in the absence of clear signs of fracture and atypical periprosthetic fractures is more controversial. This type of fracture has increased in recent years, with an incidence that, according to some studies, is estimated to be between 5% and 11% of all periprosthetic fractures [7,10].

Recent literature confirms that PAFF exist, and are associated with the duration of bisphosphonate therapy, even though PAFF are not provided for within the criteria defined by the ASBMR; the transverse orientation of the fracture, periosteal reaction, unicortical fracture and prodromal symptoms differentiate PAFFs from periprosthetic femoral fractures (PFFs), and liken them to AFFs [4,7,10].

Numerous reports describe cases of PFF with characteristics of AFF, but generally these are cases of implanted THA before the onset of the atypical fracture pattern. No cases of THA implantation on a known atypical femur pattern have yet been reported.

The correlation between bisphosphonates and AFF has been recognised for a long time. Bisphosphonates inhibit bone resorption by suppressing osteoclast activity, and it has been hypothesized that atypical fracture is promoted by bisphosphonates accumulating in areas in which a stress fracture arises; they suppress the subsequent intracortical remodelling and impair normal bone healing [7,8,11–14].

Table 1
Atypical femur fracture ASBMR 2014 revised diagnostic criteria.

ASBMR criteria: four of five major criteria should be observed, additional minor criteria are not necessary for diagnosis but could be observed in association to the major criteria	
Major criteria	<ul style="list-style-type: none"> • Fracture associated with minimal or no trauma in a fall from a standing height or less • Fracture line originates at the lateral cortex and is substantially transverse in its orientation, although it may become oblique as it progresses medially across the femur • Complete fractures extended through both cortices and are associated with a medial spike; incomplete fractures involve only lateral cortex • The fracture is not comminuted • Localized periosteal or endosteal thickening of the lateral cortex is present at the fracture site (beaking or flaring)
Minor criteria	<ul style="list-style-type: none"> • Generalized increased in cortical thickness of the femoral diaphyses • Unilateral or bilateral prodromal symptoms such as dull or aching pain in the groin or thigh • Bilateral incomplete or complete femoral diaphysis fractures • Delayed fracture healing

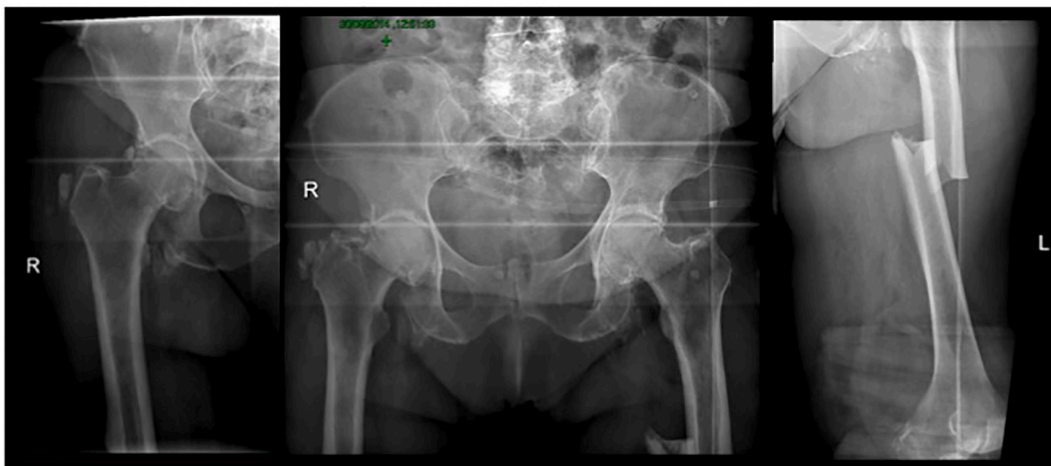


Fig. 1. Radiographs demonstrating atypical femur shaft fracture on left limb and atypical pattern on right femur. Right: right femur antero-posterior x-rays. Centre: antero-posterior pelvis. Left: left femur antero-posterior x-rays. (September 2014).

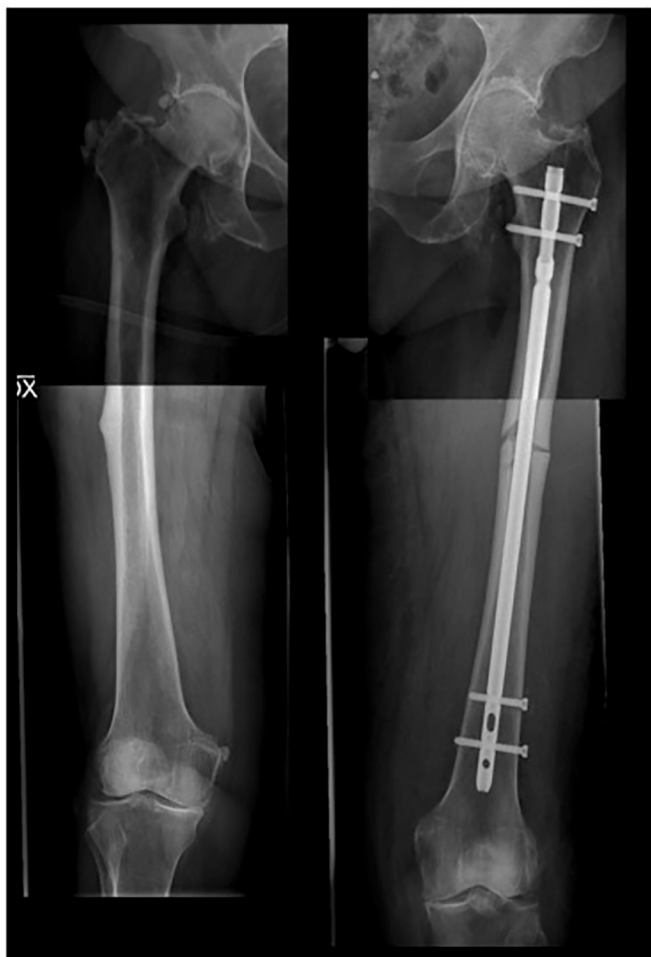

Fig. 2. Post-operative radiographs after left femur intramedullary nailing pointing-out atypical pattern features on right femoral shaft. Right: right femur antero-posterior x-rays. Left: left femur antero-posterior x-rays.

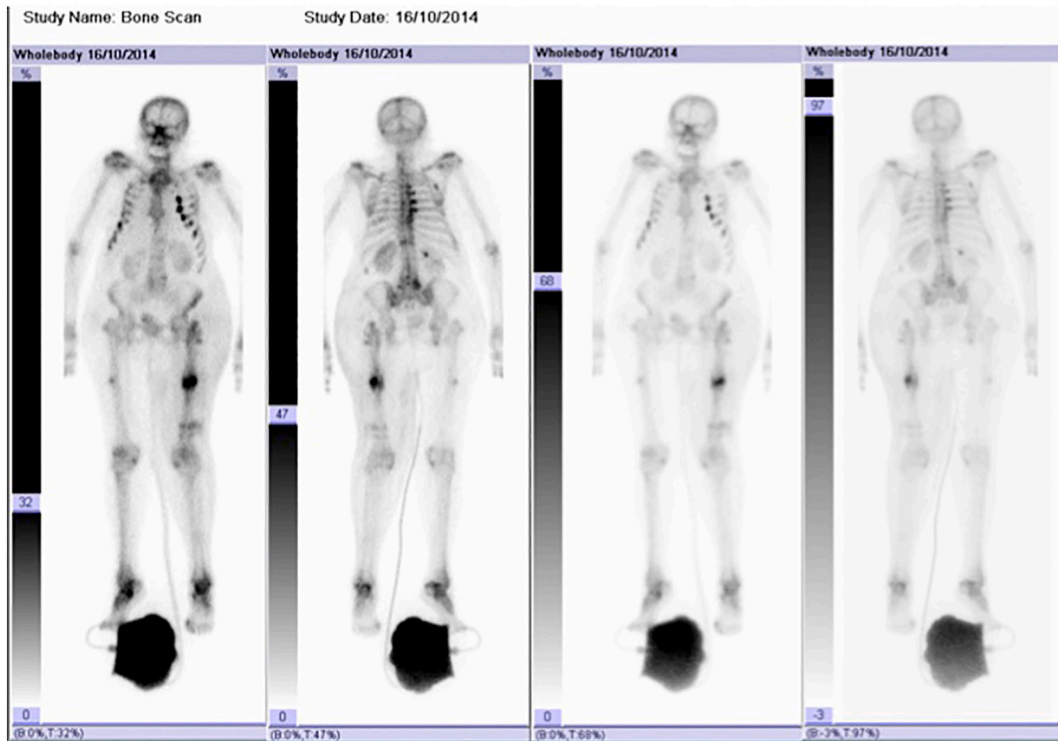


Fig. 3. Abnormal area of increased bone up-take in the right femoral midshaft on nuclear bone scintigraphy.

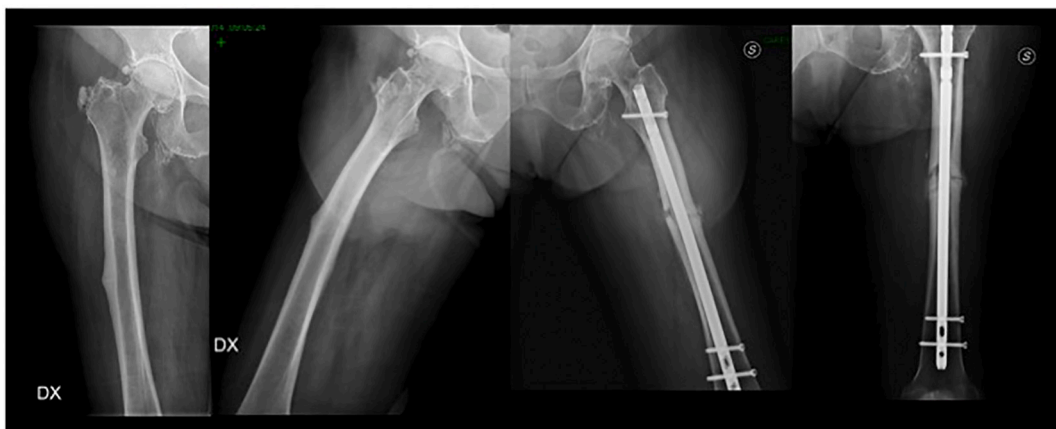

Fig. 4. 2-months follow-up radiographs. Right: right femur cortical beak. Left: dynamized intramedullary nail.

The fracture pattern in the case reported here was a Vancouver type C, usually treated by open reduction and internal fixation with plate, metallic wire cerclage and screws. Alternative options are intramedullary retrograde nail or longer femoral component, depending of type of PFF. [15] Adequate plate length and proper positioning are essential for stable fixation to avoid stress and the risk of union failure, and the surgeon should bear in mind that outcomes in AFF and PAFF are poorer than in ordinary fractures, being associated with higher risks of malunion, delayed union and non-union [14,16,17]. Corten et al. reported a mean union time of 6.4 months for typical PFF, and it is therefore reasonable to assume that PAFF might require a longer time for union than AFF and PFF [18]. As reported by Tanaka et al., the risk of non-union is also high [19]. For this reason, we immediately started therapy with teriparatide, oral vitamin D and capacitive coupling electric fields to promote fracture healing [20,21].

We describes the case of a THA that was implanted on the right femur due to groin pain, irrespective of the presence of a previously diagnosed AP. Probably underestimating the AP on x-rays and relating thigh and groin pain to hip osteoarthritis led to the Vancouver C PFF. Indeed, an atypical femur pattern decreases the elastic resistance of bone, especially in the lateral cortex. It is likely, therefore,

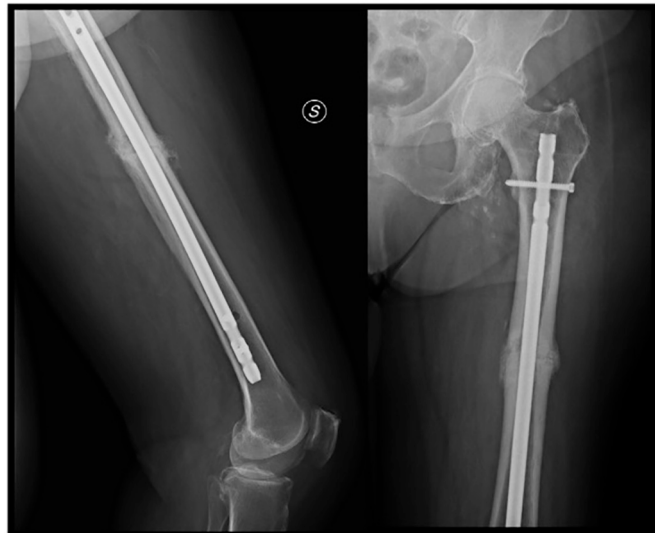


Fig. 5. Left femur 4-months follow-up radiographs showing bone healing with callus formation. Left: lateral left femur. Right: antero-posterior left femur.

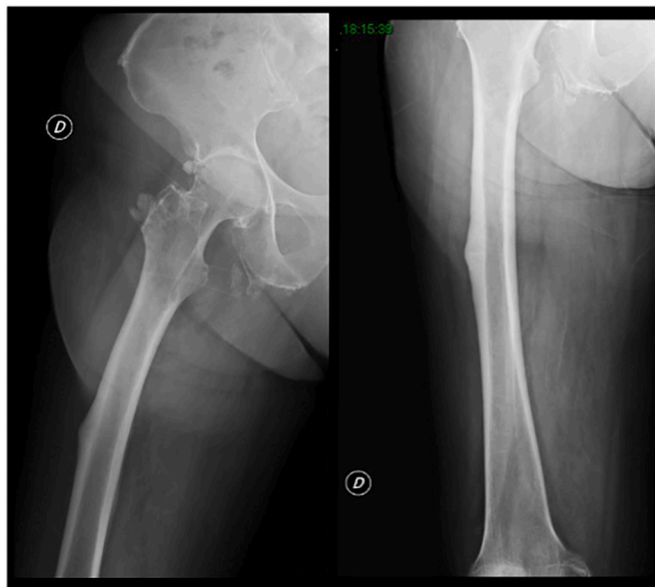


Fig. 6. Femoral shaft atypical pattern (6-month follow up). Right: right femur lateral view. Left: right femur antero-posterior view.

that the hip prosthesis enhanced the amount of mechanical stress on a well-developed weak point and thereby promoted PAFF. Maybe a different solution could have avoided the stress arising at the AFF level, as example plating the lesion with or without a strut graft or use a longer stem. It is reported that dull pain in the groin and thigh are prodromal AFF symptoms that could mislead diagnosticians [3,7,13,14]. Thigh and groin pain are not always related to hip pathologies. Before THA implantation, thorough patient assessment is strongly recommended. Surgeons should evaluate past medical history, bearing in mind that long-term bisphosphonate therapy should greatly raise suspicions of AFF or AP. THA pre-operative planning must therefore include a careful hip and femur x-ray examination to detect lateral beak and cortical thickening.

An atypical femur model under an arthritic hip should raise many questions to the surgeon about the most appropriate treatment. The patient must be evaluated with a multidisciplinary approach that includes an expert to evaluate bone metabolic conditions. The joint replacement should also be considered as a “difficult hip” as a conventional stem alone could promote AFF because of the gap between the tip of the stem and the atypical model. Surgeons must be aware of the risk of PAF in patients undergoing THR since the

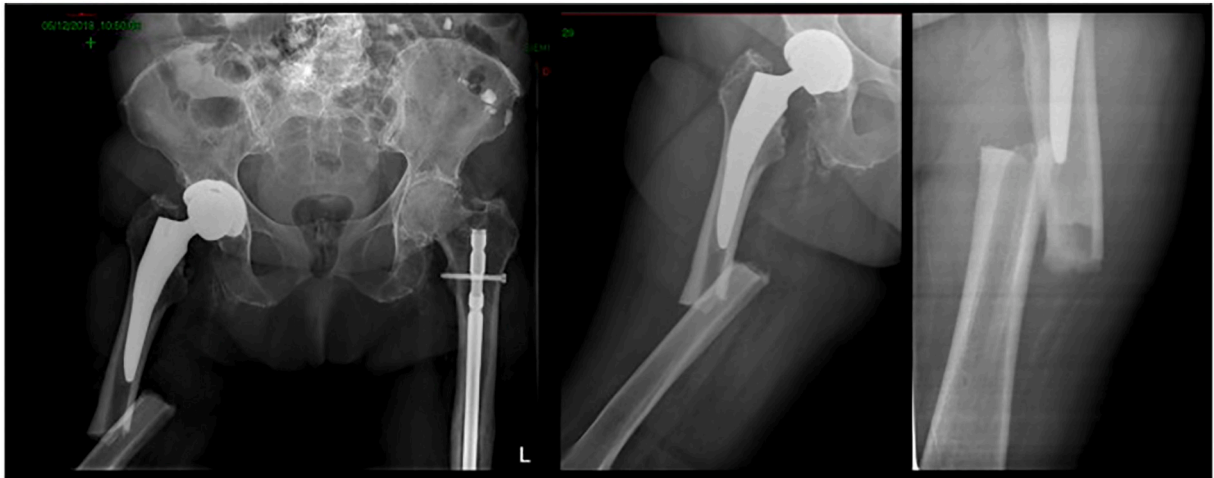


Fig. 7. Vancouver C atypical periprosthetic femur fracture. Right: pelvis antero-posterior. Centre: right femur antero-posterior. Left: lateral right femoral shaft. (December 2018).

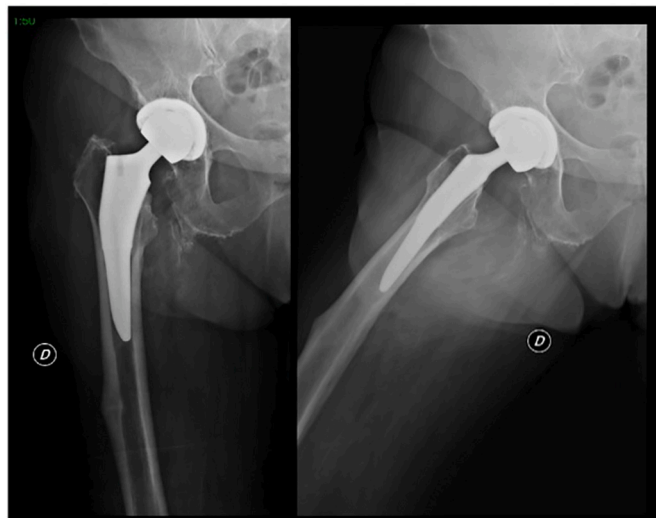


Fig. 8. Right THA implant and atypical pattern on ipsilateral limb. Right: antero-posterior view. Left: lateral view. (April 2015).

symptoms of prodromal AFF can mislead the diagnosis and, consequently, adequate treatment. An accurate evaluation of long-term bisphosphonate therapy and properly X rays are mandatory, including femoral shaft, to recognize an AP and plan the best solution.

Ethical approval

All procedures performed in studies involving human participants were in accordance with the ethical standards of the institutional research committee (Institute ethics committee vide letter no. AIIMS(R)-ethics/1995) and with the 1964 Helsinki declaration and its later amendments or comparable ethical standards.

Funding

The authors received no funding/grant from any external agencies.

Consent to participate

Written and informed consent were taken from the patient for using his individual and clinical data for publication and research purposes.

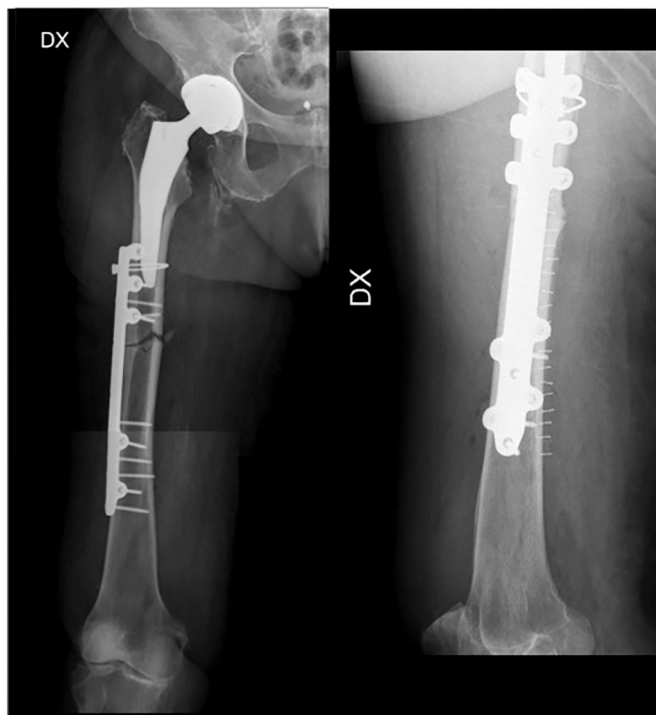

Fig. 9. Immediate post-operative radiographs demonstrating open reduction and internal fixation of periprosthetic atypical fracture. Right: antero-posterior right femur. Left: lateral right femur.

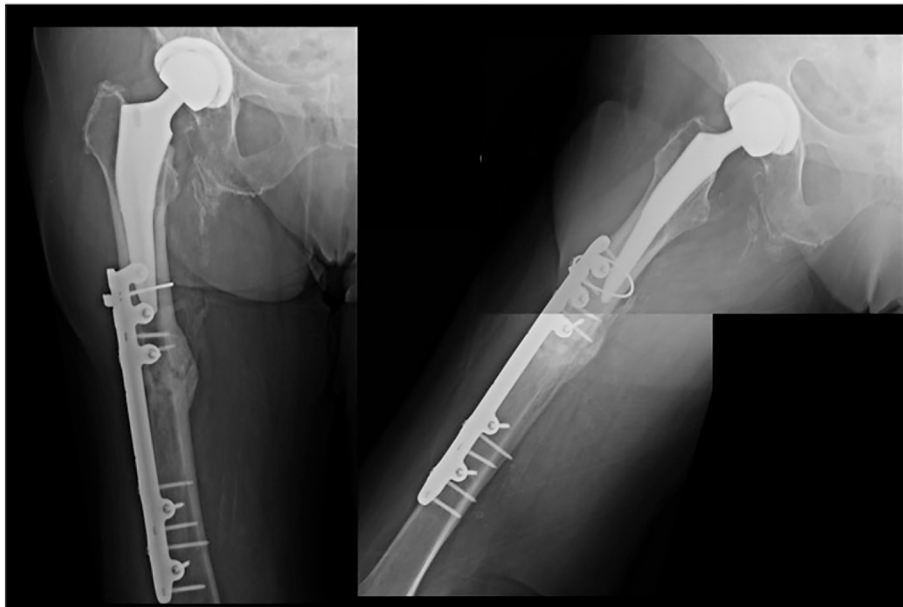


Fig. 10. Periprosthetic atypical fracture 1-year follow-up: excellent bone healing and callus formation. Right: antero-posterior femur. Left: lateral femur.

CRediT authorship contribution statement

GC - Conceptualisation; Data curation.
 NC, TA, IM - Methodology; Writing - original draft.
 VL - Review and editing.
 LM - Supervision.

Declaration of competing interest

The authors declare that they have no conflict of interest.

References

- [1] N. Kharwadkar, B. Mayne, J.E. Lawrence, V. Khanduja, Bisphosphonates and atypical subtrochanteric fractures of the femur, *Bone Joint Res.* 6 (3) (2017) 144–153.
- [2] J.E. Hagen, A.N. Miller, S.M. Ott, et al., Association of atypical fractures with bisphosphonates use by patients with varus hip geometry, *J. Bone Joint Surg. Am.* 96 (22) (2014) 1905–1909.
- [3] E. Shane, D. Burr, P.R. Ebeling, B. Abrahamsen, R.A. Adler, T.D. Brown, A.M. Cheung, F. Cosman, J.R. Curtis, R. Dell, D. Dempster, T.A. Einhorn, H.K. Genant, P. Geusens, K. Klaushofer, K. Koval, J.M. Lane, F. McKiernan, R. McKinney, A. Ng, J. Nieves, R. O’Keefe, S. Papapoulos, H.T. Sen, M.C. van der Meulen, R. S. Weinstein, M. Whyte, American Society for Bone and Mineral Research, Atypical subtrochanteric and diaphyseal femoral fractures: report of a task force of the American Society for Bone and Mineral Research, *J. Bone Miner. Res.* 25 (11) (2010) 2267–2294 (Erratum in: *J. Bone Miner. Res.* 2011;26(8):1987).
- [4] E. Shane, D. Burr, B. Abrahamsen, R.A. Adler, T.D. Brown, A.M. Cheung, F. Cosman, J.R. Curtis, R. Dell, D.W. Dempster, P.R. Ebeling, T.A. Einhorn, H.K. Genant, P. Geusens, K. Klaushofer, J.M. Lane, F. McKiernan, R. McKinney, A. Ng, J. Nieves, R. O’Keefe, S. Papapoulos, T.S. Howe, M.C. van der Meulen, R.S. Weinstein, M.P. Whyte, Atypical subtrochanteric and diaphyseal femoral fractures: second report of a task force of the American Society for Bone and Mineral Research, *J. Bone Miner. Res.* 29 (1) (2014) 1–23.
- [5] B.A. Lenart, D.G. Lorch, J.M. Lane, Atypical fractures of the femoral diaphysis in postmenopausal women taking alendronate, *N. Engl. J. Med.* 358 (12) (2008) 1304–1306.
- [6] C.M. Capecci, N.C. Tejwani, Bilateral low-energy simultaneous or sequential femoral fractures in patients on long-term alendronate therapy, *J. Bone Joint Surg. Am.* 91 (11) (2009) 2556–2561.
- [7] S.A. MacKenzie, R.T. Ng, G. Snowden, M.F.R. Powell-Bowns, A.D. Duckworth, C.E.H. Scott, Periprosthetic atypical femoral fractures exist and are associated with duration of bisphosphonate therapy, *Bone Joint J.* 101-B (10) (2019) 1285–1291.
- [8] V. Bottai, G. De Paola, F. Celli, I. Lazzarini, V. Ortenzi, A.G. Naccarato, G. Guido, R. Capanna, S. Giannotti, Histological study of atraumatic periprosthetic fractures: does atypical periprosthetic fracture exist? *Clin. Cases Miner. Bone Metab.* 14 (2) (2017) 136–139.
- [9] K.J. Lee, B.W. Min, H.K. Jang, H.U. Ye, K.H. Lim, Periprosthetic atypical femoral fracture-like fracture after hip arthroplasty: a report of three cases, *Hip Pelvis.* 27 (3) (2015) 187–191.
- [10] J.T. Leclerc, L. Michou, F. Vaillancourt, et al., Prevalence and characteristics of atypical periprosthetic femoral fractures, *J. Bone Miner. Res.* 34 (1) (2019) 83–92.
- [11] P. Franceschetti, M. Bondanelli, G. Caruso, M.R. Ambrosio, V. Lorusso, M.C. Zatelli, L. Massari, E.C. Degli Uberti, Risk factors for development of atypical femoral fractures in patients on long-term oral bisphosphonate therapy, *Bone.* 56 (2) (2013) 426–431.
- [12] T.A. Einhorn, Y. Bogdan, P. Tornetta 3rd., Bisphosphonate-associated fractures of the femur: pathophysiology and treatment, *J. Orthop. Trauma* 28 (7) (2014) 433–438.
- [13] M.R. Allen, D.B. Burr, Bisphosphonate effects on bone turnover, microdamage, and mechanical properties: what we think we know and what we know that we don’t know, *Bone.* 49 (1) (2011) 56–65.
- [14] L. Froberg, A. Troelsen, M. Brix, Periprosthetic Vancouver type B1 and C fractures treated by locking-plate osteosynthesis: fracture union and reoperations in 60 consecutive fractures, *Acta Orthop.* 83 (6) (2012) 648–652.
- [15] G. Caruso, L. Milani, T. Marko, V. Lorusso, M. Andreotti, L. Massari, Surgical treatment of periprosthetic femoral fractures: a retrospective study with functional and radiological outcomes from 2010 to 2016, *Eur. J. Orthop. Surg. Traumatol.* 28 (5) (2018) 931–938.
- [16] M.L. Prasarn, J. Ahn, D.L. Helfet, J.M. Lane, D.G. Lorch, Bisphosphonate-associated femur fractures have high complication rates with operative fixation, *Clin. Orthop. Relat. Res.* 470 (8) (2012) 2295–2301.
- [17] J. Schilcher, High revision rate but good healing capacity of atypical femoral fractures. A comparison with common shaft fractures, *Injury.* 46 (12) (2015) 2468–2473.
- [18] K. Corten, F. Vanrykel, J. Bellemans, et al., An algorithm for the surgical treatment of periprosthetic fractures of the femur around a well-fixed femoral component, *JBJS (British)* 91 (11) (2009) 1424–1430.
- [19] S. Tanaka, T. Fukui, K. Oe, T. Matsumoto, et al., A periprosthetic femoral fracture with characteristics of atypical femoral fracture, *Case Rep. Orthop.* 2019 (2019) 1275369.
- [20] L. Massari, G. Caruso, V. Sollazzo, S. Setti, Pulsed electromagnetic fields and low intensity pulsed ultrasound in bone tissue, *Clin. Cases Miner. Bone Metab.* 6 (2) (2009) 149–154.
- [21] L. Massari, R. Osti, V. Lorusso, S. Setti, G. Caruso, Biophysical stimulation and the periprosthetic bone: Is there a rationale in the use of pulsed electromagnetic fields after a hip or knee implant? *J. Biol. Regul. Homeost. Agents* 29 (4) (2015) 1013–1015.