

# **On the antiquity of Legg-Calvé-Perthes disease: skeletal evidence in Iron Age Italy.**

V.S. Manzon<sup>a</sup>, Z. Ferrante<sup>b</sup>, M. Giganti<sup>b</sup>, E. Gualdi-Russo<sup>a</sup>

a) Department of Biomedical and Surgical Specialties Sciences, University of Ferrara, Ferrara, Italy

b) Department of Morphology, Surgery and Experimental Medicine, University of Ferrara, Ferrara, Italy

## **Abstract**

Legg-Calvé-Perthes is a very rare disease involving childhood osteochondrosis of the femoral head due to interruption of its blood supply. The etiology is unknown. The signs of the pathology are well described in the literature but few paleopathological cases have been reported, mostly dating from Late Antiquity to Early Middle Ages. Here we report on morphometric and radiological analyses of a skeleton from the Etruscan necropolis of Spina (Ferrara, Italy, 6<sup>th</sup>-3<sup>rd</sup> century BCE), to our knowledge the most ancient case of Legg-Calvé-Perthes Disease published thus far.

## **Introduction**

The occurrence of Legg-Calvé-Perthes Disease in antiquity is poorly documented. During recent decades, palaeopathology has become more interdisciplinary, particularly in its technical aspects (Évinger et al., 2011). Thus, radiological and computed tomography (CT) investigations can aid in making reliable diagnoses of bone pathologies.

The present study involves a palaeopathological examination of human skeletal remains from the important Etruscan site of Spina in northern Italy. The lack of health and biological data for the

Etruscans of this site contrasts starkly with the rich literature on Etruscan archaeological findings (Berti and Guzzo, 1993; Berti et al., 2004; Muggia, 2004). Spina was an Iron Age village in the present-day province of Ferrara in Italy. Founded by the Etruscans at the end of the 6<sup>th</sup> century BCE in a strategic area where the Po River entered the upper Adriatic Sea, it was used as an emporium for commercial trade with the Greeks until the end of the 3<sup>rd</sup> century BCE. The site was discovered at the beginning of the last century and excavated in several phases from 1922 to 1965, yielding more than 4000 graves (both inhumations and cremations): the extraordinary amount of fine Greek pottery recovered represents the symposium kit that would accompany the deceased into the afterlife (Berti and Guzzo, 1993; Guzzo, 2003).

This palaeopathological study contributes to the knowledge of the health of Etruscans, since very few anthropological studies on the Spina Etruscans have been published (Masotti et al., 2013; Manzon et al., 2014; Manzon and Gualdi-Russo, 2015). The pathology, diagnosed by means of different approaches (anthropological, radiological and computed tomography [CT]), is Legg-Calvé-Perthes disease (LCPD). It involves childhood osteochondrosis of the femoral head caused by interruption of its blood flow, leading to extensive avascular necrosis of the subchondral bone (Smrcka et al., 2009). The etiology of the initial ischemic episode that interrupts normal vascularization is unknown, although some authors have suggested a traumatic origin (Herrerín and Gallarda, 2012; Ortner, 2003). Because of the interrupted blood flow, bone resorption in the subchondral area is greater than deposition; the femoral head becomes biomechanically weak and fragmentation or pathological fracture can take place (Salter, 1999). After some time, revascularization can take place in the whole area leading to “progressive substitution” of avascular bone and remodeling (Chaudhry et al., 2014; Herrerín and Gallarda, 2012). During the remodeling process the femoral head becomes flattened into a mushroom shape because of the forces acting upon it and the lack of endochondral growth. The bone density of the femoral head usually returns to

normal. Generally, there is no significant dislocation of the center of the head with respect to the neck. The acetabulum is often deformed, flattened and broadened, and is affected by osteoarthritis.

LCPD occurs unilaterally in 90% of cases (Ortner, 2003). It usually begins early, between the ages of 2 and 14 years, and boys are more commonly affected than girls (about 5 times more often). No familial or hereditary factors have been associated with the pathology, even though it seems to be 1-20% more frequent in the families of affected children (Herrerín and Gallarda, 2012) and uncommon in some ethnic groups but particularly affecting some Asian and European groups (Chaudhry et al., 2014; Ortner, 2003).

This paper focuses on one individual out of the more than 300 Etruscans from Spina (Ferrara, Italy, 6<sup>th</sup>-3<sup>rd</sup> century BCE) and describes the osteological characters used for an unambiguous diagnosis of the pathology. As LCPD is a very uncommon disease (estimated prevalence in the general pediatric population 1 per 740 boys and 1 in 3700 girls according to Zhang et al., 2011), very few cases have been documented in ancient populations (Herrerín and Gallarda, 2012; Ortner, 2003; Smrcka et al., 2009). This Etruscan individual likely represents the most ancient case of LCPD published up today in the world.

## **Materials and methods**

The skeleton is from the individual buried in grave 92D of Valle Pega (the funerary area of Spina was traditionally divided into Valle Trebba and Valle Pega). The general preservation is quite poor, with post-mortem damage. Of the skull, only the parietals are completely preserved, while the occipital bone, the right temporal with mastoid process and the mandible with P<sub>2</sub> and M<sub>1</sub> are preserved in fragments. Only the 1<sup>st</sup>, 3<sup>rd</sup> and 4<sup>th</sup> cervical, 2<sup>nd</sup> thoracic, 4<sup>th</sup> and 5<sup>th</sup> lumbar and 1<sup>st</sup> sacral vertebrae are preserved in fragments. The appendicular skeleton is represented by a fragment of the right scapula preserving the glenoid fossa, the left clavicle lacking

the sternal end, both humeri, radii and ulnae with fragmented epiphyses, the capitata and first phalanx of the 3<sup>rd</sup> digit of the right hand, two left metacarpals, pelvic fragments (right *os coxae* preserving only the acetabulum and left coxal preserving the acetabulum and pubic symphyseal surface), both fragmented femora, both tibiae with fragmented epiphyses, a diaphyseal fragment of the left fibula, both tali and the left navicular.

Sex was determined by means of standard morphological (Acsádi and Nemeskéri, 1970;

Ferembach et al., 1980) and metric criteria (Bass, 1995; Cattaneo and Grandi, 2004; Demoulin,

1972; France, 1998; Gualdi-Russo, 2007; Krogman and İşçan, 1986; Mac Laughlin and Oldane,

1992; Rühli et al., 2006). Age at death was estimated by means of ectocranial suture closure (Meindl and Lovejoy, 1985), dental wear (Brothwell, 1981; Lovejoy, 1985) and pubic symphysis modifications (Burns, 1999; Brooks and Suchey, 1990). Stature was estimated following Trotter and Gleser (1952, 1958) on the left radius (the only completely preserved long bone) using a Broca osteometric board.

The skeleton showed pathological lesions on the left hip, involving both the femoral head and acetabulum (Fig. 1). The lesions were analyzed morphologically, metrically, radiologically and by CT. The macroscopic morphological analysis was based on the specific palaeopathological literature (Smrcka et al., 2009; Herrerín and Gallarda, 2012; Ortner, 2003). Several metric traits were recorded on both femora with a non-stretchable tape (circumferences) and a sliding caliper (longitudinal and transverse diameters) following Martin and Saller (1957) and Wilder (1920). The femoral collo-diaphyseal angle was measured with a digital osteogoniometer (Gualdi-Russo and Russo, 1995).

The femora and pelvic bones were first examined anthropologically and then with a conventional X-ray tube (Multix Top, Siemens, Germany) and receiver (DRX-1C System Detector, Carestream Health, US). Radiographs of both femora separately and the femora together with acetabula were taken in anterior-posterior (AP) and

posterior-anterior (PA) projections using suitable exposure parameters (50 kV and 22 mAs). CT images were obtained using multi-planar reconstruction (Light Speed VCT CT system, General Electric, US). The X-ray and CT images were stored in digital format on a compact disc.

## **Results**

The estimated age at death of the individual buried in grave 92D is between 40 and 50 years. The poor preservation of the skeleton meant that the sex determination based on morphological criteria (especially inion, nuchal crests, supra-mastoid crest, greater sciatic notch) was quite difficult. However, it indicated, with some uncertainty, a male individual. This result was confirmed by sex identification based on metric criteria, in particular of the upper extremities, talus and calcaneus (Bass, 1995; Cattaneo and Grandi, 2004; France, 1998; Gualdi-Russo, 2007), whereas the femoral and tibial measures were partly compatible with a female individual (France, 1998). This is especially true for the diaphyses, while the femoral head diameters were uncertain for the right side (Table 1), although these findings were probably influenced by the lesions on the lower extremities described below.

**Table 1. Measurements and indices of the femora.**

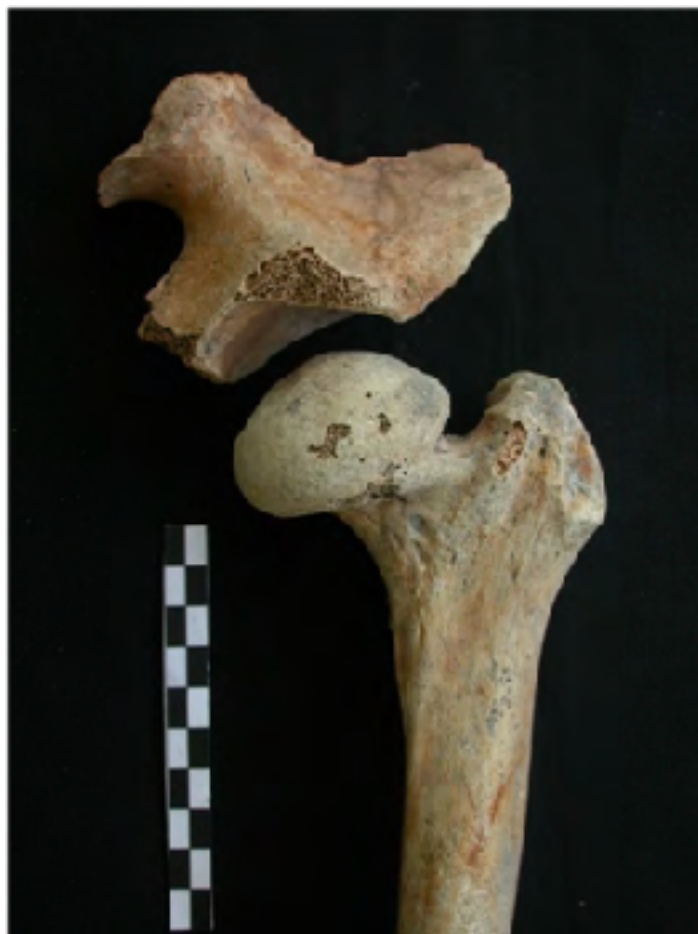<b>Osteometry</b>	<b>Left Side</b>		<b>Right Side</b>	
Metric traits				
Circumference at midshaft (mm)	85.0		83.0	
Anteroposterior diameter at midshaft (6) (mm)	27.4		27.0	
Mediolateral diameter at midshaft (7) (mm)	26.0		25.8	
Subtrochanteric mediolateral diameter (9) (mm)	33.0		33.5	
Subtrochanteric anteroposterior diameter (10) (mm)	24.7		22.5	
Length of the head & neck (mm)	62.0		69.8	
Vertical diameter of the neck (mm)	36.5		38.5	
Transverse diameter of the neck (mm)	30.4		32.7	
Vertical diameter of the head (18) (mm)	54.1		46.1	
Transverse diameter of the head (mm)	49.4		44.3	
Medio-lateral diameter of the head (mm)	29.0		30.1	
Collo-diaphyseal angle (°)	117.6		126.3	
<b>Indices</b>		<b>Categories</b>		<b>Categories</b>
Platymeric index (10/9)	74.9	platymer	67.3	platymer
Pilasteric index (6/7)	105.2	weak pilaster	104.8	weak pilaster

The estimated stature is  $1609 \pm 43$  mm according to Trotter and Gleser (1952, 1958).

This individual had osseous changes in the left hip involving the femoral head and acetabulum which appear to be the result of a pathological condition (Fig. 1).

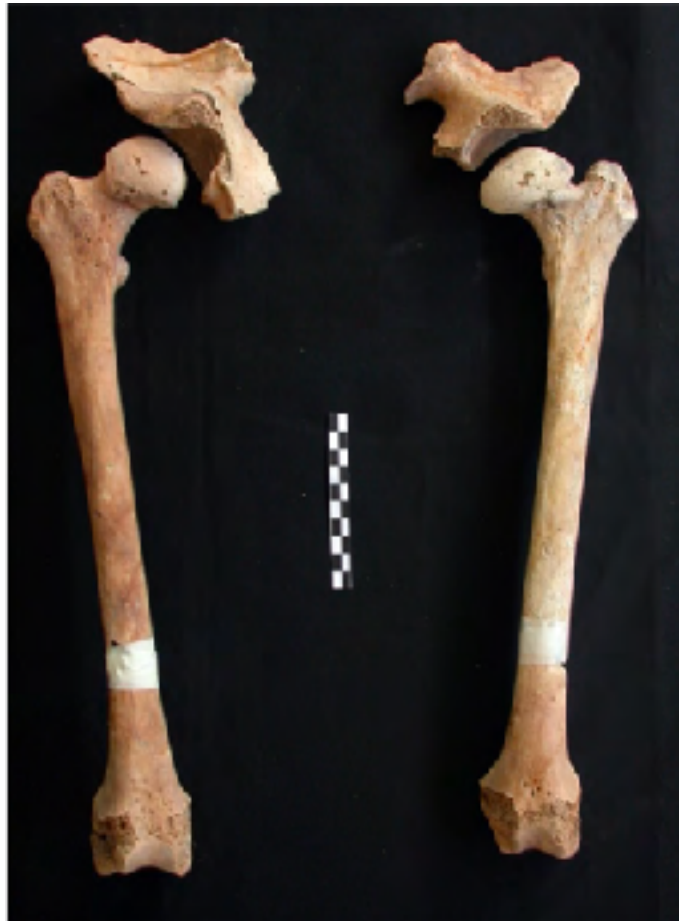Conversely, no pathological alteration is present on the right hip (Fig. 2). The left femoral head is mushroom-shaped, flattened superior-posteriorly and larger than that of the right femur (Table 1, Fig. 2). Both femora have an underdeveloped *linea aspera* and a low pilasteric index (weak pilaster); they are also platymeric (74.9 and

67.3 respectively) (Table 1) and present a Poirier's facet (Angel, 1960, 1964; Kostick, 1963). The apparently lesser length of the left femoral neck (Table 1) is mostly due to the posterior flattening of the head.



**Fig. 1** Bones of left hip of individual 92 D from Spina necropolis showing pathological alteration involving both the proximal epiphysis of the femur and acetabulum.


No downward displacement of the left femoral head is present even if the greater trochanter is higher than the center of the femoral head because of the latter's superior-posterior flattening. The left femoral head has an underdeveloped *fovea*



**Fig. 2. Comparison between bones of both the left and right hip of the analysed individual. It is possible to appreciate that the pathology is uni-lateral and involves only the left hip.**

*capitis* (the insertion of the *ligamentum capitis femoris*) and shows some porosity and exostosis on the articular surface. However, there is no evidence of severe osteoarthritis (Rogers and Waldron, 1995). The left acetabulum is markedly flattened in comparison to the right (Fig. 2) and shows an osseous border and some foci of erosion on the articular surface (Fig. 3). Unfortunately, both coxals are only partially preserved and the acetabula are not complete, preventing comparison of their diameters. No evidence of an accessory acetabulum is present in the fragmentary coxal bone. The collo-diaphyseal angle is above  $120^\circ$  on the right and below  $120^\circ$  on





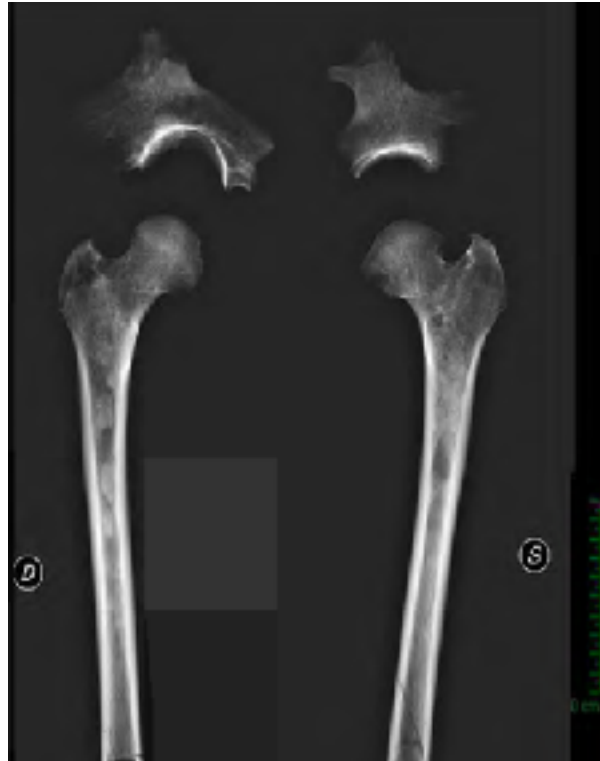**Fig. 3. Particular of left acetabulum showing articular degeneration (porosity).**

the left, leading to *coxa vara*, valgus knee and probable shortening of the left lower limb. Unfortunately it was not possible to compare the total and physiological lengths of the two femora because of condyle fragmentation.

The radiological analysis (Fig. 4) confirmed the morphometric results. The ovalization and flattening of the left femoral head are evident, as well as the shortening of the femoral neck and protrusion of the hypertrophic greater trochanter. *Coxa vara* is also present in the left hip due to a relative rectification of the angle between the neck and diaphysis of the left femur. The CT analysis with subsequent physiological length reconstructions showed a marked shortening (20 mm) of the left femur with respect to the right, as measured from the top of the femoral head to the intercondylar fossa (Fig. 5).

There is no evidence of a remodeled fracture involving the femoral head or neck. However, in comparison to the right femoral head, there are some small areas of more or less marked radiolucency on the left femoral head as a result of fragmentation and remodeling of the subchondral bone during the disease. Evidence

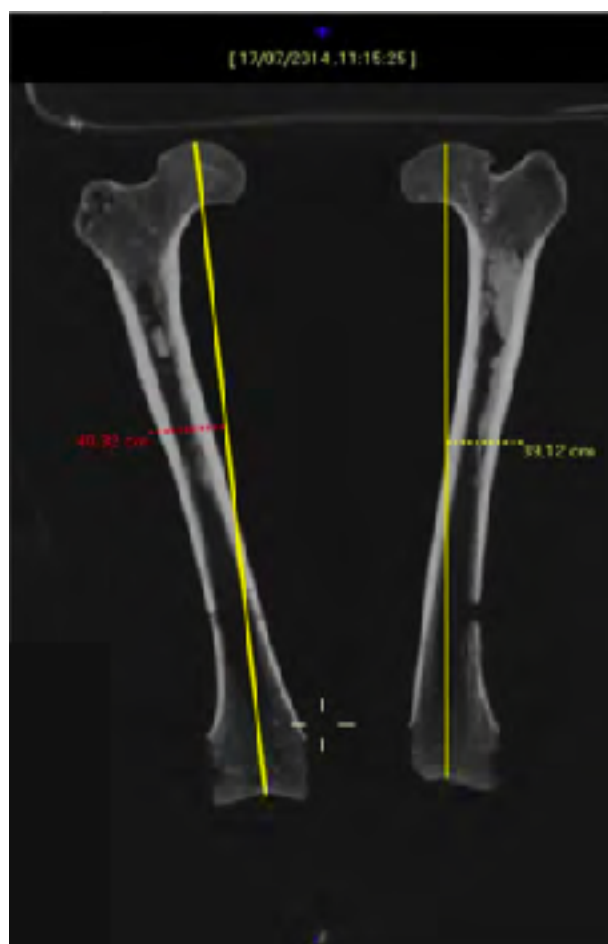of mild osteoarthritis is present on the left femoral head (porosity and exostosis on the articular surface) (Rogers and Waldron, 1995). There is no sign of severe osteoarthritis. The marked flattening and osteoarthritic modification of the left acetabulum in comparison to the right was also confirmed.



**Fig. 4. Anterior-posterior X-ray of both femora and respective fragmented acetabula in anatomic position.**

## **Discussion**

The lesions on the left hip of the individual buried in grave 92D of the Spina necropolis can be attributed to Legg-Calvé-Perthes disease. If bilateral abnormalities of the femoral head had occurred, other diseases with common bilateral involvement would have had to be considered (e.g. hypothyroidism and epiphyseal dysplasia) (Ortner, 2003). However, the characteristics of the pathological lesions in our case, affecting only one of the hips, exclude possible diseases such as hypothyroidism and other types of osteonecrosis due to sickle-cell disease, Gaucher's disease or



**Fig. 5. Physiological length reconstruction of CT images (coronal plane) of femora with respective cranio-caudal lengths.**

epiphyseal dysplasia, as they usually involve both hips or other joints (Anderson et al., 2010; Harris, 1986; Rosenfeld et al., 2007; Ruosi et al., 2003).

The absence of downward displacement of the center of the femoral head towards the axis of the neck, the almost normal neck length, the absence of a secondary acetabulum on the ilium and the absence of a fracture rim upon radiography (Fig. 4) also exclude a diagnosis of a slipped capital femoral epiphysis (Herrerín and Gallarda, 2012). Moreover, osteochondrosis can be a self-limiting disease. This was likely the case of the pathology suffered by the individual buried in grave 92D,

allowing the individual to live past 40 years of age with a quite good quality of life even without surgical treatment, obviously unavailable in the Iron Age. The only pathological consequences deducible from the radiographs of both hips are mild osteoarthritis of the left hip and deformation of the proximal epiphysis (both femoral head and neck) leading to moderate *coxa vara*, valgus knee and shortening of the left lower limb (Figs. 4-5). This probably resulted in joint stiffness of both hip and knee, pain and some difficulty in walking and moving, such as abnormal gait, limping etc. This in turn would have led to atrophy of the lower limb muscles and the observed gracility of the respective long bones. However, the appearance of the acetabulum and femoral head suggests functionality of the left hip until the individual's death. These findings are compatible with the 4<sup>th</sup> stage of LCPD as described by Lovell et al. (2006), i.e. completely healed LCPD: the femoral head is completely remodeled with the return of normal bone density.

The femoral head is medio-laterally flattened (*coxa plana*), but only mildly enlarged (*coxa magna*), as indicated from the diameters of the respective femoral heads. This alteration, probably resulting from the damage to the femoral head caused by subchondral bone resorption and fragmentation after interruption of the blood flow, is however relatively mild. This is compatible with an early onset of the disease (probably before the age of 4), which is usually associated with a better prognosis (Rosenfeld et al., 2007). The sex identification is consistent with the diagnosis of LCPD, as it especially involves European males (Chaudhry et al., 2014; Ortner, 2003).

LCPD is very rare nowadays and few studies have documented the disease in ancient populations. Ortner (2003) reported a possible case of LCPD on a right femur from Valley of Chicama in Peru characterized by a mix of male and female metric characteristics as in the present case; the archaeological age of the specimen was not well defined (Smrcka et al., 2009). Two interesting archaeological cases of LCPD were published by Smrcka et al. (2009), one involving a male older than 50 years from the Langobard cemetery at Lužice (South Moravian Region, Czech Republic)

and dating to the end of the 5<sup>th</sup>-beginning of the 6<sup>th</sup> century CE, the other affecting an adult male from Brandýsek (Kytlicová, Czech Republic) and dating to the 9<sup>th</sup>-10<sup>th</sup> century CE. Another interesting case of LCPD, involving a ~50/60-year-old male Visigoth from Duratón necropolis (Segovia, Spain, 5<sup>th</sup>-7<sup>th</sup> century CE), was published by Herrerín and Gallarda (2012). These few archaeological cases of LCPD confirm the interest in individual 92D from the Spina necropolis.

In conclusion, morphometric and radiological examinations of the left hip of the individual buried in grave 92D of the Etruscan necropolis of Spina suggest a diagnosis of LCPD. Only a few paleopathological cases of this rare disease, mostly dating to Late Antiquity-Early Middle Ages, have been published. To our knowledge the results presented here constitute the most ancient case of LCPD published thus far. This finding is very important both for the history of this disease, now dating back at least to the Iron Age, and the history of medicine, demonstrating that people affected by LCPD could survive the pathology even without surgical intervention, with only mild *sequelae* and reaching adulthood and even old age.

## Acknowledgements

The authors would like to thank the Superintendence of Archaeological Heritage of Emilia

Romagna and the National Archaeological Museum of Ferrara, Dr. Caterina Cornelio particularly, to have provided the population sample for this study. Finally, this work was supported by grant from the University of Ferrara as funding source.

## References

1. Acsádi, G., Nemeskéri, J., 1970. History of Human Life Span and Mortality. Akadémiai Kiadó, Budapest.
2. Anderson, L.A., Erickson, J.A., Severson, E., Peters, C.L., 2010. Sequelae of Perthes disease treatment with surgical hip dislocation and relative femoral neck lengthening. J. Pediatr. Orthop. 30, 758-766.

3. Angel, J.L., 1960. Human gait, hip joint and evolution. *Am. J. Phys. Anthropol.* 18, 361-376.
4. Angel, J.L., 1964. The reaction area of femoral neck. *Clin. Orthop. Rel. Res.* 32, 130-142.
5. Bass, W.M., 1995. *Human Osteology. A Laboratory and Field Manual.* Missouri Archaeological Society, Special Publication n. 2, Columbia, Missouri.
6. Berti, F., Guzzo, P., 1993. *Spina, storia di una città tra Greci ed Etruschi.* Comitato Ferrara Arte, Ferrara.
7. Berti, F., Harari, M., Ghinato, A., 2004. *Spina tra archeologia e storia. Vol II.* Corbo Editore, Ferrara.
8. Brooks, S., Suchey, J.M., 1990. Skeletal age determination based on the os pubis: a comparison of the Acsádi-Nemeskéri and Suchey-Brooks methods. *Hum. Evol.* 5, 227-238.
9. Brothwell, D.R., 1981. *Digging up Bones.* Oxford University Press, Oxford.
10. Burns, K.R. 1999. *Forensic Anthropology Training Manual.* Prentice Hall, Englewood Cliffs (NJ).
11. Cattaneo, C., Grandi, M., 2004. *Antropologia e Odontologia Forense – Guida allo studio dei resti umani.* Monduzzi Editore, Bologna.
12. Chaudhry, S., Phillips, D., Feldman, D., 2014. Legg-Calvé-Perthes disease an overview with recent literature. *Bull. Hosp. Joint Dis.* 72, 18-27.
13. Demoulin, F., 1972. Importance des certaines mesures crâniennes (en particulier de la longueur sagittale de la mastoïde) dans la détermination sexuelle des crânes. *Bull. Mém. Soc. Anthropol. (Paris)* 9, 259-264.
14. Évinger, S., Bernert, Zs., Fóthi, E., Wolff, K., Kővári, I., Marcsik, A., Donoghue, H.D., O'Grady, J., Kiss, K.K., Hajdu, T., 2011. New skeletal tuberculosis cases in past populations from Western Hungary (Transdanubia). *HOMO – J. Comp. Hum. Biol.* 62, 165-183.
15. Ferembach, D., Schwidetzky, I., Stloukal, M., 1980. Recommendation for age and sex diagnoses of skeletons. *J. Hum. Evol.* 9, 517-549.

16. France, D.L., 1998. Observational and metric analysis of sex in the skeleton. In: Reichs, K.J. (Ed.), *Forensic Osteology. Advances in the Identification of Human Remains*. Charles C Thomas, Springfield, pp. 163-186..
17. Gualdi-Russo, E., 2007. Sex determination from the talus and calcaneus measurements. *Forensic Sci. Int.* 171, 151-156.
18. Gualdi-Russo, E., Russo, R., 1995. A new technique for measurements on long bones: development of a new instrument and techniques comparison. *Anthropol. Anz.* 53, 153-182.
19. Guzzo, P.G., 2003. Ipotesi di lavoro per un'analisi dell'ideologia funeraria. In: Berti, F., Guzzo, P.G. (Eds.), *Spina, storia di una città tra Greci ed Etruschi*. Comitato Ferrara Arte, Ferrara.
20. Harris, W.H., 1986. Etiology of osteoarthritis of the hip. *Clin. Orthop. Rel. Res.* 213, 20-33.
21. Herrerín, J., Gallarda, M.D., 2012. Legg- Calvé-Perthes disease and unifocal eosinophilic granuloma in a Visigoth from the Duratón necropolis (Segovia, Spain). *Int. J. Osteoarchaeol.* 22, 86-97.
22. Kostick, E.L., 1963. Facets and imprints on the upper and lower extremities of femora from western Nigerian population. *J. Anat.* 97, 393-402.
23. Krogman, W.M., İşcan, M.Y., 1986. *The Human Skeleton in Forensic Medicine*. Charles C. Thomas, Springfield.
24. Lovell, W.W., Winter, R.B., Morrissy, R.T., Weinstein, S.L., 2006. *Lovell and Winter's Pediatric Orthopaedics*, 6<sup>th</sup> ed. Lippincott Williams and Wilkins, Philadelphia.
25. Lovejoy, C., 1985. Dental wear in the Libben population: Its Functional Pattern and Role in the Determination of Adult Skeletal Age at Death. *Am J Phys Anthropol* 68, 47-56.
26. Ortner, D.J., 2003. *Identification of Pathological Conditions in Human Skeletal Remains*, 2nd edn. Academic Press/Elsevier Science, Amsterdam.

28. Mac Laughlin, S.M., Oldane, K.N.M., 1992. Vertebral body diameter and sex prediction. *Ann. Hum. Biol.* 19, 285-292.
29. Manzon, V.S., Gualdi-Russo, E., 2016. Health patterns of the Etruscan population (6th–3rd centuries BC) in northern Italy: The case of Spina. *Int. J. Osteoarchaeol.* 26, 490-501.
30. Manzon, V.S., Onisto, N., Gualdi-Russo, E., 2014. Spondylolisthesis in an Etruscan woman from Spina (Ferrara, Italy): an iron age case report. *Coll. Antropol.* 38, 745-748.
31. Martin, R., Saller, K., 1957. *Lehrbuch der Anthropologie*. Fischer, Stuttgart.
32. Masotti, S., Onisto, N., Marzi, M., Gualdi-Russo, E., 2013. Dento-alveolar features and diet in an Etruscan population (6th–3rd c. B.C.) from northeast Italy. *Arch. Oral Biol.* 58, 416-426.
33. Meindl, R.S., Lovejoy, C.O., 1985. Ectocranial suture closure: A revised method for the determination of skeletal age at death based on the lateral-anterior sutures. *Am. J. Phys. Anthropol.* 68, 57-66.
34. Muggia, A., 2004. *Impronte nella sabbia. Tombe infantili e di adolescenti dalla necropoli di Valle Trebba a Spina. Quaderni di Archeologia dell'Emilia Romagna Edizioni All'Insegna del Giglio, Firenze.*
35. Rogers, J., Waldron, T., 1995. *A Field Guide to Joint Disease in Archaeology*. Wiley, Chichester.
36. Rosenfeld, S.B., Herring, J.A., Chao, J.C., 2007. Legg-Calvé-Perthes disease: A review of cases with onset before six years of age. *J. Bone Joint Surg. Am.* 89, 2712-2722.
37. Rühli, F.J., Müntener, M., Henneberg, M., 2006. Human osseous intervertebral foramen width. *Am. J. Phys. Anthropol.* 129, 177-198.
38. Ruosi, C., Loffredo, A., Santoro, G., Misasi, M., 2003. Anatomia e malattie degenerative dell'anca. *Giornale Italiano di Ortopedia e Traumatologia* 29, 156-160.



39. Salter, R.B., 1999. Textbook of Disorders and Injuries of the Musculoskeletal System, 3rd ed.
40. Williams & Wilkins, Baltimore, Maryland.
41. Smrcka, V., Marik, I., Svenssonova, M., Likovsky, J., 2009. Legg-Calvé-Perthes disease in Czech archaeological material. Clin. Orthop. Relat. Res. 467, 293-297.
42. Trotter, M., Gleser, G.C., 1952. Estimation of stature from long bones of American Whites and Negroes. Am. J. Phys. Anthropol. 10, 463-514.
43. Trotter, M., Gleser, G.C., 1958. A re-evaluation of estimation of stature based on measurements of stature taken during life and of long bones after death. Am. J. Phys. Anthropol. 16, 79-123.
44. Wilder, H.H., 1920. A Laboratory Manual of Anthropometry. P. Blakiston's Son & Company, Philadelphia.
45. Zhang, C., Yang, F., Cornelia, R., Tang, W., Swisher, S., Kim, H., 2011. Hypoxia-inducible factor1 is positive regulator of Sox9 activity in femoral head osteonecrosis. Bone 48, 507-513.