

Original Article

Musculoskeletal ultrasonography for psoriatic arthritis and psoriasis patients: a systematic literature review

Alen Zabotti¹, Francesca Bandinelli², Alberto Batticciotto³, Carlo Alberto Scirè^{4,5}, Annamaria Iagnocco⁶ and Garifallia Sakellariou⁷; on behalf of the Musculoskeletal Ultrasound Study Group of the Italian Society of Rheumatology

Abstract

Objective. To systematically review the role of musculoskeletal US in patients suffering from PsA or psoriasis (Pso) in terms of prevalence, diagnosis, prognosis, monitoring and treatment.

Methods. A systematic literature review was conducted through medical databases (MEDLINE via PubMed, Embase) and the grey literature up to September 2015 to inform a new study of the Musculoskeletal Ultrasound Study Group of the Italian Society for Rheumatology. All articles reporting data on musculoskeletal US in PsA or Pso were included and extracted according to the underlying clinical question.

Results. A total of 86 publications were included. The prevalence of US abnormalities showed a wide range for each examined feature (e.g. 37–95% for entheses thickness of the lower limbs). The performance of US for diagnosis of disease or elementary lesions was variable across studies, but no study evaluated the overall performance of US in addition to clinical findings for diagnosing PsA. Considering US in defining PsA and Pso prognosis, several works focused on US of entheses of lower limbs in Pso, while for the monitoring of PsA activity five different scoring systems were identified. Last, the results of the role of US in guiding intra-articular interventions were controversial for the clinical outcomes, but in favour of US for accuracy.

Conclusion. despite the recognized importance of US in the management of PsA and Pso, this review clearly demonstrated the need of pivotal research in order to optimize the use of US in the diagnosis and monitoring of psoriatic disease.

Key words: ultrasonography, psoriatic arthritis, psoriasis, entheses, synovitis, tenosynovitis, systematic literature review, US-guided intra-articular injection, research agenda, ultrasound score

Rheumatology key messages

- Musculoskeletal ultrasound is superior to clinical examination in detection of joint inflammation.
- Ultrasonography should be integrated into clinical practice.
- A large amount of research is necessary into the use of ultrasonography in the management of psoriatic disease.

¹Rheumatology Clinic, Department of Medical and Biological Sciences, University Hospital Santa Maria della Misericordia, Udine, ²Rheumatology Unit, Azienda Sanitaria di Firenze, S. Giovanni di Dio Hospital, Florence, ³Rheumatology Unit, L. Sacco University Hospital, ⁴Epidemiology Unit of the Italian Society for Rheumatology (SIR), Milan, ⁵Department of Medical Sciences, Section of Rheumatology, University of Ferrara, Ferrara, ⁶Dipartimento di Scienze Cliniche e Biologiche, Università degli Studi di Torino, Turin and ⁷Division of

Rheumatology, IRCCS Policlinico San Matteo Foundation, University of Pavia, Pavia, Italy

Submitted 29 November 2016; revised version accepted 4 April 2017

Correspondence to: Annamaria Iagnocco, Dipartimento di Scienze Cliniche e Biologiche, Università degli Studi di Torino, Azienda Ospedaliero-Universitaria San Luigi Gonzaga, Regione Gonzole 10, 10043 Orbassano, Torino, Italy.
E-mail: annamaria.iagnocco1@gmail.com

Introduction

PsA is a systemic inflammatory disease with articular and extra-articular features. In recent years, imaging is playing an increasingly important role in the differential diagnosis of and in monitoring treatment response in PsA. Recently, the EULAR recommendations for the use of imaging in the diagnosis and management of SpA advise the use of MRI and US for diagnosis, activity monitoring and structural change evaluation in peripheral SpA [1]. US demonstrated good accuracy, reliability and sensitivity to change in the assessment of various structures that may be involved in PsA, i.e. tendons, entheses, synovium and bone [1–3]. In addition, the information given by US assessment can be integrated with that obtained by clinical examination, thus improving differential diagnosis (e.g. early seronegative polyarthritis), stratification of patients and therapeutic strategies in a treat-to-target (T2T) context [4, 5]. Currently, the utility of US in clinical practice is not yet supported by adequate evidence [6]; therefore, reflecting the need to determine the role of US in diagnosis and prognostic stratification and to support prioritization of US studies in PsA, the Musculoskeletal Ultrasound Study Group of the Italian Society of Rheumatology decided to perform a systematic literature review (SLR) on the use of US in the management of PsA.

Methods

The Preferred Reporting Items for Systematic reviews and Meta-analyses were followed to design and report this review [7]. The most relevant areas of application of US in PsA and psoriasis (Pso) were identified, and pre-specified inclusion criteria for each item were developed (supplementary Table S1, available at *Rheumatology* Online).

Data sources and search

PubMed and Embase were searched, without time limits, up to 27 September 2015. The search strategy was developed based on search terms aiming at identifying studies including patients with PsA or Pso in which musculoskeletal US was performed. The search strategy is presented in supplementary Table S2, available at *Rheumatology* Online. Abstracts of the ACR and EULAR congresses (2014 and 2015) were hand searched. Studies had to be published in English, and neither publication restrictions nor selection based on quality were applied.

Study selection

Studies of patients with suspected or confirmed PsA were included, including patients with mixed populations of arthritis (only some of the patients were diagnosed with PsA). Studies on patients with skin psoriasis without arthritis were also eligible for inclusion. US was considered as the index test/intervention; details on the comparators, outcomes and eligible study designs are shown in Table S1. The reviewers (F.B., A.B., A.Z.) worked in pairs for each area of interest, independently screening titles and abstracts.

Data extraction and quality assessment

Study characteristics and data were extracted using separate standardized forms for each area of interest. For diagnostic accuracy items, when possible, data were extracted as 2×2 tables, and sensitivity, specificity, positive and negative likelihood ratios with 95% CIs were calculated. Pre-specified meta-analyses were not planned, due to the expected heterogeneity across studies. The hypothesis of heterogeneity was tested in the subgroup of studies assessing the performance of US in detecting elementary lesions. The risk of bias and methodological quality of the included studies were assessed with different tools, depending on study design. For diagnostic studies, the QUADAS-2 tool was used [8]; for randomized controlled trials (RCTs) the risk of bias tool proposed by the Cochrane collaboration was used [9], while for observational studies the Newcastle–Ottawa scale (NOS) was used [10].

Results

Selected studies

Of the 365 studies produced by the PubMed and Embase searches, 71 studies met the criteria for inclusion. Furthermore 15 additional studies were included: 2 from the hand search and 13 from the 2014–15 abstracts of ACR and EULAR (Fig. 1). Table 2 highlights high-quality studies on prevalence, diagnosis and prognosis.

Prevalence of US abnormalities in PsA and Pso

The search retrieved 56 studies examining the prevalence of US abnormalities in PsA (50/56 studies) and isolated Pso (6/50 studies) [11–66]. The results are summarized in Table 1 and completely reported in supplementary Table S3, available at *Rheumatology* Online. Regarding the examined US abnormalities, synovitis, erosions and enthesopathy were often studied; less frequently, soft tissue inflammation (described as oedema) and/or power Doppler (PwD) peri-tendinous, were studied. The prevalence of the examined lesions had a wide range in the studies: 10–100% for synovitis [22, 34, 48, 52, 55]; 37–94.5% for entheses thickness of the lower limbs [14, 15, 17, 24, 27, 30, 35, 36]; and 10.8–52% for erosions [16, 34, 53, 55]. The sites examined were very variable, except for studies of US entheses, in which the lower limbs were the most frequently studied. For entheses evaluation, the Glasgow Ultrasound Enthesitis Scoring System (GUESS) was the most commonly employed score [15, 17, 27, 41, 50, 59], followed by the MAdrid Sonography Enthesitis Index (MASEI) score [12, 26]. Furthermore, two studies evaluated synovial contrast enhancement, with a prevalence in PsA of ~30% [33, 55]. The risk of bias for all selected studies, assessed using the NOS, is reported in supplementary Table S3, available at *Rheumatology* Online.

Making a diagnosis of PsA

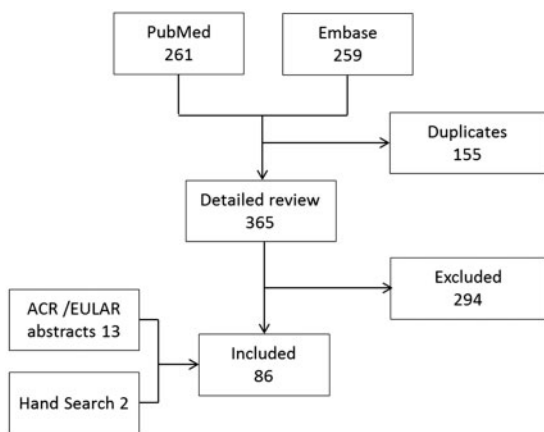
Performance of US in the diagnosis of PsA and Pso

The search retrieved 23 studies, including a qualitative systematic review [67], examining the performance of

TABLE 1 Prevalence of US abnormalities across primary studies

PsA patients	Prevalence on site examined (%)	Prevalence on patient (%)
Grey-scale synovitis	14.0–57.0	10.0–100.0
Power Doppler synovitis	2.0–8.7	28.6–73.0
Joint erosions	6.1–57.7	10.8–52.0
Increased thickness of lower limbs entheses:		
PwD at enthesis	0.0–7.4	15.6–40.2
Enteseal erosions	5.0–14.9	0.0–10.8
Soft-tissue inflammation	38.9–65.8	14.3–32.0

Values are listed as range (%). PwD: power Doppler.

FIG. 1 Flow-chart showing the selection process

US in diagnosing PsA [12, 17, 19–21, 26–31, 34, 37, 40, 42, 45–47, 56, 58, 59, 68]. The results of the studies are summarized in Table S4, available at *Rheumatology* Online, Fig. 2, supplementary Figs S1 and S2, available at *Rheumatology* Online. The diagnostic performance of US was variable across studies; in particular, no study evaluated the overall performance of US in addition to clinical findings re diagnosing PsA, while most studies were focusing on single lesions. However, no study demonstrated an adequate performance for US variables, considered separately. The performance of US in detecting PsA was broadly variable among studies, with sensitivities ranging from 0.22 to 1.00 for enthesopathy, from 0.16 to 0.76 for synovial hypertrophy and from 0.14 to 0.58 for joint bone erosions. Also, sensitivities were extremely variable, ranging from 0.20 to 1.0 for enthesopathy, from 0 to 1.0 for synovial hypertrophy and from 0.40 to 1.0 for bone erosions. Most of the studies (22 out of 23) followed a cross-sectional case-control design, and the evaluation of the diagnostic performance of US was in many cases not the primary objective of the study. As expected, the studies were heterogeneous in terms of examined sites and reference standard, although clinical diagnosis or classification criteria were the only standards

adopted. The risk of bias, assessed by the modified version of the QUADAS, was in general considered high for the items concerning patient recruitment, unclear for the items dealing with the index test and mostly low for the items covering the reference standard and the timing (supplementary Figure S3, available at *Rheumatology* Online).

Performance of US in the diagnosis of PsA and Pso elementary lesions

The search retrieved 30 studies examining the performance of US in diagnosing PsA elementary lesions [11, 15, 16, 20, 23–25, 30, 32–34, 37–39, 44, 45, 47, 48, 51–53, 55, 57, 58, 63, 64, 69–72]. The results of the studies are summarized in supplementary Table S5, available at *Rheumatology* Online. The PsA elementary lesions evaluated were heterogeneous for type of lesions (e.g. synovial or extra-synovial features), anatomic structures and reference standard. The reference standard was clinical examination in 14 studies, MRI in 5, conventional radiography and arthroscopy in 3, and CT and histological evaluation in 1. Considering MRI as the reference standard, the sensitivity and specificity underwent wide variations depending on the examined anatomic structures and types of lesions; e.g. considering synovitis, sensitivity ranged from 0.49 to 0.94, while specificity ranged from 0.20 to 0.91 (supplementary Fig. S4, available at *Rheumatology* Online). In the unique study using histopathology as the reference, the amount of PwD did not significantly associate with a global histopathological inflammatory score [44], while for the single study comparing US with CT, a large proportion of bone lesions detected by US could be verified by CT [32]. The risk of bias, assessed by the modified version of the QUADAS, was in general considered high for the items concerning patients' recruitment, unclear for the items dealing with the reference standard and mostly low for the index test and flow and timing (supplementary Fig. S5, available at *Rheumatology* Online). This subgroup of studies was used to test for the presence of heterogeneity across studies (supplementary Fig. S6, available at *Rheumatology* Online), showing a significant degree of heterogeneity (for joint abnormalities: $\chi^2 = 785.46$, $P < 0.0001$ for the presence of heterogeneity; for enteseal abnormalities: $\chi^2 = 1027.29$, $P < 0.0001$ for the presence of heterogeneity).

TABLE 2 Summary table on prevalence, diagnosis and prognosis reporting high-quality studies^a

Equipment	Area of interest	References	n	Population	Control	Examined structures
Aydin <i>et al.</i> [13]	42 PsA	Cutaneous psoriasis with nail disease	20 HCs	Nail	GE Logiq E9, 10–18 Mhz	Disease prevalence; diagnosis of PsA and elementary lesions
Aydin <i>et al.</i> [14]	58 PsA	Cutaneous psoriasis including PsA	42 Pso; 23 HCs	Lower limb entheses	GE Logiq E9 and Logiq5 machine	Disease prevalence; diagnosis of PsA and elementary lesions; prognosis
Bandinelli <i>et al.</i> [16]	112 PsA	PsA with symptoms onset <1 year	-	MCP-PIP-DIP joints; flexor and extensor digitorum tendons; radio and intercarpal joints	Esaote MyLab70 XVG, 6–18 MHz	Disease prevalence; diagnosis of elementary lesions
Eder <i>et al.</i> [26]	50 PsA	PsA	66 Pso; 60 HCs	Enthesis included in the MASEI score	Esaote MyLab70 XVG, 6–18 MHz	Disease prevalence; diagnosis of PsA and elementary lesions
Fourniè <i>et al.</i> [34]	20 PsA	PsA and RA	21 RA	Hand joints (MCP, PIP and DIP); extensor and flexor tendon; soft tissue	Siemens Sonoline Elegra, 13.5 MHz	Disease prevalence; diagnosis of PsA and elementary lesions
Freeston <i>et al.</i> [37]	42 PsA	Early PsA (<24 months)	10 HCs	Lateral epicondyles of the elbow, inferior patellar tendon insertion, Achilles tendon, plantar fascia	Philips HDI 5000, 5–12 and 7–15 MHz	Disease prevalence; diagnosis of PsA and elementary lesions
Freeston <i>et al.</i> [38]	49 PsA	Early PsA (<24 months)	8 HCs	Bilateral posterior glenohumeral joints, olecranon fossa, wrists, MCP and PIP joints, knees, tibiotalar and MTP joints	Philips HDI 5000 machine, 5–12 MHz and 7–15 MHz	Disease prevalence; diagnosis of elementary lesions
Gisondi <i>et al.</i> [73]	30 Pso	Pso without any clinical evidence of arthritis or enthesitis	30 HCs	Target entheses (GUESS score)	ATL HDI 3000, 10–15 MHz probe	Prognosis
Gutierrez <i>et al.</i> [40]	20 PsA	PsA and RA	18 RA	MCP joints	Esaote MyLab70 XVG 6–18 Mhz	Disease prevalence; diagnosis of PsA and elementary lesions
Gutierrez <i>et al.</i> [41]	45 Pso	Pso without any clinical evidence of arthritis or enthesitis	45 HCs	Target entheses of GUESS score	Esaote MyLab70 XVG 6–18 MHz	Disease prevalence; prognosis
Husic <i>et al.</i> [74]	70 PsA	PsA	-	68 joints and 14 entheses	Esaote MyLabTwice, 6–18 MHz	Prognosis
Marchesoni <i>et al.</i> [46]	30 PsA	PsA and FM	30 FM	14 target entheses	GE Logiq5, 8–15 MHz	Disease prevalence; diagnosis of PsA
Naredo <i>et al.</i> [49]	162 Pso	Plaque psoriasis	60 controls with other skin disease	Wrist, MCP-PIP and -DIP joints of the hands, knee, tibiotalar joint; extensor tendon of the wrist; finger flexor tendon; target entheses	GE Logiq 9, 8–14 MHz	Disease prevalence; prognosis
Tinazzi <i>et al.</i> [75]	30 Pso	Pso	-	Target entheses (GUESS score)	ATL HDI 3000, 10–15 MHz	Prognosis


(continued)

TABLE 2 Continued

Equipment	Area of interest	References	n	Population	Control	Examined structures
Zayat <i>et al.</i> [60]	60 PsA	PsA, RA, gout and OA	70 RA, 60 gout, 60 OA, 60 HCs	Distal articular radius and ulna, II-III and V MCP joints, II-III PIP joints and I and V MTP joints, second, third	probe;GE Logiq5, 10-15 MHz GE LogiqE9, 6-15 MHz	Disease prevalence; diagnosis of elementary lesions

^aHigh quality studies are defined as those containing relevant results for the reviewers and including at least 20 PsA patients or 30 Pso patients. HC: healthy control; Pso: psoriasis.

Fig. 2 Performance of US variables for diagnosing PsA: sensitivities and specificities of primary studies



(A) synovial abnormalities/joint effusion; (B) enteseal abnormalities; (C) tendon abnormalities; (D) bone erosions. No US abnormality, considered alone, had an optimal diagnostic performance for diagnosing PsA.

Prognosis and follow-up

Role of US in defining PsA and Pso prognosis

The search retrieved 15 studies examining the role of US in defining PsA and Pso prognosis [11, 14, 23, 41, 49, 56, 59, 73–80], with only two having a prospective design [75, 80]. The results of the studies are summarized in supplementary Table S6, available at *Rheumatology* Online. Several works, selected for this item, focused on target enthesis US in Pso patients revealing a high rate of subclinical inflammatory signs. Subclinical enthesitis, confirmed by a significantly higher Glasgow Ultrasound Enthesitis Scoring System (GUESS) score, was found more frequently in Pso compared with in healthy controls [14, 41, 73], while only one study focused on the prevalence of subclinical synovitis in Pso [49]. There was only one prospective study, published by Tinazzi *et al.* in which GUESS scores of patients with Pso who developed PsA compared with those who did not develop PsA did not statistically differ. Furthermore, in the logistic regression analysis, baseline thickness of the quadriceps tendon was found to be an independent predictor of the development of PsA [75]. Moreover, the presence of PwD signal in enthesis, evaluated as enthesial-organ in Aydin *et al.* [14] and within 2 mm of bone insertion in Gutierrez *et al.* [41], was found to be highly specific for psoriatic disease. The risk of bias for all selected studies, assessed using the NOS, is reported in supplementary Table S6, available at *Rheumatology* Online.

Role of US in the follow-up of PsA and Pso

The search retrieved 15 studies exploring the role of US in PsA follow-up [18, 63, 69, 12, 81–91]. The results are summarized in Table 3. In several studies, US assessment was used to analyse the response to a standardized therapeutic approach with inhomogeneous US endpoints. The comparison between articles is made difficult by the variability in definitions of elementary lesions and scoring systems, machine settings and image acquisition. Among the selected articles, five different scoring systems have been tested. The US Group of the Spanish Society of Rheumatology demonstrated that the power Doppler US (PDUS) examination of 14 peripheral entheses was able to monitor the 6 months therapeutic response in SpA patients [86]. The German US7 scores significantly reflected the therapeutic response of PsA patients, evaluating synovitis, tenosynovitis and erosions of small joints, whereas the sonography of large joints in Rheumatology (SOLAR score), used to evaluate synovitis and tenosynovitis of the large joints, was able to monitor the treatment response in a cohort of PsA patients [81, 88]. The Five Targets PwD for Psoriatic Disease score was the first score including all domains characterizing PsA (joint, tendon with synovial sheath, enthesis, skin and nail); those, one for each target area, showing the highest expression of PwD were selected for monitoring an anti-TNF therapy in PsA patients [90]. The Five Targets PwD for psoriatic disease score showed significant improvement during therapy, but it did not correlate with HAQ-modified for SpA. Finally, Ficjan *et al.* developed two US scores

(PsA-Son22 and PsA-Son13) in a prospective study on 83 consecutive PsA patients; these scores explored joints, peri-articular structures and entheses. Both composite scores had sufficient sensitivity to show change, but the bilateral score (PsA-Son22) was more sensitive than the unilateral score for detecting PsA lesions [89]. The risk of bias, assessed using the NOS, the Preferred Reporting Items for Systematic reviews and Meta-analyses Checklist and the Cochrane diagnostic test Accuracy, was reported in Table 3.

US to guide intra-articular interventions

The search retrieved four studies, including two randomized controlled trials, examining the role of US in guiding intra-articular interventions [92–95]. Among the two RCTs, comparing blinded and US-guided injections, the results were controversial with respect to clinical outcome, but accuracy was better for US-guided procedures [94, 95]. In Sibbit *et al.* [95], US-directed intra-articular injections were superior to palpation-guided methods in all therapeutic measures: absolute VAS pain scores for injection pain were 81% less, responder rates were increased by 38%, and non-responder rates were reduced by 34%. Conversely, in the study published by Cunnington *et al.* [94], there was no statistically significant difference between US-guided and blind injections for any of the major outcome variables (e.g. VAS pain, function and stiffness) measured at 2 or 6 weeks. Only one study focused on tenosynovitis, and no study focused on enthesitis or bursitis [93]. The risk of bias, assessed by the Cochrane Collaboration's tool for intervention studies, is reported in supplementary Fig. S7, available at *Rheumatology* Online.

Discussion

The usefulness of US in diagnosis, prognosis and follow-up of inflammatory arthritis in clinical practice is still a matter of debate, despite the evidence for higher sensitivity over clinical examination. Recently, an EULAR task force developed evidence-based recommendations on the use of imaging in the clinical management of RA and SpA [1, 96], acknowledging the need of further extensive research in order to optimize the use of imaging in routine clinical practice. On this basis, and in order to identify and prioritize its research agenda in the field of PsA, the MSUS Study Group of the Italian Society of Rheumatology, decided to plan a SLR with the aim of highlighting the current state of knowledge. Currently, in early inflammatory arthritis, rheumatologists need supporting tools in order to strengthen diagnoses [97]. Among imaging modalities, US is the most attractive one, as it is less time-consuming, safer, and readily and easily used. For this reason, an increasing number of studies about US for diagnosing PsA has recently been published. However, its use in clinical practice is still a matter of debate. In the SLR, the diagnostic performance of US was widely variable, and no study evaluated the overall performance of US in addition to clinical findings in diagnosing PsA. Moreover, most of the selected diagnostic studies

TABLE 3 Studies evaluating US in monitoring PsA

References	n	Study design	Inclusion criteria	Examined structures	Equipment	Results	Risk of bias ^a
Acquacalda et al. 2015 [12]	22 PsO 12 PsA	Prospective cohort	CASPAR before introduction of the first systemic treatment or biologic	Five entheses Hypoechoogenicity, thickness, erosion, calcification, PwD, morphological/structural lesion	Esaote MyLab70 XVG	US morphological abnormalities (baseline vs 6 months) PsO 30% vs 17.7%, $P = 0.021$ PsA (PwD) 33% vs 24%, $P = 0.164$	Sel ** Comp ** Exp **
Backhaus et al. [81]	120 patients (PsA 9%)	Prospective cohort	PSA starting new therapy	Wrist, second to third MCP and PIP, second-fifth MTP GS and PwD	Different US machines	3 months: Synovitis GSUS/DAS28, $r = 0.44$, $P < 0.05$ PDUS/DAS28, $r = 0.44$, $P < 0.05$ Tenosynovitis GSUS/DAS28, $r = 0.11$, $P > 0.05$ PDUS/DAS28, $r = 0.11$, $P > 0.05$ Erosions/DAS28, $r = 0.11$, $P > 0.05$ 6 months: synovitis GSUS/DAS28, $r = 0.38$, $P < 0.05$ PDUS/DAS28, $r = 0.31$, $P < 0.05$ tenosynovitis GSUS/DAS28, $r = 0.26$, $P < 0.05$ PDUS/DAS28, $r = 0.24$, $P < 0.05$ Erosions/DAS28 $r = 0.16$, $P > 0.05$	Sel *** Comp Exp *
Bonifati et al. [18]	25 PsA	Retrospective cohort	CASPAR criteria, ETA o ADA (>12 months)	Target joints US contrast-enhanced	-	Positive CEUS (baseline vs 12 months) 22/25 vs 3/25, $P < 0.0001$	Sel *** Comp Exp **
Cozzi et al. [82]	36 PsA	RCT	CASPAR, TNFi >6 months	All joints of both hands US contrast enhanced	Esaote My Lab 70	GEUS in PsA receiving mud-bath (baseline-45 days): seconds, mean (s.d.) Time of appearance 22.21 (8.79) vs 25.71 (12.81), $P < 0.05$ Washout rate 9.32 (0.49) vs 9.12 (0.78), $P > 0.05$ Peak value 0.14 (0.06) vs 0.13 (0.04), $P > 0.05$	High risk

(continued)

TABLE 3 Continued

References	n	Study design	Inclusion criteria	Examined structures	Equipment	Results	Risk of bias ^a
Ficjan <i>et al.</i> [89]	83 PsA	Prospective cohort	CASPAR, peripheral articular manifestations	PsASon 22, bilateral score included 22 joints and 4 entheses. PsASon13, unilateral score included 13 joints and 2 entheses	Esaote My Lab Twice	Contrast flow 0.07 (0.03) vs 0.06(0.03), <i>P</i> < 0.05 PsASon 22 and 13 (6 months) Sel *** Global US inflammation Comp *** Subscore: Exp *** SRM: -0.53 to -0.04 (entire cohort) -1.04 to -0.09 (pts from active disease to MDA) ICC: 0.84 (PsASon22), 0.54 (PsASon 0.96) Significant correlation between clinical and US indexes at all time-points (baseline, 2, 6, 12 months)	Sel *** Comp *** Exp ***
Fiocco <i>et al.</i> [69]	23 patients (11 PsA)	Prospective cohort	Moll and Wright, knee joint pain, patients treated with NSAIDs and second-line drugs >6 months	Knee Joint Tickness effusion/Synovial	7.5MHz electronic linear transducer/ 10 MHz mechanical sectorial transducer Elegra, Siemens		Sel ** Comp * Exp **
Fiocco <i>et al.</i> [83]	27 patients (8 PsA)	Prospective cohort	Moll and Wright Criteria, eligible for TNFI	Involved knee Synovitis PwD		F/SI-PD mean (s.d.) Baseline 1.31 (0.30); 3 months 0.63 (0.21) <i>P</i> < 0.001; 12 months 0.44 (0.20), <i>P</i> < 0.05 P/CI-PD mean (s.d.) Baseline 1.59 (0.21), 3 months 1.62 (0.018), <i>P</i> > 0.05; 12 months 0.89 (0.18) <0.05	Sel *** Comp Exp **
Fraser <i>et al.</i> [84]	72 PsA	RCT	18-70 years, PsA criteria 1994 >24 weeks, active PsA and Pso, no response to MTX	Second-fifth MCP and PIP of the dominant hand	ATL HDI 3000	US synovitis reduction after 12 months -2.5 (95% CI: -4.07, -1.01)	Unclear
Keen <i>et al.</i> [85]	-	Systematic review	Published studies in English, humans, comparing imaging of structural tissue	Involved knee Synovial thickness, effusion size, PwD	-	US internal responsiveness was found with regard to synovial thickness, effusion size, and popliteal cyst size. External responsiveness was demonstrated against several referenced health status measures No quantitative synthesis, references were screened	PRISMA Checklist: 20/28
Gutierrez <i>et al.</i> [90]	16 PsA	Prospective cohort	CASPAR, starting therapy with ADA, ETA, IFX	MCPs, MTPs, wrists, finger flexor tendons, tibialis posterior tendons, peroneous tendons, entheses (Achilles)	Esaote My Lab 70 XVG	Median (IQR) 5 target PD: Baseline 9 (4-12), 8 weeks 3 (1-5), <i>P</i> = 0.0001	Sel *** Comp Exp **

(continued)

TABLE 3 Continued

References	n	Study design	Inclusion criteria	Examined structures	Equipment	Results	Risk of bias ^a
Naredo et al. [86]	327 SpA	Prospective cohort	ESSG or Amor criteria, starting TNFi	tendon, distal and proximal insertion of patellar tendon), psoriatic plaques, nails 14 peripheral entheses Morphologic abnormalities, calcific deposits, cortical abnormalities, adjacent bursitis, PwD	Logiq 5 PRO; (General Electric)	Inter-reader reliability baseline k: joint 0.74, tendon 0.79 entheses 0.97, nail 0.65, skin 0.88 Intra-reader reliability baseline k: joint 0.98, tendon 0.98, entheses 0.97, nail = 0.82, skin 0.94 Baseline vs 6 months [mean Sel ^{***} (s.d.)] Morphologic abnormality score 2.19 (2.66) vs 1.34 (2.02), P < 0.0005 Calcific deposit score 1.11 (1.63) vs 1.23 (1.79), P = 0.142 Cortical abnormality score 3.92 (3.73) vs 4.17 (3.86), P = 0.036 Adjacent bursitis score 0.94 (1.21) vs 0.76 (1.19), P = 0.036 Intraentheses PwD 1.36 (2.11) vs 0.68 (1.64), P < 0.0005 Perientheses PwD 1.75 (2.92) vs 0.98 (2.23), P < 0.0005	
Teoli et al. [87]	40 PsA	Retrospective cohort	CASPAR; therapy with ADA	Most clinically involved joints. Synovial effusion, synovial proliferation, PwD	Logiq 5 Pro (General Electric)	Baseline vs 24 months score [mean, IQR] Synovial effusion 2.3 (1-3) vs Exp ^{**} 0.1 (0-1) Synovial proliferation 1.125 (0-2) vs 0.025 (0-1) PwD 2.5 (1-3) vs 1 (0-2) Bone erosions 0.2 (0-2) vs 0.25 (0-2)	
Schafer et al. [88]	126 SpA	Prospective cohort	CASPAR	Shoulder, elbow, hip, kneeSolar score (GS/PwD)	-	Baseline vs 6 months score [mean (s.d.)] Shoulder GS 2.8 (1.9) vs 1.1 Exp ^{***} (1.2), P < 0.05 PwD 1.7 (1.6) vs 0.4 (0.8), P < 0.05 Elbow GS 4.3 (2.6) vs 0.9 (1.5), P < 0.05 PwD 2.3 (2.0) vs 0.6 (1.1), P < 0.05	

(continued)

TABLE 3 Continued

References	n	Study design	Inclusion criteria	Examined structures	Equipment	Results	Risk of bias ^a
Coates <i>et al.</i> [63]	89 PsA	Retrospective cohort	Early PsA	Hands US Erosions	Unclear	Hip GS 2.0 (0.8) vs 1.0 (1.1), P < 0.05 PwD 0.7 (0.9) vs 0.3 (0.5), P > 0.05 Knee GS 5.3 (2.9) vs 2.8 (2.8), P < 0.001 PwD 2.9 (3.1) vs 1.4 (2.4), P < 0.05 Erosions (%) baseline vs 48 weeks 3.5% vs 5.6%	

^aThe results of the Newcastle-Ottawa quality Assessment Scale are expressed with ***, **, or **** for each item. According with this validated tools, every statement satisfied awards one * up till a maximum of ****. ADA: adalimumab; CASPAR: Classification criteria for psoriatic arthritis; CEUS: contrast-enhanced ultrasonography; Comp: comparator; ETA: etanercept; Exp: exposure; F/SI-PD: fluid/synovium interface; P/CI-PD pannus/capsule interface; GS: grey-scale; GSUS: grey-scale ultrasonography; HC: healthy control; ICC: interclass correlation; IFX: infliximab; IQR: interquartile range; PASI: psoriasis area severity index; PDUS: power doppler ultrasonography; Pso: psoriasis; PwD: power Doppler; Sel: selection; SRM: standardized response mean; TNFi: TNF inhibitors.

followed a cross-sectional case-control design, introducing a bias in patient selection (leading to an overestimation of the diagnostic performance of the index test). The ability of US to detect elementary lesions, which may support the diagnosis of PsA, is widely described in the literature. Considering the potential pathogenetic role of enthesitis in PsA, US of entheses was (not surprisingly) most frequently used for diagnosis [11, 12, 15, 17, 23-27, 30, 31, 38, 39, 42, 45, 46, 52, 59]. Furthermore, US was used to image synovitis, tenosynovitis, bursitis and erosions (and less frequently soft tissue and hand nails). Clinical examination was often the reference standard for both the diagnosis of PsA and of psoriatic elementary lesions. Only one study examined the performance of PwD in identifying synovitis, using histopathology as the gold standard, showing that a negative PwD in the synovium did not exclude the possibility of synovitis [44]. In axial SpA, imaging is a key component of classification criteria, mostly due to the absence of specific clinical symptoms [1], while in the classification of peripheral inflammatory arthritis, its use is not mandatory. However, in early disease, imaging might play an important role in supporting diagnosis and directing the treatment. Regarding the differential diagnosis, studies seem to support the idea that PsA could be differentiated from RA by major extra-synovial involvement. Soft tissue inflammation, described as oedema and/or PwD peri-tendinous, could be a very distinctive sign of PsA, being absent in RA controls [34, 40, 45]. Fourniè *et al.* [34] highlighted major synovial involvement in RA compared with PsA (i.e. 100% vs 76%), and furthermore, the prevalence of erosions was lower in PsA than in RA [58, 60, 63], even though this result was recently questioned by another study [45]. Moreover, the prevalence of features differed greatly between selected studies, mainly due to the heterogeneity of inclusion criteria, elementary lesion definitions and equipment. In addition, possible sources of bias mainly related to patient selection might have been present. With sooner the better being the ideal treatment strategy, the application of US in predicting the development of arthritis in Pso patients or in identifying PsA patients with poorer outcome, is of interest. Considering the importance of enthesitis as the key lesion in PsA, some studies focused on entheses of lower limbs in psoriatic disease (with or without arthritis), revealing an high rate of enthesopathy signs [14, 41, 73], particularly for PwD activity. The results of the SLR supported the idea that enthesal PwD, rather than grey-scale (GS) changes, is a highly specific feature for PsA. However, the prognostic role of these lesions in the development of arthritis in Pso patients is not yet clear. There was only one prospective work by Tinazzi *et al.* [75] demonstrating that, in Pso patients, the baseline thickness of the quadriceps tendons was an independent predictor of PsA development, suggesting the need for further investigation in larger cohorts. Currently, in RA synovitis, tenosynovitis and bone marrow oedema appear to be predictors of radiographic progression and synonymous with disease activity [93, 98-100]. To date, in PsA, US predictors of poorer outcome have not

TABLE 4 Research Agenda of US in PsA and Pso patients

1. To investigate the integration of US in clinical practice in order to improve the certainty of diagnosis
2. To investigate which US elementary lesions could be highly specific for PsA
3. To investigate the prognostic role of US in identifying Pso patients at risk of developing PsA
4. To further analyse US score in order to monitor disease activity
5. To identify US predictors of treatment response in order to stratify treatment regimens (i.e. better selection of patients with poorer outcome)
6. To further analyse the supposed superiority of US-guided injection compared with palpation-guided injection

been identified; moreover, many studies have had an inappropriate design for evaluating prognostic measures. Since in RA T2T studies based solely on US did not prove a superiority of imaging over clinical management [101], the potential role of US in monitoring disease activity has to be tested, in addition to clinical follow-up. The integration of US with clinical examination for stratifying patients and for deciding treatments in a T2T strategy also represents an interesting possibility. The SLR identified few US scores for monitoring disease activity in PsA patients. The German US7 score, developed in RA, was the first applied and was able to significantly reflect the therapeutic response of PsA patients, evaluating synovitis, tenosynovitis and erosions [81]. Focusing on large joints, the SOLAR score, was used to evaluate activity in a cohort of PsA and AS patients, and Schafer *et al.* concluded that it was a valuable tool [88]. Furthermore, the Group of the Spanish Society of Rheumatology demonstrated that the PDUS examination of 14 peripheral entheses was able to monitor the response of SpA patients during anti-TNF therapy, and (interestingly) the authors highlighted that the score may contribute to the development of a cumulative scoring system of combined elementary lesions [86]. Considering the clinical heterogeneity of PsA with different domains and peculiar sites involved, a dedicated US composite score is arguably necessary. First, Gutierrez *et al.* [90] developed a PsA dedicated preliminary five-target score for the assessment of PsA patients during anti-TNF therapy. Later, Ficjan *et al.* [89] also proposed two PsA-specific US scores (PsASon-13 and PsASon-22) for monitoring disease activity in PsA. All these last three scores are original and interesting, but they are not applied in other series; thus, they remain preliminary scores, despite good sensitivity for the detection of inflammation and feasibility. Although there is extensive use in clinical practice, the superiority in terms of clinical outcome of US-guided injections over blinded injections remains doubtful in PsA, and further studies are needed in order to better define the efficacy of one over the other. US-guided injections were overall more accurate. Accordingly, Cunnington *et al.* recommended US-guided procedures in joints that were frequently injected inaccurately (e.g. shoulder, ankle, hip) and in order to reduce tissue necrosis or possible damage to surrounding tissues [94]. Thus, safety seems to be an advantage of US-guided injections. Although the SLR pointed up the importance and potential of US in the management of PsA and Pso, it

also underlined the need for a large amount of research into optimizing the use of US in the diagnosis and monitoring of psoriatic disease in clinical practice. In particular, several gaps in the literature were underlined, as well as the presence of possible biases (such as in patient selection, the reference standard for diagnostic studies and randomization in interventional studies). In addition, since the presence of publication bias was not investigated, it cannot be excluded. Based on the evidence arising from the SLR, a research agenda has also been proposed (Table 4). Considering the gaps in the literature underlined by the SLR, the Musculoskeletal Ultrasound Study Group of the Italian Society for Rheumatology gave priority to a novel study aiming to identify clinical and US predictors of Minimal Disease Activity in PsA patients with active peripheral arthritis starting a new course of therapy (Ultrasound in Psoriatic Arthritis Treatment study). Identifying prognostic factors for remission or low disease activity will improve selection of patients with poorer outcome and possibly guide therapeutic strategies, responding to the need for personalized medicine, optimizing the outcome for patients with PsA as well as for treatment management.

Acknowledgements

The participants of the Ultrasound in Psoriatic Arthritis Treatment (UPSTREAM) group have no role in the literature review, but they will be the subinvestigators of the new study of the Musculoskeletal US Study Group of the Italian Society of Rheumatology. The topic and the objectives of the UPSTREAM study were defined on the basis of the results of this systematic review. The UPSTREAM group includes the following: Andrea Delle Sedie; Antonella Draghessi; Alessandra Gabba; Alessandro Volpe; Andrea Di Matteo; Antonella Adinolfi; Bernd Raffener; Francesca Bandinelli; Alberto Batticciotto; Nicola Boffini; Alessandra Bortoluzzi; Carlo Venditti; Claudio Mastaglio; Scioscia Crescenzo; Daniela Rossi; Daniele Lubrano; Emanuela Bellis; Emilio Filippucci; Gentiana Vukatana; Georgios Filippou; Gianluca Santoboni; Giovanni Cagnotto; Giuseppe Scavo; Ilaria Tinazzi; Giuliana Maria Concetta La Paglia; Luca Idolazzi; Filippo Luccioli; Marco Canzoni; Maria Cristina Focherini; Pierluigi Macchioni; Marilena Frigato; Marta Caprioli; Michele Colaci; Giulia Mirabelli; Mirco Magnani; Marco Massarotti; Orazio De Lucia; Oscar Massimiliano Epis; Marco Piras; Roberta Ramonda;

Salvatore Bellinvia; Silvia Rossi; Simone Parisi; Matteo Piga; Riccardo Terenzi; Valentina Denaro; Viviana Ravagnani; Alen Zabotti; Garifallia Sakellariou; Carlo Alberto Scirè; Annamaria Iagnocco.

Funding: This study has been supported by the Musculoskeletal Ultrasound Study Group of the Italian Society for Rheumatology.

Disclosure statement: The authors have declared no conflicts of interest.

Supplementary data

Supplementary data are available at *Rheumatology* Online.

References

- Mandl P, Navarro-Compan V, Terslev L *et al*. EULAR recommendations for the use of imaging in the diagnosis and management of spondyloarthritis in clinical practice. *Ann Rheum Dis* 2015;74:1327–39. [TQ1]
- Gutierrez M, Filippucci E, De Angelis R *et al*. A sonographic spectrum of psoriatic arthritis: “the five targets.” *Clin Rheumatol* 2010;29:133–42.
- Kane D. The role of ultrasound in the diagnosis and management of psoriatic arthritis. *Curr Rheumatol Rep* 2005;7:319–24.
- Zabotti A, Salvin S, Quartuccio L, De Vita S. Differentiation between early rheumatoid and early psoriatic arthritis by the ultrasonographic study of the synovio-entheseal complex of the small joints of the hands. *Clin Exp Rheumatol* 2016;34:459–65.
- Coates LC, Helliwell PS. Treat to target in psoriatic arthritis—evidence, target, research agenda. *Curr Rheumatol Rep* 2015;17:1–6.
- Gutierrez M, Draghessi A, Bertolazzi C *et al*. Ultrasound in psoriatic arthritis. Can it facilitate a best routine practice in the diagnosis and management of psoriatic arthritis? *Clin Rheumatol* 2015;34:1847–55.
- Moher D, Liberati A, Tetzlaff J, Altman DG. PRISMA Group. Preferred reporting items for systematic reviews and meta-analyses: the PRISMA statement. *PLoS Med* 2009;6:e1000097.
- School of Social and Community Medicine, University of Bristol. QUADAS-2. <http://www.bristol.ac.uk/social-community-medicine/projects/quadas/quadas-2/> (11 October 2016, date last accessed).
- Higgins JPT, Altman DG, Sterne JAC, on behalf of the Cochrane Statistical Methods Group and the Cochrane Bias Methods Group. Chapter 8: Assessing risk of bias in included studies. http://handbook.cochrane.org/chapter_8/8_assessing_risk_of_bias_in_included_studies.htm (11 October 2016, date last accessed).
- Wells G, Shea B, O’Connell D, *et al*. Ottawa Hospital Research Institute. The Newcastle–Ottawa Scale (NOS) for assessing the quality of nonrandomised studies in meta-analyses. http://www.ohri.ca/programs/clinical_epidemiology/oxford.asp (11 October 2016, date last accessed).
- Abbas M, Suhail M, Ejaz A *et al*. Comparison of clinical and sonographical findings of achilles tendon involvement in newly diagnosed and established cases of psoriasis. *J Pak Assoc Dermatol* 2011;21:16–21.
- Acquacalda E, Albert C, Montaudie H *et al*. Ultrasound study of entheses in psoriasis patients with or without musculoskeletal symptoms: a prospective study. *Joint Bone Spine* 2015;82:267–71.
- Aydin SZ, Castillo-Gallego C, Ash ZR *et al*. Ultrasonographic assessment of nail in psoriatic disease shows a link between onychopathy and distal interphalangeal joint extensor tendon enthesopathy. *Dermatology* 2012;225:231–5.
- Aydin SZ, Ash ZR, Tinazzi I *et al*. The link between enthesitis and arthritis in psoriatic arthritis: a switch to a vascular phenotype at insertions may play a role in arthritis development. *Ann Rheum Dis* 2013;72:992–5.
- Balint PV, Kane D, Wilson H, McInnes IB, Sturrock RD. Ultrasonography of enthesal insertions in the lower limb in spondyloarthropathy. *Ann Rheum Dis* 2002;61:905–10.
- Bandinelli F, Denaro V, Prignano F *et al*. Ultrasonographic wrist and hand abnormalities in early psoriatic arthritis patients: correlation with clinical, dermatological, serological and genetic indices. *Clin Exp Rheumatol* 2015;33:330–5.
- Bandinelli F, Prignano F, Bonciani D *et al*. Ultrasound detects occult enthesal involvement in early psoriatic arthritis independently of clinical features and psoriasis severity. *Clin Exp Rheumatol* 2013;31:0219–24.
- Bonifati C, Elia F, Francesconi F *et al*. The diagnosis of early psoriatic arthritis in an outpatient dermatological centre for psoriasis. *J Eur Acad Dermatol Venereol* 2012;26:627–33.
- De Simone C, Caldarola G, D’Agostino M *et al*. Usefulness of ultrasound imaging in detecting psoriatic arthritis of fingers and toes in patients with psoriasis. *Clin Dev Immunol* 2011;2011:390726.
- Ciancio G, Volpinari S, Fotinidi M *et al*. Involvement of the inconstant bursa of the fifth metatarsophalangeal joint in psoriatic arthritis: a clinical and ultrasonographic study. *Biomed Res Int* 2014;2014:174841.
- Coari G, Iagnocco A, Mastrantuono M *et al*. Sonographic and NMR imaging study of sausage digit. *Acta Derm Venereol Suppl (Stockh)* 1994;186:33–4.
- De Agustín JJ, Moragues C, De Miguel E *et al*. A multi-centre study on high-frequency ultrasound evaluation of the skin and joints in patients with psoriatic arthritis treated with infliximab. *Clin Exp Rheumatol* 2012;30:879–85.
- De Simone C, Guerriero C, Giampietruzzi AR *et al*. Achilles tendinitis in psoriasis: clinical and sonographic findings. *J Am Acad Dermatol* 2003;49:217–22.
- Delle Sedie A, Riente L, Filippucci E *et al*. Ultrasound imaging for the rheumatologist XXVI. Sonographic assessment of the knee in patients with psoriatic arthritis. *Clin Exp Rheumatol* 2010;28:147–52.
- Delle Sedie A, Riente L, Filippucci E *et al*. Ultrasound imaging for the rheumatologist. XXXII. Sonographic assessment of the foot in patients with psoriatic arthritis. *Clin Exp Rheumatol* 2011;29:217–22.

- 26 Eder L, Jayakar J, Thavaneswaran A *et al.* Is the MADrid Sonographic Enthesitis index useful for differentiating psoriatic arthritis from psoriasis alone and healthy controls? *J Rheumatol* 2014;41:466–72.
- 27 Ezzat Y, Gaber W, Abd ELRSF, Ezzat M, El Sayed M. Ultrasonographic evaluation of lower limb entheses in patients with early spondyloarthropathies. *Egypt Rheumatol* 2013;35:29–35.
- 28 Falcao S, de Miguel E, Castillo-Gallego C *et al.* Achilles entheses ultrasound: the importance of the bursa in spondyloarthritis. *Clin Exp Rheumatol* 2013;31:422–7.
- 29 Falsetti P, Frediani B, Filippou G *et al.* Enthesitis of proximal insertion of the deltoid in the course of seronegative spondyloarthritis. An atypical enthesitis that can mime impingement syndrome. *Scand J Rheumatol* 2002;31:158–62.
- 30 Falsetti P, Frediani B, Fioravanti A *et al.* Sonographic study of calcaneal entheses in erosive osteoarthritis, nodal osteoarthritis, rheumatoid arthritis and psoriatic arthritis. *Scand J Rheumatol* 2003;32:229–34.
- 31 Farouk HM, Mostafa AAA, Youssef SS, Elbeblawy MMS, Assaf NY, Elokda ESE. Value of enthesal ultrasonography and serum cartilage oligomeric matrix protein in the pre-clinical diagnosis of psoriatic arthritis. *Clin Med Insights Arthritis Musculoskelet Disord* 2010;37–14.
- 32 Finzel S, Ohrndorf S, Englbrecht M *et al.* A detailed comparative study of high-resolution ultrasound and micro-computed tomography for detection of arthritic bone erosions. *Arthritis Rheum* 2011;63:1231–6.
- 33 Fiocco U, Ferro F, Cozzi L *et al.* Contrast medium in power Doppler ultrasound for assessment of synovial vascularity: comparison with arthroscopy. *J Rheumatol* 2003;30:2170–6.
- 34 Fournié B, Margarit-Coll N, Champetier de Ribes TL *et al.* Extrasynovial ultrasound abnormalities in the psoriatic finger. Prospective comparative power-doppler study versus rheumatoid arthritis. *Joint Bone Spine* 2006;73:527–31.
- 35 Frediani B, Falsetti P, Storri L *et al.* Quadriceps tendon enthesitis in psoriatic arthritis and rheumatoid arthritis: ultrasound examinations and clinical correlations. *J Rheumatol* 2001;28:2566–8.
- 36 Frediani B, Falsetti P, Storri L *et al.* Ultrasound and clinical evaluation of quadriceps tendon enthesitis in patients with psoriatic arthritis and rheumatoid arthritis. *Clin Rheumatol* 2002;21:294–8.
- 37 Freeston JE, Coates LC, Helliwell PS *et al.* Is there sub-clinical enthesitis in early psoriatic arthritis? A clinical comparison with power doppler ultrasound. *Arthritis Care Res Hoboken* 2012;64:1617–21.
- 38 Freeston JE, Coates LC, Nam JL *et al.* Is there subclinical synovitis in early psoriatic arthritis? A clinical comparison with gray-scale and power Doppler ultrasound. *Arthritis Care Res* 2014;66:432–9.
- 39 Galluzzo E, Lisch DM, Taglione E *et al.* Sonographic analysis of the ankle in patients with psoriatic arthritis. *Scand J Rheumatol* 2000;29:52–5.
- 40 Gutierrez M, Filippucci E, Salaffi F, Di Geso L, Grassi W. Differential diagnosis between rheumatoid arthritis and psoriatic arthritis: the value of ultrasound findings at metacarpophalangeal joints level. *Ann Rheum Dis* 2011;70:1111–4.
- 41 Gutierrez M, Filippucci E, De Angelis R *et al.* Subclinical enthesal involvement in patients with psoriasis: an ultrasound study. *Semin Arthritis Rheum* 2011;40:407–12.
- 42 Iagnocco A, Spadaro A, Marchesoni A *et al.* Power Doppler ultrasonographic evaluation of enthesitis in psoriatic arthritis. A multi-center study. *Joint Bone Spine* 2012;79:324–5.
- 43 Karreman MC, Weel AEAM, Van Der Ven M *et al.* Musculoskeletal complaints and psoriatic arthritis in primary care patients with psoriasis. *Arthritis Rheumatol* 2014;66:(Karreman M.C.; Weel A.E.A.M.; Van Der Ven M.; Vis M.; Nijsten T.E.C.; Hazes J.M.W.; Luime J.J.) Erasmus University Medical Center, Rotterdam, Netherlands):S694.
- 44 Koski JM, Saarakkala S, Helle M *et al.* Power Doppler ultrasonography and synovitis: correlating ultrasound imaging with histopathological findings and evaluating the performance of ultrasound equipments. *Ann Rheum Dis* 2006;65:1590–5.
- 45 Lin Z, Wang Y, Mei Y, Zhao Y, Zhang Z. High-frequency ultrasound in the evaluation of psoriatic arthritis: a clinical study. *Am J Med Sci* 2015;350:42–6.
- 46 Marchesoni A, De Lucia O, Rotunno L, De Marco G, Manara M. Enthesal power Doppler ultrasonography: a comparison of psoriatic arthritis and fibromyalgia. *J Rheumatol* 2012;39 (Suppl. 89):29–31.
- 47 Melchiorre D, Calderazzi A, Maddali Bongi S *et al.* A comparison of ultrasonography and magnetic resonance imaging in the evaluation of temporomandibular joint involvement in rheumatoid arthritis and psoriatic arthritis. *Rheumatology* 2003;42:673–6.
- 48 Milosavljevic J, Lindqvist U, Elvin A. Ultrasound and power Doppler evaluation of the hand and wrist in patients with psoriatic arthritis. *Acta Radiol* 2005;46:374–85.
- 49 Naredo E, Moller I, de Miguel E *et al.* High prevalence of ultrasonographic synovitis and enthesopathy in patients with psoriasis without psoriatic arthritis: a prospective case-control study. *Rheumatology* 2011;50:1838–48.
- 50 Pistone G, La Vecchia M, Pistone A, Bongiorno MR. Achilles tendon ultrasonography may detect early features of psoriatic arthropathy in patients with cutaneous psoriasis. *Br J Dermatol* 2014;171:1220–2.
- 51 Riente L, Delle Sedie A, Filippucci E *et al.* Ultrasound imaging for the rheumatologist XLV. Ultrasound of the shoulder in psoriatic arthritis. *Clin Exp Rheumatol* 2013;31:329–33.
- 52 Riente L, Delle Sedie A, Sakellariou G *et al.* Ultrasound imaging for the rheumatologist XXXVIII. Sonographic assessment of the hip in psoriatic arthritis patients. *Clin Exp Rheumatol* 2012;30:152–5.
- 53 Sankowski AJ, Iębkowska UM, Ćwikła J, Walecka I, Walecki J. The comparison of efficacy of different imaging techniques (conventional radiography, ultrasonography, magnetic resonance) in assessment of wrist joints and metacarpophalangeal joints in patients with psoriatic arthritis. *Pol J Radiol* 2013;78:18–29.
- 54 Scarpa R, Cuocolo A, Peluso R *et al.* Early psoriatic arthritis: the clinical spectrum. *J Rheumatol* 2008;35:137–41.

- 55 Solivetti FM, Elia F, Teoli M *et al.* Role of contrast-enhanced ultrasound in early diagnosis of psoriatic arthritis. *Dermatology* 2010;220:25-31.
- 56 Turner DE, Hyslop E, Barn R *et al.* Metatarsophalangeal joint pain in psoriatic arthritis: a cross-sectional study. *Rheumatology* 2014;53:737-40.
- 57 Weiner SM, Jurenz S, Uhl M *et al.* Ultrasonography in the assessment of peripheral joint involvement in psoriatic arthritis. *Clin Rheumatol* 2008;27:983-9.
- 58 Wiell C, Szkudlarek M, Hasselquist M *et al.* Ultrasonography, magnetic resonance imaging, radiography, and clinical assessment of inflammatory and destructive changes in fingers and toes of patients with psoriatic arthritis. *Arthritis Res Ther* 2007;9:R119.
- 59 Woodburn J, Hyslop E, Barn R, McInnes IB, Turner DE. Achilles tendon biomechanics in psoriatic arthritis patients with ultrasound proven enthesitis. *Scand J Rheumatol* 2013;42:299-302.
- 60 Zayat AS, Ellegaard K, Conaghan PG *et al.* The specificity of ultrasound-detected bone erosions for rheumatoid arthritis. *Ann Rheum Dis* 2015;74:897-903.
- 61 Rizzo G, Raffeiner B, Coran A *et al.* Pixel-based approach to assess contrast-enhanced ultrasound kinetics parameters for differential diagnosis of rheumatoid arthritis. *J Med Imaging* 2015;2:034503.
- 62 Yumusakhuylu Y, Kasapoglu E, Murat S *et al.* Similar enthesopathy scores by US in psoriatic arthritis and osteoarthritis. *Ann Rheum Dis* 2015;74 (Suppl 2):889-90.
- 63 Coates LC, Freeston JE, Nam J, Conaghan PG, Helliwell PS. Ultrasound identifies additional erosive disease in patients with early psoriatic arthritis - results from the Ticopa Study. *Ann Rheum Dis* 2015;74 (Suppl 2):353.
- 64 van der Ven M, Karreman M, Weel A *et al.* Ultrasound enthesitis in primary care psoriasis patients with musculoskeletal complaints. *Ann Rheum Dis* 2015;74 (Suppl 2):631.1-631.
- 65 Ceccarelli F, Ricci E, Rutigliano IM *et al.* Synovitis in patients with inflammatory arthropathies: comparison between rheumatoid arthritis and psoriatic arthritis evaluated by power-doppler ultrasound. *Ann Rheum Dis* 2015;74 (Suppl 2):882.
- 66 Acosta-Felquer M. Enteseal abnormalities and nail involvement at the distal interphalangeal joints on ultrasound examination in patients with psoriasis and psoriatic arthritis. Could the nail-enthesitis theory be supported? ACR Meeting Abstracts. <http://acrabstracts.org/abstract/enteseal-abnormalities-and-nail-involvement-at-the-distal-interphalangeal-joints-on-ultrasound-examination-in-patients-with-psoriasis-and-psoriatic-arthritis-could-the-nail-enthesitis-theory-be-supp/> (5 October 2016, date last accessed).
- 67 Bakewell CJ, Olivieri I, Aydin SZ *et al.* Ultrasound and magnetic resonance imaging in the evaluation of psoriatic dactylitis: status and perspectives. *J Rheumatol* 2013;40:1951-7.
- 68 Mendonça JA, Nogueira JP, Laurido IMM *et al.* Can spectral doppler identify nail enthesitis in psoriatic arthritis? *Ann Rheum Dis* 2014;73 (Suppl 2):659.
- 69 Fiocco U, Cozzi L, Rubaltelli L *et al.* Long-term sonographic follow-up of rheumatoid and psoriatic proliferative knee joint synovitis. *Br J Rheumatol* 1996;35:155-63.
- 70 Meenagh G, Filippucci E, Delle Sedie A *et al.* Ultrasound imaging for the rheumatologist XXX. Sonographic assessment of the painful knee. *Clin Exp Rheumatol* 2010;28:803-5.
- 71 Rubaltelli L, Fiocco U, Cozzi L *et al.* Prospective sonographic and arthroscopic evaluation of proliferative knee joint synovitis. *J Ultrasound Med* 1994;13:855-62.
- 72 Rezik S, Jrad M, Aouadi A *et al.* Assessment of achilles enthesitis in the spondyloarthritis by colour doppler ultrasound. *Ann Rheum Dis* 2015;74 (Suppl 2):743.
- 73 Gisondi P, Tinazzi I, El-Dalati G *et al.* Lower limb enthesopathy in patients with psoriasis without clinical signs of arthropathy: a hospital-based case-control study. *Ann Rheum Dis* 2008;67:26-30.
- 74 Husic R, Gretler J, Felber A *et al.* Disparity between ultrasound and clinical findings in psoriatic arthritis. *Ann Rheum Dis* 2014;73:1529-36.
- 75 Tinazzi I, McGonagle D, Biasi D *et al.* Preliminary evidence that subclinical enthesopathy may predict psoriatic arthritis in patients with psoriasis. *J Rheumatol* 2011;38:2691-2.
- 76 Özçakar L, Çetin A, İnanici F *et al.* Ultrasonographical evaluation of the Achilles' tendon in psoriasis patients. *Int J Dermatol* 2005;44:930-2.
- 77 Michelsen B, Diamantopoulos A, Kavanaugh A, Haugeberg G. Lack of correlation between clinical and ultrasonographic evidence of disease activity in psoriatic arthritis. *Ann Rheum Dis* 2014;73 (Suppl 2):733.
- 78 Negm AA, AL Araby S, Abdulazim E, Abul Ela M, AboGamal AF. Comparison between enthesopathy in psoriasis and psoriatic arthritis. (Clinical and ultrasonographic study). *Ann Rheum Dis* 2014; 73 (Suppl 2):1111-2.
- 79 Michelsen B. Sensitivity and specificity of clinical criteria to identify patients in ultrasound remission in psoriatic arthritis. ACR Meeting Abstracts. <http://acrabstracts.org/abstract/sensitivity-and-specificity-of-clinical-criteria-to-identify-patients-in-ultrasound-remission-in-psoriatic-arthritis/> (5 October 2016, date last accessed).
- 80 Marin J. Utility of power Doppler ultrasound-detected synovitis for the prediction of short term flare in psoriatic arthritis patients in clinical remission. ACR Meeting Abstracts. <http://acrabstracts.org/abstract/utility-of-power-doppler-ultrasound-detected-synovitis-for-the-prediction-of-short-term-flare-in-psoriatic-arthritis-patients-in-clinical-remission/> (5 October 2016, date last accessed).
- 81 Backhaus M, Ohrndorf S, Kellner H *et al.* Evaluation of a novel 7-joint ultrasound score in daily rheumatologic practice: a pilot project. *Arthritis Care Res* 2009;61:1194-201.
- 82 Cozzi F, Raffeiner B, Beltrame V *et al.* Effects of mud-bath therapy in psoriatic arthritis patients treated with TNF inhibitors. Clinical evaluation and assessment of synovial inflammation by contrast-enhanced ultrasound (CEUS). *Joint Bone Spine* 2015;82:104-8.

- 83 Fiocco U, Ferro F, Vezzù M *et al.* Rheumatoid and psoriatic knee synovitis: clinical, grey scale, and power Doppler ultrasound assessment of the response to etanercept. *Ann Rheum Dis* 2005;64:899–905.
- 84 Fraser AD, van Kuijk AW, Westhovens R *et al.* A randomised, double blind, placebo controlled, multicentre trial of combination therapy with methotrexate plus ciclosporin in patients with active psoriatic arthritis. *Ann Rheum Dis* 2005;64:859–64.
- 85 Keen HI, Mease PJ, Bingham CO III *et al.* Systematic review of MRI, ultrasound, and scintigraphy as outcome measures for structural pathology in interventional therapeutic studies of knee arthritis: focus on responsiveness. *J Rheumatol* 2011;38:142–54.
- 86 Naredo E, Battle-Gualda E, García-Vivar ML *et al.* Power doppler ultrasonography assessment of entheses in spondyloarthropathies: response to therapy of enthesal abnormalities. *J Rheumatol* 2010;37:2110–7.
- 87 Teoli M, Zangrilli A, Chimenti MS *et al.* Evaluation of clinical and ultrasonographic parameters in psoriatic arthritis patients treated with adalimumab: a retrospective study. *Clin Dev Immunol* 2012;2012:823854.
- 88 Schafer VS, Fleck M, Kellner H *et al.* Evaluation of the novel ultrasound score for large joints in psoriatic arthritis and ankylosing spondylitis: six month experience in daily clinical practice. *BMC Musculoskelet Disord* 2013;14:358.
- 89 Ficjan A, Husic R, Gretler J *et al.* Ultrasound composite scores for the assessment of inflammatory and structural pathologies in Psoriatic Arthritis (PsASon-Score). *Arthritis Res Ther* 2014;16:476.
- 90 Gutierrez M, Di geso L, Salaffi F *et al.* Development of a preliminary US power Doppler composite score for monitoring treatment in PsA. *Rheumatology* 2012;51:1261–8.
- 91 Ramírez García J, Inciarte-Mundo J, Ruiz-Esquide V *et al.* Comparative study on the presence of ultrasound sub-clinical synovitis between patients with RA and PSA in clinical remission or low disease activity in treatment with anti-TNF therapy. *Ann Rheum Dis* 2014;73 (Suppl 2):242.
- 92 Goncalves B, Ambrosio C, Serra S *et al.* US-guided interventional joint procedures in patients with rheumatic diseases – when and how we do it? *Eur J Radiol* 2011;79:407–14.
- 93 Di Geso L, Filippucci E, Meenagh G *et al.* CS injection of tenosynovitis in patients with chronic inflammatory arthritis: the role of US. *Rheumatology* 2012;51:1299–303.
- 94 Cunnington J, Marshall N, Hide G *et al.* A randomized, double-blind, controlled study of ultrasound-guided corticosteroid injection into the joint of patients with inflammatory arthritis. *Arthritis Rheum* 2010;62:1862–9.
- 95 Sibbitt WL, Band PA, Chavez-Chiang NR *et al.* A randomized controlled trial of the cost-effectiveness of ultrasound-guided intraarticular injection of inflammatory arthritis. *J Rheumatol* 2011;38:252–63.
- 96 Colebatch AN, Edwards CJ, Østergaard M *et al.* EULAR recommendations for the use of imaging of the joints in the clinical management of rheumatoid arthritis. *Ann Rheum Dis* 2013;72:804–14.
- 97 Sakellariou G, Scirè CA, Zambon A, Caporali R, Montecucco C. Performance of the 2010 classification criteria for rheumatoid arthritis: a systematic literature review and a meta-analysis. *PloS One* 2013;8:e56528.
- 98 Bellis E, Scirè CA, Carrara G *et al.* Ultrasound-detected tenosynovitis independently associates with patient-reported flare in patients with rheumatoid arthritis in clinical remission: results from the observational study STARTER of the Italian Society for Rheumatology. *Rheumatology* 2016;55:1826–36.
- 99 Døhn UM, Ejbjerg B, Boonen A *et al.* No overall progression and occasional repair of erosions despite persistent inflammation in adalimumab-treated rheumatoid arthritis patients: results from a longitudinal comparative MRI, ultrasonography, CT and radiography study. *Ann Rheum Dis* 2011;70:252–8.
- 100 Hetland ML, Ejbjerg B, Hørslev-Petersen K *et al.* MRI bone oedema is the strongest predictor of subsequent radiographic progression in early rheumatoid arthritis. Results from a 2-year randomised controlled trial (CIMESTRA). *Ann Rheum Dis* 2009;68:384–90.
- 101 Dale J, Stirling A, Zhang R *et al.* Targeting ultrasound remission in early rheumatoid arthritis: the results of the TaSER study, a randomised clinical trial. *Ann Rheum Dis* 2016;75:1043–50.