

Surgical Treatment of Diffuse Idiopathic Skeletal Hyperostosis (DISH) Involving the Cervical Spine: Technical Nuances and Outcome of a Multicenter Experience





Global Spine Journal

1-10

© The Author(s) 2021

Article reuse guidelines:
sagepub.com/journals-permissions
 DOI: 10.1177/2192568220988272
journals.sagepub.com/home/gsj



Giorgio Lofrese, MD¹, Alba Scerrati, MD^{2,3} , Massimo Balsano, MD⁴, Roberto Bassani, MD⁵, Michele Cappuccio, MD⁶, Michele A. Cavallo, MD^{2,3}, Fabio Cofano, MD⁷ , Francesco Cultrera, MD¹, Federico De Iure, MD⁶, Francesco Di Biase, MD⁸, Roberto Donati, MD¹, Diego Garbossa, MD, PhD⁷, Marta Menegatti, MD², Alessandro Olivi, MD^{9,10}, Giorgio Palandri, MD¹¹ , Antonino Raco, MD, PhD¹², Luca Ricciardi, MD¹³, Giannantonio Spena, MD, PhD¹⁴, Luigino Tosatto, MD¹ , Jacopo Visani, MD², Massimiliano Visocchi, MD^{9,10}, Gianluigi Zona, MD¹⁵, and Pasquale De Bonis, MD, PhD^{2,3}

Abstract

Study Design: Retrospective multicenter.

Objectives: Diffuse idiopathic skeletal hyperostosis (DISH) involving the cervical spine is a rare condition determining disabling aero-digestive symptoms. We analyzed impact of preoperative settings and intraoperative techniques on outcome of patients undergoing surgery for DISH.

Methods: Patients with DISH needing for anterior cervical osteophyctomy were collected. Swallow studies and endoscopy supported imaging in targeting bone decompression. Patients characteristics, clinico-radiological presentation, outcome and surgical strategies were recorded. Impact on clinical outcome of duration and time to surgery and different surgical techniques was evaluated through ANOVA.

Results: 24 patients underwent surgery. No correlation was noted between specific spinal levels affected by DISH and severity of pre-operative dysphagia. A trend toward a full clinical improvement was noted preferring the chisel ($P = 0.12$) to the burr ($P = 0.65$), and whenever C2-C3 was decompressed, whether hyperostosis included that level ($P = 0.15$). Use of curved chisel reduced the surgical times ($P = 0.02$) and, together with the nasogastric tube, the risk of complications, while bone removal involving 3 levels or more ($P = 0.04$) and shorter waiting times for surgery ($P < 0.001$) positively influenced a complete swallowing recovery. Early

¹ Neurosurgery Division, "M. Bufalini" Hospital, Cesena, Italy

² Department of Neurosurgery, S. Anna University Hospital, Ferrara, Italy

³ Department of Morphology, Surgery and Experimental Medicine, University of Ferrara, Ferrara, Italy

⁴ Regional Spinal Department, UOC Ortopedia A, AOUI, Verona, Italy

⁵ Spine Surgery II, IRCCS Istituto Ortopedico Galeazzi, Milan, Italy

⁶ Department of Spine Surgery, Ospedale Maggiore "C.A. Pizzardi," Bologna, Italy

⁷ Department of Neuroscience "Rita Levi Montalcini," Neurosurgery Unit, University of Turin, Turin, Italy

⁸ Department of Neurologic Surgery, San Carlo Hospital, Potenza, Italy

⁹ Department of Neurosurgery, Fondazione Policlinico Universitario A. Gemelli IRCCS, Rome, Italy

¹⁰ Department of Neuroscience, Neurosurgery Section, Università Cattolica del Sacro Cuore, Rome, Italy

¹¹ Department of Neurologic Surgery, Institute of Neurological Sciences of Bologna IRCCS, Bologna, Italy

¹² UOC di Neurochirurgia, Azienda Ospedaliera Sant'Andrea, Sapienza, Roma, Italy

¹³ UO di Neurochirurgia, Pia Fondazione di Culto e Religione Cardinal G. Panico, Tricase, Italy

¹⁴ Neurosurgery Unit, Ospedale Alessandro Manzoni, Lecco, Italy

¹⁵ Section of Neurosurgery, IRCCS Ospedale Policlinico San Martino, Genoa, Italy

Corresponding Author:

Alba Scerrati, Faculty of Medicine and Surgery, University of Ferrara, Via Aldo Moro, 8, Ferrara, Italy.
 Email: a.scerrati@gmail.com



decompressions were preferred, resulting in 66.6% of patients reporting disappearance of symptoms within 7 days. One and two recurrences respectively at clinical and radiological follow-up were registered 18-30 months after surgery.

Conclusion: The “age of DISH” counts more than patients’ age with timeliness of decompression being crucial in determining clinical outcome even with a preoperative mild dysphagia. Targeted bone resections could be reasonable in elderly patients, while in younger ones more extended decompressions should be preferred.

Keywords

DISH, Forestier syndrome, cervical hyperostosis, dysphagia, dysphonia, osteophyctomy

Abbreviations

DISH, diffuse idiopathic skeletal hyperostosis; OPLL, ossification of the posterior longitudinal ligament; CT, computed tomography; MRI, magnetic resonance imaging; ENT, ear-nose-and-throat; BMI, body mass index.

Introduction

Diffuse idiopathic skeletal hyperostosis (DISH) is characterized by flowing calcification and ossification of ligaments along the anterolateral aspects of at least 4 contiguous vertebral bodies, with relative preservation of disc height, in the absence of extensive degenerative changes of the intervertebral discs or apophyseal-sacroiliac joints.^{1,2} Although frequently asymptomatic, up to 78% of cases affecting the cervical spine result in dysphagia, dysphonia, hoarseness, regurgitation, lump or foreign body sensation, aspiration, sleep apnea and Horner’s syndrome.^{1,3} Anterior cervical osteophyctomy is considered highly effective and it is recommended whenever conservative management fails.¹ Since DISH is a very rare condition, most of the literature consists of case reports with few treated patients.⁴⁻¹⁵ Therefore, our aim was to combine the experience of different surgeons in treating this rare condition, particularly focusing on different preoperative settings and intra-operative technical nuances and on their effect on outcome, enriching the debate both on treatment strategies and natural history of this disease.^{3,12}

Methods

Twenty-two hospitals were included in the study, but only 12 of them were able to provide cases.

Patients were collected by consulting the electronic databases using ICD-9 code 721.6, over the period January 2008-January 2020.

The following parameters were recorded:

- reference center
- sex
- age
- main symptoms at onset
- diagnostic imaging
- extension of ossification
- level treated
- co-presence of ossification of posterior longitudinal ligament (OPLL)
- preoperative planning

- time to surgery
- surgery date
- duration of surgery
- surgical approach
- intraoperative strategies and technical nuances
- stabilization
- complications
- timing of resolution of symptoms
- clinical and radiological outcome
- need for a new intervention
- length of follow up

After data collection, we focused on the analysis of the different preoperative settings, intraoperative technical nuances and postoperative controls adopted by the surgeons to improve outcome.

The Ethics committee approval number is reported on title page for double-blind review. Informed consent was obtained from all participants.

Our manuscript adheres to Strobe guidelines.

Study Population

From January 2008 to January 2020, 24 consecutive patients treated for DISH were included in this retrospective analysis. All of them were diagnosed with DISH according to the Resnick criteria¹⁶ (Table 1) and none had missing data or resulted lost at follow-up. Each patient underwent surgery after failure of conservative strategies including postural changes when swallowing, diet modifications, non-steroidal anti-inflammatory drugs (NSAIDs), muscle relaxants, steroid pulse, and anti-reflux regimens. Those patients with an associated OPLL were excluded from the study.

Table 1. Resnick Criteria.

Resnick criteria

- 1) Flowing ossification and calcification of the anterior longitudinal ligament in at least 4 contiguous vertebral bodies
- 2) Absence of apophyseal joint ankylosis and sacroiliac joint sclerosis
- 3) Preservation of intervertebral disc height in the involved segments

Surgery

All surgeons adopted a standard Smith-Robinson approach to the cervical spine. Fluoroscopic guidance was used to perform the osteophylectomy, which was executed using curved osteotomes, rongeurs, and/or high-speed burr, with the goal of reducing the hyperostosis and re-establishing the native anterior vertebral contour. Care was taken to spare the annulus fibrosus and to differentiate between the relatively avascular osteophytic overgrowth and the more vascular vertebral body. Bleeding from the vertebral body was controlled with the application of bone wax or through the diamond burr.

Surgical times, technical nuances and postoperative complications were recorded.

Functional and Radiological Assessment

Before discharge, all the patients underwent postoperative cervical spine X-rays or CT-scan, and in some cases, an esophageal transit study was performed. Radiological outcome was usually evaluated at 6, 12 months and, in most of the cases, up to several years after surgery, through cervical spine CT scan or MRI in order to exclude recurrence. Clinical outcome was assessed during outpatient follow-up. Dysphonia, odynophagia, otalgia, aspiration, and dysphagia were investigated through an ENT evaluation with the dysphagia prospectively assessed according to the same severity scale adopted by Miyamoto et al.⁸: mild (abnormal sensation in the pharynx during swallowing solids or liquids); moderate (difficulty while

swallowing solid foods without difficulty with small amounts of liquid); severe, (no foods or drinks allowed to be swallowed).

Statistical Analysis

MedCalc, version 15.4 (1993-2015 MedCalc Software bvba) was used to perform all the statistical analyses. Student t-test for continuous variables and Chi-square test for categorical variables were adopted. The significance of changes was evaluated through repeated measures of analysis of variance (ANOVA) and this test was used even for evaluating the impact of different techniques on surgical time and for investigating the role of this latter, together with the waiting time for surgery, in determining clinical outcome. Were deemed statistically significant all the results showing $P \leq 0.05$.

Results

Patients Characteristics

Centers provided information on 24 patients, who underwent osteophylectomy for the treatment of dysphagia associated with prominent anterior cervical bony outgrowths. The mean age was 69.1 years, with a man/woman ratio of 7:1 and with men and elderly (>65 yo) representing respectively the 87.5% and 66.7% of the patient sample. Reported symptoms were dysphagia (41.7% mild, and 58.3% moderate) and dysphonia (16.7% of patients) (Table 2).

Table 2. Patients Characteristics, Clinical Symptoms, and Diagnostic Imaging.

Patient number	Age	Sex	Symptoms				Diagnostic exam
			Neck pain	Dysphagia	Dysphonia	Neurosigns	
1	62	M	N	Moderate	Y	N	MRI
2	78	M	N	Moderate	Y	N	MRI
3	85	M	Y	Mild	Y	N	CT
4	84	M	N	Mild	N	N	CT
5	75	M	N	Moderate	N	N	CT
6	50	F	N	Mild	N	N	MRI
7	82	M	N	Moderate	N	N	CT
8	81	M	N	Moderate	N	N	CT
9	59	M	N	Moderate	N	N	CT
10	73	F	N	Moderate	N	N	MRI
11	73	M	N	Mild	N	N	MRI
12	69	M	N	Mild	N	N	MRI
13	62	M	N	Mild	N	N	MRI
14	75	M	N	Moderate	N	N	MRI
15	73	M	N	Moderate	N	N	CT
16	50	M	N	Moderate	N	N	CT
17	53	M	Y	Mild	N	N	CT
18	69	M	Y	Mild	N	N	X-rays
19	70	M	N	Moderate	N	N	X-rays
20	67	F	Y	Mild	N	N	X-rays
21	58	M	N	Moderate	N	N	X-rays
22	64	M	Y	Moderate	N	N	X-rays
23	71	M	N	Mild	Y	N	MRI
24	77	M	N	Moderate	N	N	MRI

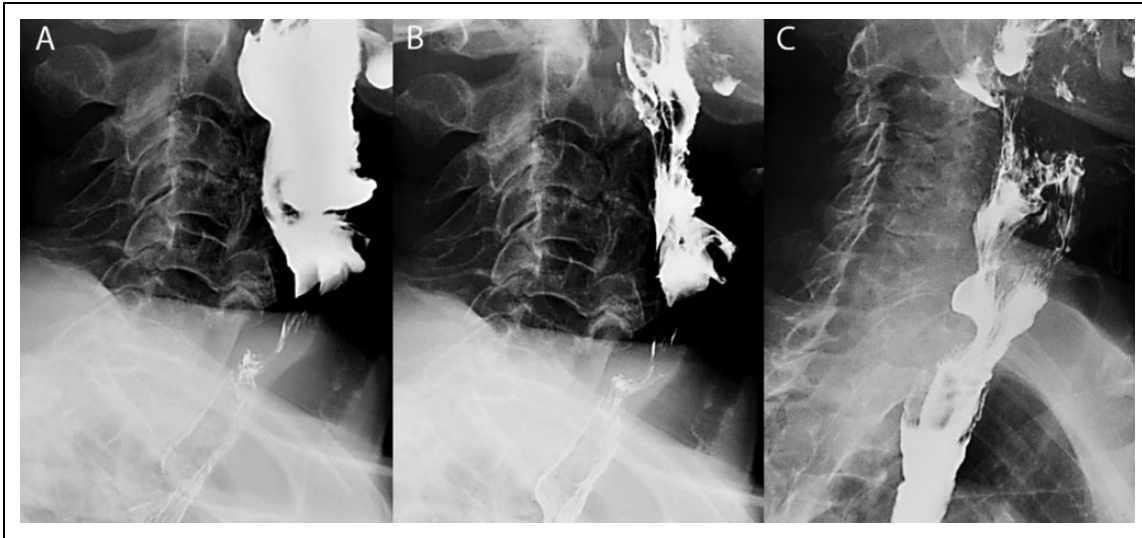


Figure 1. (A, B) preoperative video-fluoroscopic barium swallow study showing a severe C5-C6 obstruction sustained by a prominent DISH-related bony spur; (C) postoperative swallow study documenting the recovery of pharyngo-esophageal transit.

Preoperative Evaluation

Cervical spine MRI and CT scan represented the diagnostic examinations respectively in 41.7% and 37.5% of cases, while in the remaining 20.8% x-rays were the first imaging raising the suspicion of DISH.

In 54.2% of our sample, flowing ossifications of anterior longitudinal ligament involved 4 contiguous vertebral bodies, while a more extended hyperostosis was observed in 45.8% of the patients.

Every single case was preoperatively evaluated by an ENT-surgeon for excluding other causes of dysphonia and dysphagia. Video-fluoroscopic barium swallow studies completed the preoperative assessment in 58.3% of the patients, demonstrating the exact point of extrinsic pharyngo-esophageal compression by the osteophytes (Figure 1). In the remaining 41.7%, imaging was supplemented by a direct fiberoptic laryngoscopy, which provided a more accurate localization of the critical bony compression, ruling out weakening/perforations to the posterior pharyngeal wall, motility disorders/spasm, or intrinsic diseases of the vocal folds. Cervical osteophytes were always diagnosed as the unique cause of dysphagia and dysphonia. The mean waiting time for surgery was 239 days, during which conservative treatments were always maximized.

None of the patients showed concomitant neurological impairments and none of them needed for enteral feeding or gastrostomy before the intervention. In one case, a preoperative tracheostomy was performed, given presurgical respiratory complaints, but decannulation was possible 5 days after surgery.

Analysis of Surgical Findings

A standard Smith-Robinson approach to the cervical spine was always performed (left or right side respectively in 33.3% and 66.7% of the patients). A 2-level anterior decompression was

preferred in 41.7% of patients while a 3-4-level decompression was performed in 58.3% of patients. The mean surgical time was 139 minutes, and no patients underwent fusion.

Almost all the patients (91.7%) had nasogastric tube placed as a palpable landmark of the esophagus during both its dissection from the vertebral osteophytes and its retraction. Intraoperatively, osteophytes always revealed a blunt and smooth interface with the pharyngo-esophageal complex, although a moderate adhesion between the anterior aspect of the cervical hyperostosis and the surrounding connective tissue was always noted.

In 37.5% of cases, a curved chisel was preferred to high-speed burr and rongeur to complete the osteophylectomy; in 3 patients, such an osteotome allowed an “en-bloc” removal of the bony outgrowths, while perfectly preserving the anterior vertebral contour (Figure 2). High-speed burr was crucial both for creating a trough lateral to the osteophytes and for completing their removal, using fluoroscopy as guidance to avoid violating the vertebral body or the disc space. The curved chisel allowed a 66-minutes reduction in surgical times when preferred to the high-speed burr ($F [1, 22] = 5.579, P = 0.02$) (Figure 3). The most common levels decompressed were C4-C5 (95.8%), C3-C4 (83.3%), C5-C6 (58.3%) and C2-C3 (33.3%). No correlation was noted between levels most affected by DISH and severity of pre-operative dysphagia.

Hemostasis was achieved with bone wax in 29.2% of patients, while in the remaining cases diamond burr and abundant irrigation were preferred. No suspected instabilities were noted intraoperatively after the anterior bone removal.

Clinical and Radiological Outcome

Reported complications were: 1 transient palsy of the XII cranial nerve, 1 esophageal perforation, 2 cases of mild transient

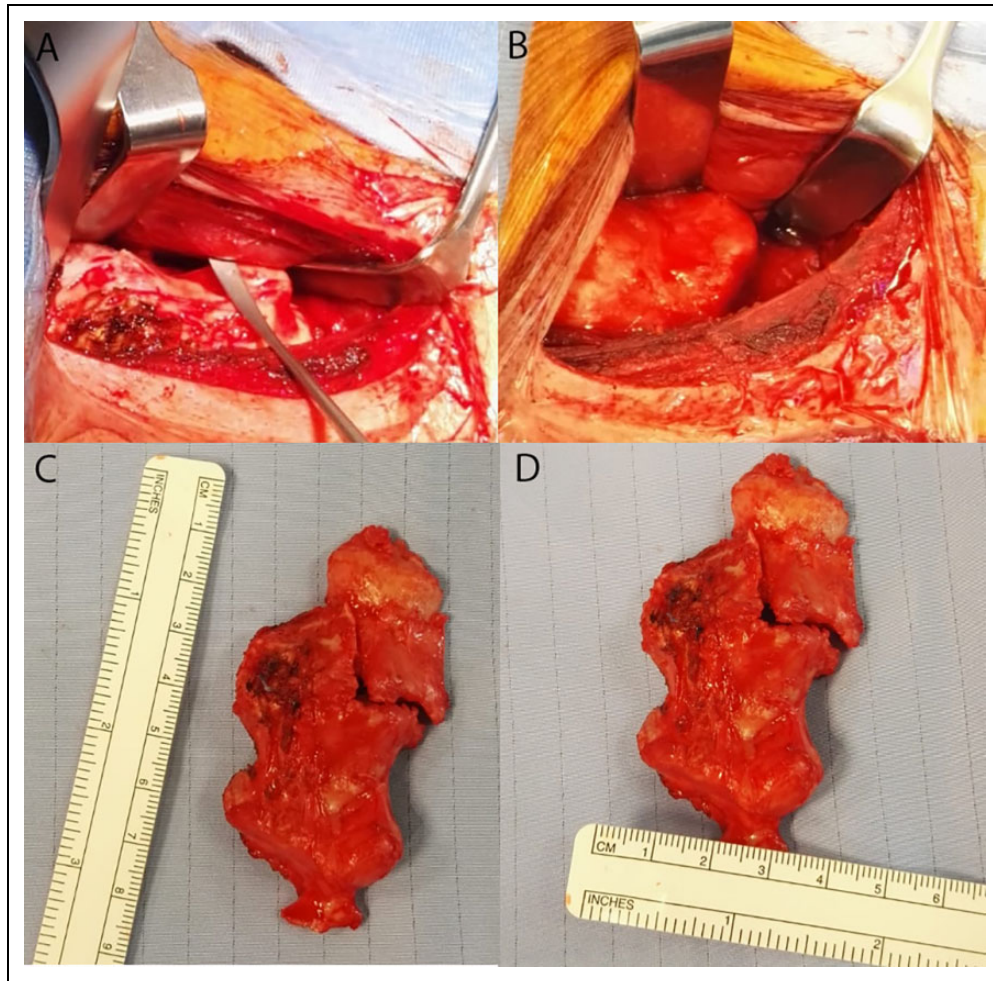


Figure 2. Dissection of the pharyngo-esophageal complex from the smooth surface of the osteophyte (A), until obtaining its complete exposure (B); (C, D) en-bloc excision of a multilevel bar-like osteophyte through the curved chisel.

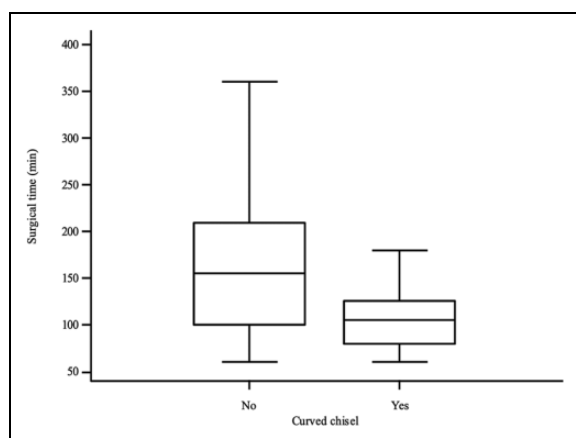


Figure 3. Differences of surgical time with and without the curved chisel for performing the osteophyctomy.

dysphonia, and 1 case with dysphagia and dysphonia unmodified despite the bone decompression.

The mean age of patients presenting or not complications was 76.4 and 67.2 years respectively ($F [1, 22] = 3.531, P =$

0.07) (Figure 4), with aging not influencing the chance for complete functional recovery ($F [1, 22] = 0.394, P = 0.53$). The side of surgical approach didn't affect clinical outcome or complication rate, with this latter being positively influenced by a short time to surgery ($F [1, 22] = 7.633, P = 0.01$). No differences in terms of complications were noted between osteophyctomies extended for 3 levels or more and those limited to 1-2 levels (Chi-squared, $P = 0.93$). The only case of intraoperative esophageal tear was determined by high-speed burr in one of the two patients without the nasogastric tube.

Shorter surgical time ($F [3, 20] = 1.507, P = 0.24$) and severity of pre-operative swallowing impairment (Chi-squared, $P = 0.66$) did not correlate with dysphagia improvement, while bone removal involving 3 levels or more (Chi-squared, $P = 0.04$) and a reduced waiting time for surgery ($F [1, 22] = 12.600, P = 0.002$) significantly influenced a complete swallowing recovery (Figure 5). A trend toward a full clinical improvement was noted preferring the chisel (Chi-squared, $P = 0.12$) to the burr (Chi-squared, $P = 0.65$) for the osteophyctomy, and whenever

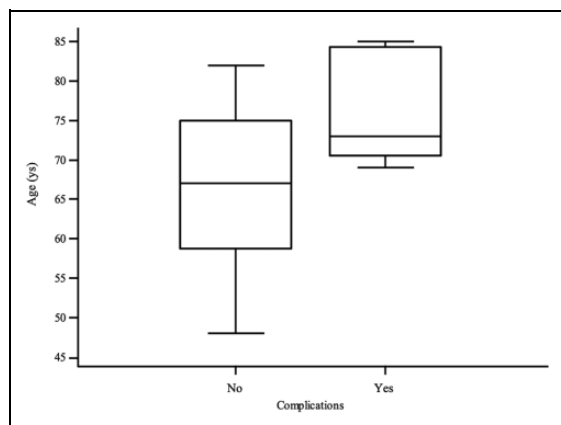


Figure 4. Age distribution of patients incurring or not in complications.

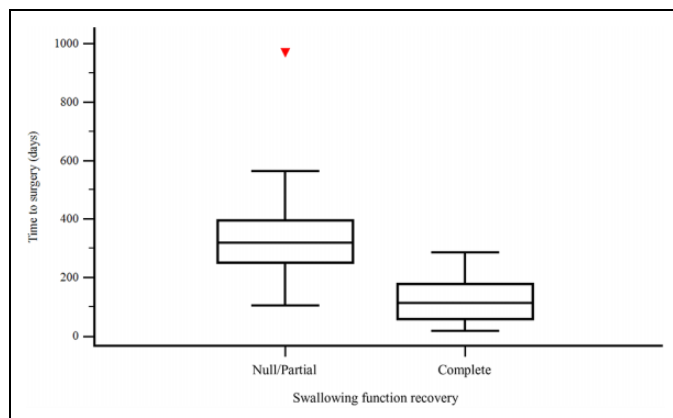


Figure 5. Swallowing function recovery (dichotomized) in relation to the waiting time for surgery

C2-C3 was decompressed whether hyperostosis included that level (Chi-squared, $P = 0.15$).

A significant recovery of complaints was reported within 7 days in 66.6% of the patients, within 3 months in 16.6%, and 6 months in 8.3% (Chi-squared, $P = 0.0004$).

Before discharge, all patients underwent cervical spine x-rays or CT scans and 25% of them underwent video-fluoroscopic barium swallow studies. Imaging revealed optimal bony removals after all the procedures, while video-fluoroscopy showed an immediate improvement of bolus transit in half of the patients (Figure 6). A complete resolution of osteophyte-related disorders was observed in 54.2% of patients, with 76.9% of them being over 65 years of age (Figure 7). A partial benefit after surgery with residual mild dysphagia was recorded in 33.3% of the cases, while 3 out of 4 patients showed a complete resolution of preoperative dysphonia.

The median follow-up was 24 months with 8 patients over 30 months and, among these, 4 over 60 months.

Only 2 radiological recurrences were observed respectively 18 and 30 months after discharge and no differences were noted in terms of reossification adopting bone wax or diamond burr to stop bone bleeding (Chi-squared, $P = 0.35$). Except for a single clinical recurrence registered 18 months after surgery, among all the patients no further clinical recurrences of pharyngo-esophageal or laryngeal disorders were reported at follow-up (Table 3).

Discussion

When facing dysphagia caused by DISH, symptoms typically develop in a chronic fashion, with aging playing a role in determining extension of hyperostosis¹⁷ and severity of

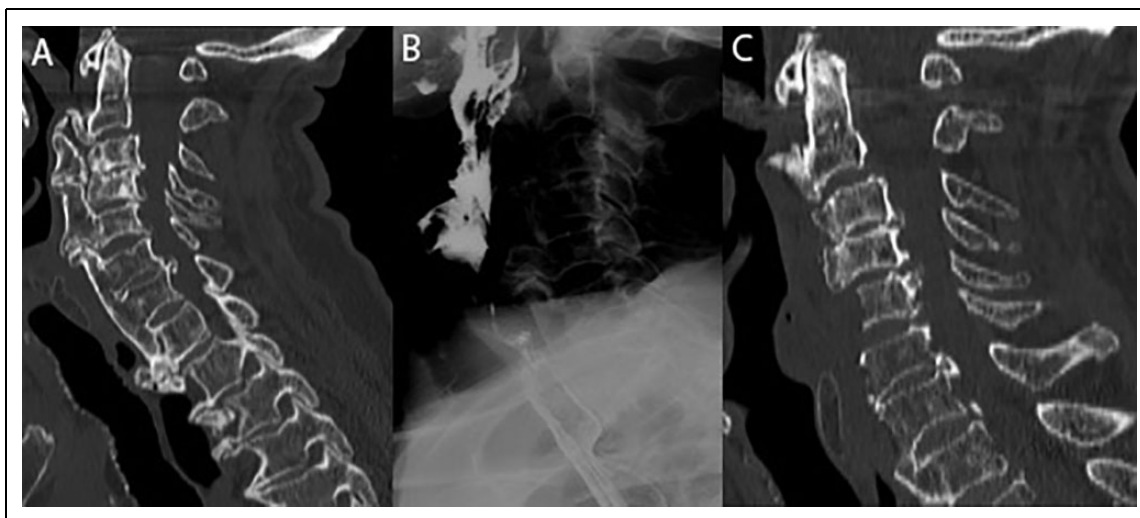


Figure 6. (A) Preoperative cervical spine CT-scan of an ultra-elderly patient suffering from an extended DISH with the most prominent bony spurs in T1-T2 and C5-C6; (B) preoperative videofluoroscopic barium swallow study showing a severe C5-C6 obstruction most likely responsible of symptoms (C) 12-month CT-scan control after C3-C7 bone decompression.

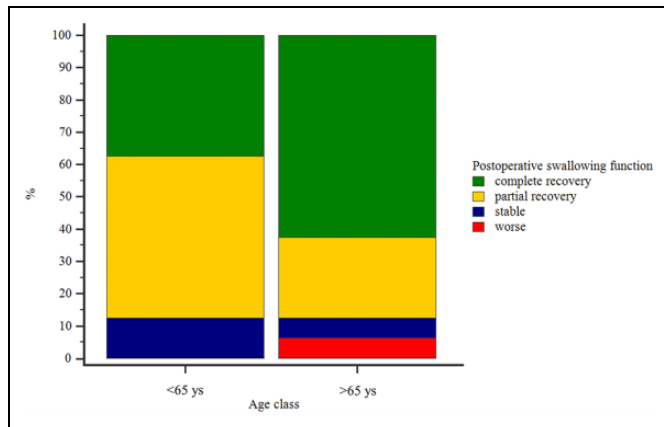


Figure 7. Recovery rates of swallowing function in patients less than or over 65 years of age. Postoperative swallowing function determined starting from the preoperative assessment of severity of dysphagia (mild, moderate, or severe).

symptoms. Timely detection of slowly progressive swallowing impairment may be critical.¹⁸ The geriatric patients in our series probably benefited from osteophylectomy, because it was performed before the development of severe dysphagia, chronic aspiration, or weight loss.¹⁹ Differently from other authors, we didn't observe patients with concomitant dyspnea.^{9,12} The pathogenesis of dysphagia caused by DISH could result from direct compression and local inflammation leading to mucosal edema, adhesion, fibrosis, and cricopharyngeal muscle spasm.¹⁹ This hypothetical mechanism, together with presbyphagia, supported an early resection of osteophytes even when the symptoms were mild.⁶ Swallow studies and endoscopy were always determinant in targeting bone decompression exclusively to those bony outgrowths primarily responsible for dysphagia, whenever extended resections would have been too risky. Nevertheless, complications resulted not correlated to the number of levels decompressed and duration of surgery, but trended to the elderly patients, with a higher rate over 65 years of age. Risk of iatrogenic esophageal tear in DISH may be higher than usual, because of the pharyngo-esophageal wall thinning secondary to peripharyngo-esophageal pressure, irritation, and adhesion.¹¹ The curved chisel helped in reducing these complications thanks both to a shorter surgical time and to the lower retraction force needed, since a retraction limited to the salient part of the osteophytes may be sufficient. In fact, while the traditional high-speed burr has to work over the entire surface of the hyperostosis progressively reducing its volume, therefore requiring a prolonged wide exposure, the curved chisel allows for an en-bloc resection by cutting the stem of the osteophyte under the protection of its own dome (Figure 8). Hence, the main risk of a pharyngo-esophageal perforation adopting a curved chisel could be mostly related to an increased compression while dislocating the bony spur, whether dissection of this latter from the surrounding tissues has not been adequately performed.²⁰ Whatever the technique adopted, we strongly suggest introducing a nasogastric tube to palpate it during identification, dissection,

and mobilization of pharynx and esophagus, since these organs are markedly deformed and particularly vulnerable in DISH patients.^{9,13}

The adoption of a curved chisel is favored by its shape, which perfectly fits the pattern of bone deposition similar to a bony sprout anchored to the anterior vertebral wall by a sort of stem.³ Some authors believe that anterior fusion is always necessary,^{8,13,21} whereas others suggest it for cases in which instability is apparent or suspected.⁹ In our surgical series, no intraoperative evidence of intrinsic instability were reported.²²

Our patients showed a marked improvement or a complete resolution of their upper aerodigestive disturbances mostly in a time frame between 7 days and 3 months,²³ with a trend toward a full swallowing recovery whenever the decompression was extended for 3 levels or more and the waiting time for surgery was preferably within the 200 days from the diagnosis. Excluding temporary dysphonia after long procedures, serious complications occurred in 8.3% of cases, as already reported.²⁴ Although the unique regrowth of anterior osteophytes was documented in a case without its application, we didn't ascertain the role of bone wax in reducing recurrence.²⁴

In our experience, except for a single patient who didn't benefit from surgery and one radiological re-ossification, no clinical recrudescences of DISH were noted among all the patients decompressed without fusion.¹¹

Although with the limitation of a relatively short follow-up, osteophyte recurrence could not be necessarily the norm.^{1,6} Therefore, in elderly patients, a limited bone resection might represent a reasonable strategy, while in younger patients more extended decompressions should be preferred, in association with long-term follow-up. Spine imaging and swallow studies are mandatory for excluding segmental instability and recurrences. In patients with moderate to severe symptoms and in those ones with persistent complaints despite optimal conservative treatment, surgery is recommended. In our experience instead, even a long history of mild dysphagia with radiological evidence of swallowing impairment could make early surgery highly advocated, because of the natural evolution of hyperostosis over years and the increased risk of complications with aging. Our results showed that timeliness of surgical decompression weighs more than advanced age in determining clinical outcome, with most patients who experienced a complete recovery of function being over 65 years of age. Nevertheless, the unfavorable outcomes recorded even in those cases with extended decompressions performed in short surgical times, remind us not to underestimate the fragility of elderly patients.

Limitations

The main limitations of this study lie in its retrospective design, in the fairly small patient sample, in the relatively short median follow up and in the evaluation of clinical outcome lacking specific scores for dysphagia.

Table 3. DISH Characteristics, Surgical Aspects, and Outcome.

Patient number	DISH		OPLL	Time of surgery (min)	Technical nuances	Fusion	Complications	Outcome				
	Levels involved	Levels treated						Dysphagia improvement	Clinical Recurrence	Radiological recurrence	Reintervention	Follow up (months)
1	<3	C2-C5	N	60	NG tube, chisel	N	N	Complete	N	N	N	42
2	<3	C2-C5	N	120	NG tube, chisel, wax	N	N	Complete	N	N	N	24
3	>3	C2-C7	N	125	NG tube, chisel, wax	N	Transient XII c.n. palsy, dysphonia	Worsening	N	N	N	12
4	>3	C3-C7	N	135	NG tube, chisel, wax	N	Transient dysphonia	Complete	N	N	N	18
5	>3	C2-C6	N	90	NG tube, burr	N	N	Partial	N	N	N	18
6	>3	C2-C4	N	101	NG tube, burr	N	N	Complete	N	N	N	18
7	>3	C3-C7	N	85	NG tube, chisel	N	N	Partial	N	N	N	20
8	>3	C3-C6	N	100	burr	N	N	Complete	N	N	N	30
9	>3	C3-C7	N	80	NG tube, chisel	N	N	Stable	Y	N	N	18
10	<3	C3-C5	N	60	NG tube, chisel, wax	N	N	Partial	N	N	N	18
11	<3	C4-C6	Y	160	NG tube, burr	Y	Transient dysphonia	Partial	N	N	N	24
12	<3	C3-C5	Y	180	NG tube, burr	Y	Esophageal tear	Stable	N	N	N	18
13	>3	C4-C6	Y	360	NG tube, burr	Y	N	Partial	N	Y	N	18
14	<3	C4-C6	N	75	NG tube, chisel	N	N	Complete	N	N	N	24
15	<3	C2-C5	N	120	NG tube, chisel, wax	N	N	Complete	N	N	N	20
16	<3	C3-C5	Y	150	burr	N	N	Partial	N	N	N	24
17	<3	C4-C6	N	120	NG tube, burr	N	N	Partial	N	N	N	42
18	<3	C3-C6	N	105	NG tube, chisel	N	N	Complete	N	N	N	132
19	>3	C2-C6	N	204	NG tube, burr	N	N	Complete	N	N	N	90
20	<3	C3-C5	N	215	NG tube, burr	N	N	Complete	N	N	N	66
21	<3	C2-C5	N	75	NG tube, burr	N	N	Complete	N	N	N	66
22	<3	C3-C5	Y	60	NG tube, burr	N	N	Partial	N	Y	N	30
23	>3	C3-C6	N	180	NG tube, burr, wax	N	Transient dysphonia	Complete	N	N	N	24
24	>3	C3-C7	N	220	NG tube, burr, wax	N	N	Complete	N	N	N	18

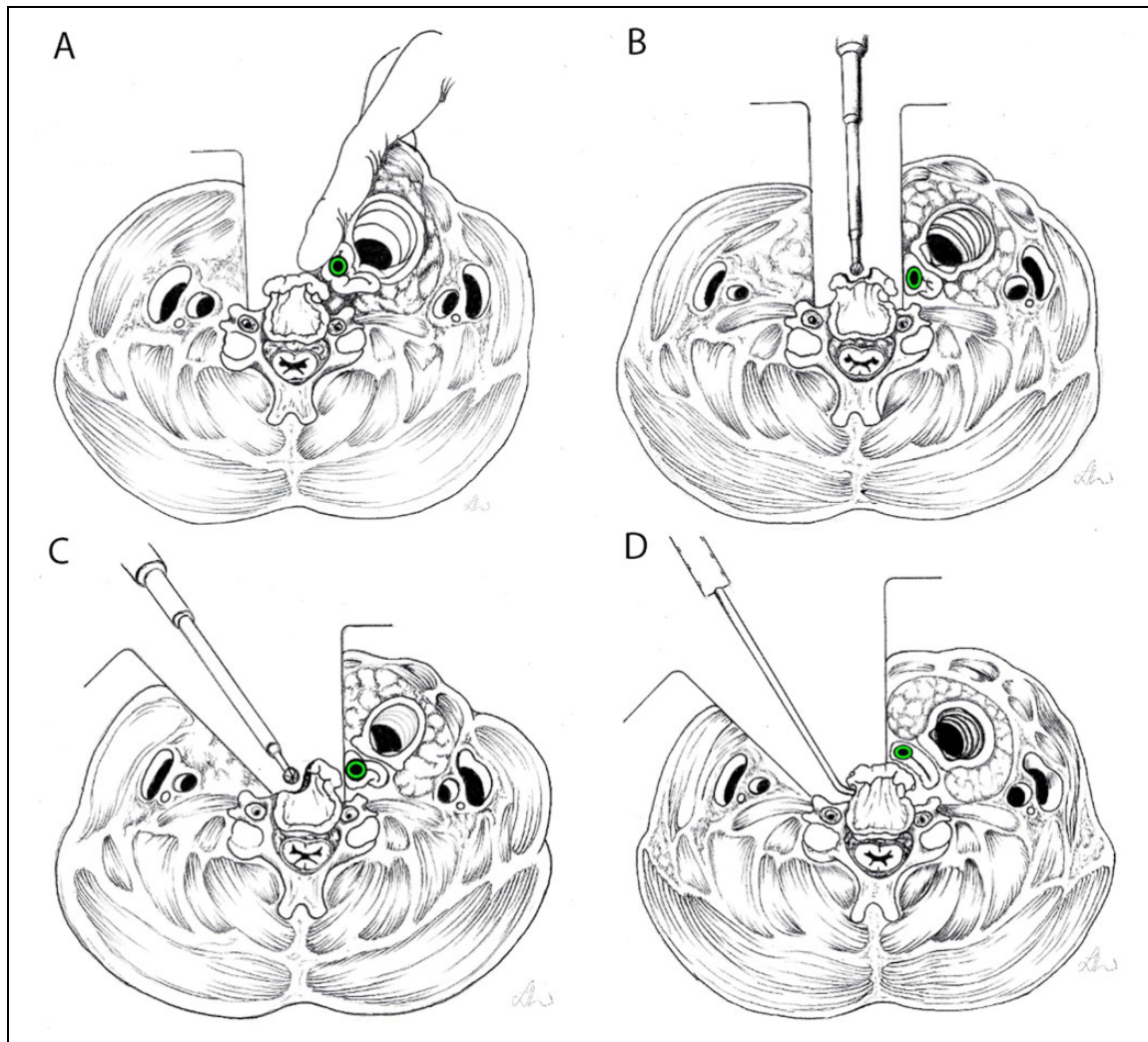


Figure 8. Schematic drawing representing the role of nasogastric tube as an important palpable landmark during pharyngo-esophageal dissection and retraction (A), and the different techniques adopted for the osteophylectomy: the progressive osteophyte removal through the high-speed burr, which mulls the dome of the bony spur (B) and its stem (C) under a wide exposure of the whole bony outgrowth, thus through a prolonged and intense retraction; the undercutting technique performed through the curved chisel (D), which allows the bony spur removal by truncating its stem and requiring a shorter and less intense retraction of pharyngo-esophageal complex.

Conclusion

Based on our results the “age of DISH” counted more than patients’ age in determining clinical outcome, therefore, especially in the elderly, timely bone decompressions appeared crucial, even with mild dysphagia, in presence of a long-lasting clinical history.

Preoperative CT and MRI, barium swallow studies, intraoperative nasogastric tube and curved chisel represent fundamental tools in the surgical management of this disease.

Larger studies assessing functional outcome of elderly patients with DISH, undergoing limited vs extended decompressions, would help in estimating the impact of these 2 different strategies. Further analysis on the severity of symptoms and timing of surgery in relation to functional recovery, morbidity, mortality, and odds of recurrence would contribute to define a treatment algorithm.

Although our study presents radiological recrudescences within 30 months, we believe reasonable to extend the follow-up of DISH even beyond 10 years especially in non-elderly patients, because of the increasing life expectancy and the multiple factors that can contribute to reossification.⁸ In this sense, further studies evaluating long-term outcome are needed.

Authors’ Note

Giorgio Lofrese and Pasquale De Bonis contributed equally to the paper. All authors (1) made substantial contributions to the conception or design of the work; or the acquisition, analysis, or interpretation of data; (2) drafted the work or revised it critically for important intellectual content; (3) approved the version to be published; and (4) agree to be accountable for all aspects of the work in ensuring that questions related to the accuracy or integrity of any part of the work are appropriately investigated and resolved.





Declaration of Conflicting Interests

The author(s) declared no potential conflicts of interest with respect to the research, authorship, and/or publication of this article.

Funding

The author(s) received no financial support for the research, authorship, and/or publication of this article.

ORCID iDs

Alba Scerrati, MD  <https://orcid.org/0000-0002-8607-5323>
 Fabio Cofano, MD  <https://orcid.org/0000-0002-5100-7478>
 Giorgio Palandri, MD  <https://orcid.org/0000-0002-9306-0242>
 Luigino Tosatto, MD  <https://orcid.org/0000-0002-8708-255X>

References

- Lui Jonathan YC, Sayal P, Prezerakos G, Russo V, Choi D, Casey ATH. The surgical management of dysphagia secondary to diffuse idiopathic skeletal hyperostosis. *Clin Neurol Neurosurg.* 2018;167:36-42.
- Resnick D, Niwayama G. Radiographic and pathologic features of spinal involvement in diffuse idiopathic skeletal hyperostosis (DISH). *Radiology.* 1976;119(3):559-568.
- Bakker JT, Kuperus JS, Kuijff HJ, Oner FC, de Jong PA, Verlaan JJ. Morphological characteristics of diffuse idiopathic skeletal hyperostosis in the cervical spine. *PLoS One.* 2017;12(11):e0188414.
- Fox TP, Desai MK, Cavenagh T, Mew E. Diffuse idiopathic skeletal hyperostosis: a rare cause of dysphagia and dysphonia. *BMJ Case Rep.* 2013;2013:bcr2013008978.
- Hirano H, Suzuki H, Sakakibara T, Higuchi Y, Inoue K, Suzuki Y. Dysphagia due to hypertrophic cervical osteophytes. *Clin Orthop Relat Res.* 1982;(167):168-172.
- Lecerf P, Malard O. How to diagnose and treat symptomatic anterior cervical osteophytes? *Eur Ann Otorhinolaryngol Head Neck Dis.* 2010;127(3):111-116.
- Mithani K, Meng Y, Pinilla D, et al. Diffuse idiopathic skeletal hyperostosis masquerading as asthma: case report. *J Neurosurg Spine.* 2019;31(2):261-264.
- Miyamoto K, Sugiyama S, Hosoe H, Inuma N, Suzuki Y, Shimizu K. Postsurgical recurrence of osteophytes causing dysphagia in patients with diffuse idiopathic skeletal hyperostosis. *Eur Spine J.* 2009;18(11):1652-1658.
- Sebaaly A, Boubez G, Sunna T, et al. Diffuse idiopathic hyperostosis manifesting as dysphagia and bilateral cord paralysis: a case report and literature review. *World Neurosurg.* 2018;111:79-85.
- Soejima Y, Arima J, Doi T. Diffuse idiopathic skeletal hyperostosis: a case with dysphonia, dysphagia and myelopathy. *Am J Case Rep.* 2019;20:349-353.
- Urrutia J, Bono CM. Long-term results of surgical treatment of dysphagia secondary to cervical diffuse idiopathic skeletal hyperostosis. *Spine J.* 2009;9(9): e13-e17.
- Verlaan JJ, Boswijk PF, de Ru JA, Dhert WJ, Oner FC. Diffuse idiopathic skeletal hyperostosis of the cervical spine: an underestimated cause of dysphagia and airway obstruction. *Spine J.* 2011;11(11):1058-1067.
- von der Hoeh NH, Voelker A, Jarvers JS, Gulow J, Heyde CE. Results after the surgical treatment of anterior cervical hyperostosis causing dysphagia. *Eur Spine J.* 2015;24(Suppl 4): S489-S493.
- McCafferty RR, Harrison MJ, Tamas LB, Larkins MV. Ossification of the anterior longitudinal ligament and Forestier's disease: an analysis of seven cases. *J Neurosurg.* 1995;83(1):13-17.
- Epstein NE. Simultaneous cervical diffuse idiopathic skeletal hyperostosis and ossification of the posterior longitudinal ligament resulting in dysphagia or myelopathy in two geriatric North Americans. *Surg Neurol.* 2000;53(5):427-431; discussion 431.
- Resnick D, Shaul SR, Robins JM. Diffuse idiopathic skeletal hyperostosis (DISH): Forestier's disease with extraspinal manifestations. *Radiology.* 1975;115(3):513-524.
- Mazieres B. Diffuse idiopathic skeletal hyperostosis (Forestier-Querelet disease): what's new? *Joint Bone Spine.* 2013;80(5): 466-470.
- Kos MP, van Royen BJ, David EF, Mahieu HF. Anterior cervical osteophytes resulting in severe dysphagia and aspiration: two case reports and literature review. *J Laryngol Otol.* 2009;123(10): 1169-1173.
- Carlson ML, Archibald DJ, Graner DE, Kasperbauer JL. Surgical management of dysphagia and airway obstruction in patients with prominent ventral cervical osteophytes. *Dysphagia.* 2011;26(1): 34-40.
- Carrara RL, Cintron FR, Astor F. Transcervical approaches to the prevertebral space. *Arch Otolaryngol Head Neck Surg.* 1990; 116(9):1070-1073.
- von Glinski A, Takayanagi A, Elia C, et al. Surgical treatment of ossifications of the cervical anterior longitudinal ligament: a retrospective cohort study [published online May 19, 2020]. *Global Spine J.* 2020. doi:10.1177/2192568220922195
- Sobol SM, Rigual NR. Anterolateral extrapharyngeal approach for cervical osteophyte-induced dysphagia. Literature review. *Ann Otol Rhinol Laryngol.* 1984;93(5 Pt 1):498-504.
- Goh PY, Dobson M, Iseli T, Maartens NF. Forestier's disease presenting with dysphagia and dysphonia. *J Clin Neurosci.* 2010;17(10):1336-1338.
- Egerter AC, Kim ES, Lee DJ, et al. Dysphagia secondary to anterior osteophytes of the cervical spine. *Global Spine J.* 2015; 5(5):e78-e83.