

Modified Outflow Reconstruction with a Venous Patch in Domino Liver Transplantation

Matteo Cescon, Gian Luca Grazi, Matteo Ravaioli, Alessandro Cucchetti, Giorgio Ercolani, and Antonio Daniele Pinna

Liver and Multiorgan Transplant Unit, Department of Surgery and Transplantation, University of Bologna, Bologna, Italy

Received March 2, 2007; accepted March 6, 2007.

Domino transplantation (DT) with livers from recipients with metabolic diseases is a well recognized tool for expanding organ availability. The best technique for caval anastomosis in DT recipients is not well defined. We devised a new technique for outflow reconstruction that was adopted in 3 cases of DT, in which all donors had familial amyloidotic polyneuropathy.

DT DONOR HEPATECTOMY

All DT donors received a whole liver graft from a deceased donor. DT donor hepatectomy was performed with preservation of the inferior vena cava. Short veins draining the caudate lobe were sutured. In two cases, the classic piggyback technique¹ was used with an end-to-end anastomosis between the stump of the three major hepatic veins (right, middle, and left) and the donor suprahepatic inferior vena cava. In order to keep the hepatic vein cuff long enough to perform a piggyback reconstruction, no attempt was made to obtain a long caval stump in the native liver. In 1 case, the 3 major hepatic veins lying on different transversal planes were sutured and an end-to-side cavo-caval anastomosis was performed.

In all cases, the orifices of major hepatic veins of the amyloidotic livers did not have sufficient tissue to perform a direct anastomosis with the caval cuff of the DT recipients, in whom a piggyback reconstruction had been planned (Fig. 1).

BACK-TABLE PREPARATION OF THE GRAFTS

At the back table, a vascular graft including the lower portion of the inferior vena cava in continuity with the

left or right common iliac vein harvested from the deceased donor was used. The conduit was opened longitudinally and placed upon the above-mentioned venous stumps with its inferior wall, which was opened circularly in correspondence with each venous orifice and anastomosed with an everting 6/0 polypropylene suture. A venoplasty between the stumps of the amyloidotic graft was performed whenever possible. In the first case, a venoplasty was performed between 1 vein draining segment IV and the middle hepatic vein, and between a right superficial vein and the main trunk of the right hepatic vein, whereas 1 vein draining the caudate lobe was anastomosed separately. In the second case, 1 vein from the caudate lobe was anastomosed separately and a venoplasty was performed between the middle and left hepatic veins. In the third case, a venoplasty was performed between a common stump including the left hepatic vein and 1 vein from the caudate lobe, and the middle hepatic vein, while a common cuff including the main and the superficial right hepatic veins was anastomosed directly (Fig. 2).

The external edge of the vascular graft was trimmed in order to obtain a circular stump, which was anastomosed end-to-end with the recipient cuff formed by the right, middle, and left hepatic veins using an everting 5/0 polypropylene suture. Back-table preparation required less than 45 minutes in all cases.

LIVER TRANSPLANT PROCEDURES AND OUTCOME

DT recipient procedures were carried out with standard techniques, without caval clamping. Ischemia time was 525, 290, and 212 minutes, respectively. Operation

Abbreviation: DT, domino transplantation.

Address reprint requests to Matteo Cescon, M.D., Unità Operativa Chirurgia Trapianti di Fegato e Multiorgano, Padiglione 25, Policlinico Sant'Orsola-Malpighi, Via Massarenti, 9, 40138 Bologna, Italy. Telephone: 39-051-6364810; FAX: 39-051-304902; E-mail: matteo.cescon@aosp.bo.it

DOI 10.1002/lt.21180

Published online in Wiley InterScience (www.interscience.wiley.com).

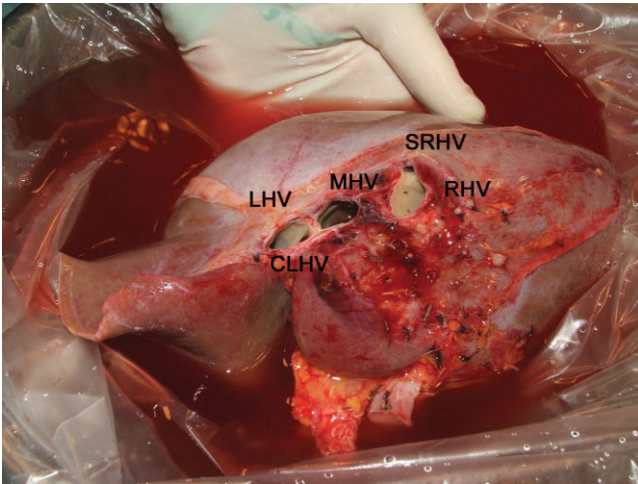


Figure 1. Amyloidotic liver graft with the orifices of the caudate lobe hepatic vein (CLHV), left hepatic vein (LHV), middle hepatic vein (MHV), right hepatic vein (RHV), and superficial right hepatic vein (SRHV).

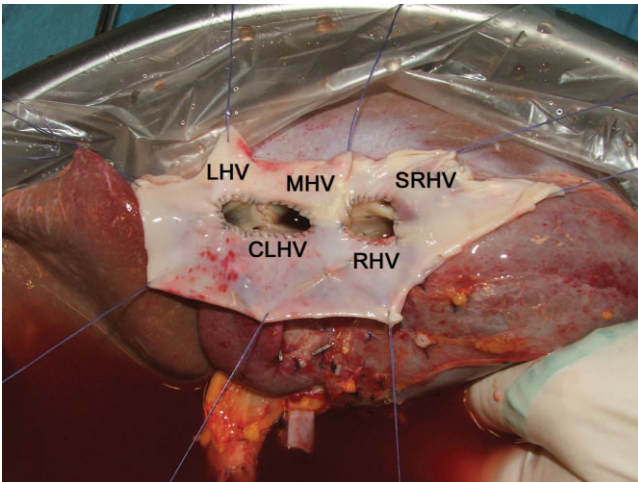


Figure 2. Venous patch anastomosed to the orifices formed by the caudate lobe hepatic vein (CLHV), left hepatic vein (LHV), and middle hepatic vein (MHV), and by the right hepatic vein (RHV) and superficial right hepatic vein (SRHV).

time was 345, 405, and 255 minutes, respectively. Packed red blood cell transfusion was 650, 1,000, and 0 mL, respectively.

Postoperatively, Doppler ultrasound showed normal triphasic flow into all major hepatic veins of the amyloidotic liver in all cases. All DT recipients showed normal liver function and excellent clinical conditions within 2 weeks of transplantation.

The technique described above allowed liver transplantation procedures to be safely performed with preservation of the inferior vena cava and without venovenous bypass. The use of venous grafts, including inferior vena cava and iliac bifurcation, and portal vein bifurcation have been described in other studies.^{2,3} However, a conduit with 2 terminal stumps may not be anastomosed to multiple venous cuffs and could have limited possibilities of orientation, determining outflow problems because of torsion.⁴ In our technique, 2 advantages can be recognized: the possibility of anastomosing several venous orifices to a single patch and of preventing outflow obstruction by creating a wide and adaptable cuff.⁵

REFERENCES

1. Tzakis A, Todo S, Starzl TE. Orthotopic liver transplantation with preservation of the inferior vena cava. *Ann Surg* 1989;210:649-652.
2. Cerqueira A, Pacheco-Moreira L, Enne M, Alves J, Amil R, Balbi E, Martinho JM. Outflow reconstruction in domino liver transplantation with interposition of autologous portal vein graft. A new technical option in living donor domino liver transplant scenario. *Liver Transpl* 2006;12:1298-1300.
3. Jabbour N, Gagandeep S, Genyk Y, Selby R, Mateo R. Caval preservation with reconstruction of the hepatic veins using caval-common iliac bifurcation graft for domino liver transplantation. *Liver Transpl* 2006;12:324-325.
4. Aucejo F, Winans C, Henderson JM, Vogt D, Eghtesad B, Fung JJ, et al. Isolated right hepatic vein obstruction after piggyback liver transplantation. *Liver Transpl* 2006;12:808-812.
5. Sugawara Y, Makuuchi M, Imamura H, Kaneko J, Kokudo N. Outflow reconstruction in extended right liver grafts from living donors. *Liver Transpl* 2003;9:306-309.