



Case Report

Case Report: Endovascular Approach for Iatrogenic Artery Damage in Covid-19 Pandemic Era

Zairo Ferrante¹, Roberto Galeotti¹, Marianna Mucignat^{2*}, Giorgia Castrucci², Vincenzo Gasbarro², Andrea Saletti³

¹Unit of Vascular and Interventional Radiology, Department of Radiology, Arcispedale S. Anna University Hospital, Ferrara, Italy

²Unit of Vascular and Endovascular Surgery, Arcispedale S. Anna University Hospital, Ferrara, Italy

³Unit of Interventional Neuroradiology, Department of Radiology, Arcispedale S. Anna University Hospital, Ferrara, Italy

***Corresponding author:** Marianna Mucignat, Unit of Vascular and Endovascular Surgery, Arcispedale S. Anna University Hospital, Ferrara, Italy

Citation: Ferrante Z, Galeotti R, Mucignat M, Castrucci G, Gasbarro V, et al. (2020) Case Report: Endovascular Approach for Iatrogenic Artery Damage in Covid-19 Pandemic Era. Ann Case Rep: 14: 443. DOI: 10.29011/2574-7754.100443

Received Date: 09 July, 2020; **Accepted Date:** 13 July, 2020; **Published Date:** 20 July, 2020

Abstract

Since February, the Italian sanitary system and his healthcare workers are facing COVID-19 pandemic; however, some Operative Units (such as Interventional Radiology and Vascular Surgery) appear to have higher contagion risk, because of the closer contact, needed by their specialty, with the patient and for the invasive operations needed for patient's treatment.

This is more and more making mandatory the needing to develop and use new guidelines to decrease contagion risk. In this case report we describe our experience in a case of intervention for the treatment of an active bleeding in a COVID-19 positive patient.

Keywords: Arterial damage; COVID-19; Endovascular

Introduction

COVID-19 pandemic has radically changed the routinary activity of healthcare workers, focusing the procedures on Coronavirus positive patients. This caused the stopping or delaying of all election treatments due to limit further contagion and to concentrate all the resources in this emergency. This event cannot stop urgency and emergency activity, such as interventional radiology and endovascular surgery procedures, but we also must protect the healthcare personnel with all the individual protection devices (DPI) and guarantee the best medical practice for the patients.

In this case report we describe our experience in a case of intervention for the treatment of an active bleeding in a COVID-19 positive patient.

Case Report

An 83 y.o. female came to the Emergency Department (A&E) on 15th March 2020 for an atraumatic syncope episode after a week of continuous diarrhea. The woman doesn't have any other symptoms or fever, but refers that her son had contact with a group of people COVID-19 but his son's exams were completely negative

for Coronavirus. An X-ray thorax scan revealed a pulmonary opacity on the right upper lobe, so the pneumologist prescribed an HRCT scan: the imaging showed a large area of parenchyma with "ground glass" and "crazy paving", with interstitial involvement. The infectivologist opinion was asked and, despite the CT scan signs, the patient was discharged because of the lack of symptoms. The patient was asked to do the swab for COVID-19 the day after, but it was negative.

On the 20th March the patient came back to A&E because of her worsening symptoms, with high fever and dyspnea. The HRCT scan was repeated and showed a dimensional increase of the areas with crazy paving and ground glass aspect, with the extension to both lungs. The patient was then transferred to the Infectious Disease department and made another swab for Coronavirus. The day after, the patient's symptoms were progressively worsening with confusion, tachypnoea, desaturation (SpO₂ of 67% without support, and of 80% with an O₂ reservoir mask at 20L/min). Life support therapy was then performed and in the following days the patient's conditions were stabilized.

For a better therapeutic management, a central venous access was positioned in superior vena cava, with a right subclavian approach. In the next days a clinical worsening was observed, associated to progressive anemia: with a suspect of bleeding, a

thorax-abdomen CT scan with contrast medium was performed, revealing a large hematoma in the right subclavian area with extension in the right lateral hemithorax, with active bleeding signs from right subclavian artery, but without any precise location. The radiologist suspected a lesion of a small branch of the posterior subscapular portion of the subclavian artery. The imaging also revealed a 2cm pseudoaneurysm of the right common carotid artery (Figure 1).

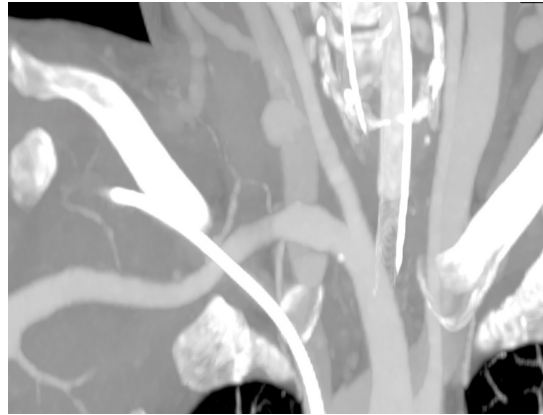


Figure 1: CT scan multiplanar reconstruction of carotid artery pseudoaneurysm.

The patient then underwent to an urgency angiogram, to clarify the position of the active bleeding spot, with the discovery of a small laceration of the upper-anterior wall in the intermedium portion of the right subclavian artery and the confirmation of the presence of a pseudoaneurysm of the proximal tract of the homolateral common carotid artery (Figure 2).

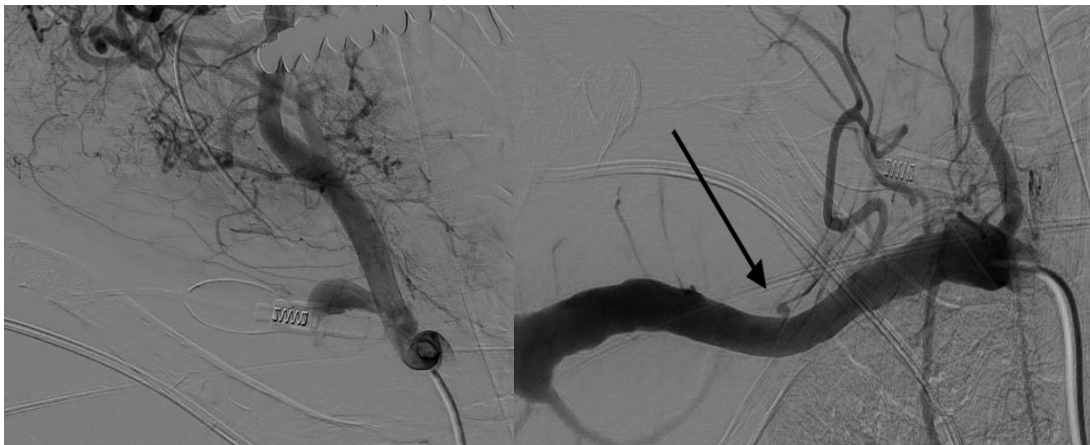


Figure 2: Angiogram showing (a) pseudoaneurysm of the right common carotid artery (b) laceration of the upper-anterior wall of the right subclavian artery (arrow).

Materials and Methods

The case was collectively discussed between the vascular surgeon and the interventional radiologist, with the decision to act with the endovascular approach, due to stop the bleeding quickly and safely.

Two stent-graft, both 8x57mm (Bentley BeGraft peripheral and Jotec E-Ventus BX stent) were positioned in the right subclavian artery and in the common carotid artery, with a percutaneous femoral artery access, solving the bleeding with the correct restoration of the blood flow and patency of the stents (Figure 3).

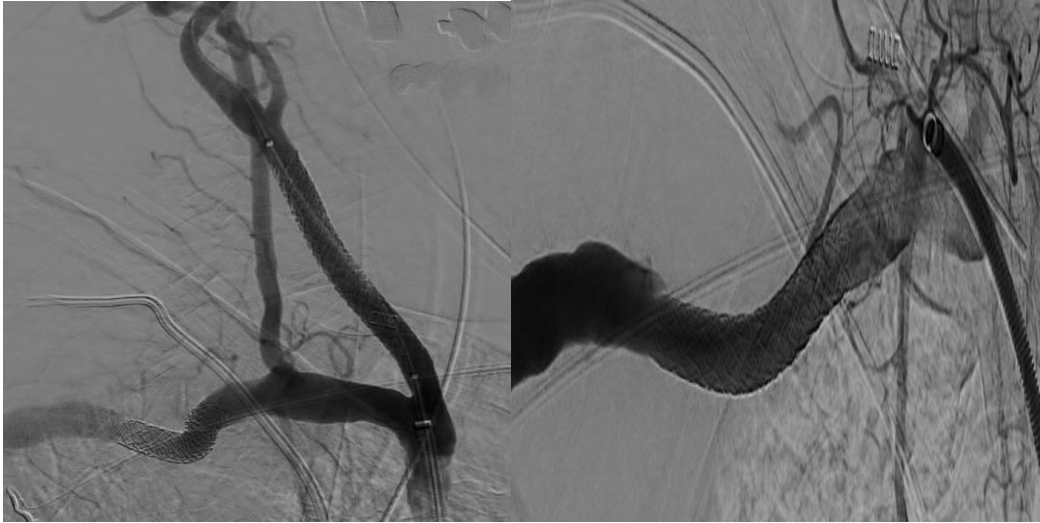


Figure 3: Post-procedure angiogram showing (a) right common carotid artery stenting (b) right subclavian artery stenting.

Patient's drug therapy was updated with dual antiplatelet therapy, due to prevent occlusion of the carotid stent [1]. At the time of this case report, no IRB existed in our institute. We declare that the latest principles of the Declaration of Helsinki (2013) were followed.

Discussion

At the time of the writing of this case (24th April 2020), the Italian Health Ministry data on COVID-19 pandemic reported the presence of 2807 hospitalized patients with 3300 deaths reported only in Emilia-Romagna region, even though Ferrara district appears to be in the less affected, with 877 declared deaths.

From the beginning of the pandemic, our hospital followed all the Italian Health Ministry recommendations, with the institution of dedicated pathways for Coronavirus positive patients and this changed also our Interventional Radiology service, in order to protect the healthcare workers and the patients.

The first step provides a close communication with the clinical team and the interventional radiology team, due to divide the patients basing on the risk of transmission of the virus, avoiding the contact with COVID-19-free patients [2].

All elective activity was suspended for extra-hospital patients, concentrating the activities exclusively on urgencies/emergencies and in-patients.

The DPI's for the operatory theater personnel were augmented: beside the standard equipment (represented by leaded gown, sterile gown, sterile gloves and surgical cap), a fundamental role is played by FFP-2 and 3 filtered masks used in addition to the surgical mask, which is worn over the filtered mask, allowing the protection for both the operator and the patient. Moreover, a protective medical visor is used for facial and ocular protection and another layer of sterile gown, sterile gloves and a sterile cover

for shoes completes the protection.

In our case report, we describe an example of how we must act in an urgency set, despite the infection of the patient. We must say that in normal conditions, an open surgical repairing of the subclavian artery and the correction of the pseudoaneurysm with a latero-cervical access, would have been an optimal treatment for this complication, but under Coronavirus pandemic events, this would have expose the Vascular Surgeons at a higher risk of contagion and an open surgery could have also expose the patient to an overinfection, because of the compromised conditions of the patient herself.

In this case, the laceration of the subclavian and the common carotid artery appear to be iatrogenic, caused by the positioning of the central venous catheter. Literature describes that this kind of complication of the procedure is rare, but can represent the 2-4,5% of the cases [3,4], causing also severe complications for the patients almost in 30% of the cases [5], such as hematoma (our case), haemothorax, stroke and neurological damages.

This event must also be considered because of the high number of people in the pandemic hospitalized in Intensive Care Unit, which require CVC for a better therapy management. It's also important to precise that the therapeutic protocol for COVID-19 treatment provides the administration of low molecular weight heparin (LMWH), showing a notable success in China for its anti-inflammatory effects in the lungs, with a mortality reduction at

28 days in patients with high D-dimer [6-9]. On the other side, LMWH administration is associated to higher risk of spontaneous bleeding. In our case, this was an additive for the fast worsening of patient's conditions, considering also that the age of the patient made her coagulation less efficient, resulting in a rapid haemorrhagic subcutaneous infarction.

Finally, we must mention the fact that we used two different covered stents which were not specifically designed for their use in subclavian and carotid artery, but for renal and pelvic arteries: this shows the importance to expand as much as possible our back up set of materials and to be ready to face complications like the one we reported, especially during this pandemic event.

Conclusions

Interventional radiology and endovascular surgery must be ready and equipped during this period of Coronavirus pandemic: a right management of the patient, the straight and rigid using of DPI's and the possibility to act with as much materials as possible is fundamental to reduce the contagion risk and to obtain good outcomes for the patient.

Acknowledgements

Conflict of interest: The authors have no conflicts of interest to declare. All co-authors have seen and agree with the contents of the manuscript and there is no financial interest to report. We certify that the submission is original work and is not under review at any other publication.

Funds: This report received no specific grant from any funding agency in the public, commercial, or nonprofit sectors.

There are no relevant or minor financial relationships from authors, their relatives or next of kind with external companies.

References

1. A Lamanna, J Maingard, CD Barras, HK Kok, G Handelman, et al. (2019) Carotid artery stenting: Current state of evidence and future directions. *Acta Neurol Scand* 139: 318-333.
2. Chandy PE, Nasir MU, Srinivasan S, Klass D, Nicolaou S, et al. (2020) Interventional radiology and COVID-19: evidence-based measures to limit transmission. *Diagn Interv Radiol* 26: 236-240.
3. CS Ezaru, MP Mangione, TM Oravitz, JW Ibinson, RJ Bjerke (2009) Eliminating Arterial Injury During Central Venous Catheterization Using Manometry. *Anesth Anal* 109: 130-134.
4. LR Golden (1995) Incidence and management of large-bore introducer sheath puncture of the carotid artery. *J Cardiothorac Vasc Anesth* 9: 425-428.
5. Kusminsky RE (2007) Complications of central venous catheterization. *J Am Coll Surg* 204: 681-696.
6. Thachil, J. (2020) The versatile heparin in COVID-19. *J Thromb Haemost* 18: 1020-1022.
7. Li Jianlin, Li Yuesheng, Yang Bin, Wang Hailing, Li Lin (2018) Low-molecular-weight heparin treatment for acute lung injury/acute respiratory distress syndrome: a meta-analysis of randomized controlled trials. *Int J Clin Exp Med* 11: 414-422.
8. Li Taisheng, Lu Hongzhou, Wenhong Zhang (2020) Clinical Observation and Management of COVID-19 Patients. *Emerg Microbes Infect* 9: 687-690.
9. E Terpos, I Ntanasis-Stathopoulos, I Elalamy, E Kastritis, TN Sargentanis, et al. (2020) Hematological Findings and Complications of COVID-19. *Am J Hematol* 95: 834-847.