

Sigmoid volvulus: is it a possible complication after stapled transanal rectal resection (STARR)?

G. RESTA, L. SCAGLIARINI, M. BANDI, L. VEDANA, A. MARZETTI,
G. FERROCCI, M. SANTINI, G. ANANIA, G. CAVALLESCO, M. BACCARINI

SUMMARY: Sigmoid volvulus: is it a possible complication after stapled transanal rectal resection (STARR)?

G. RESTA, L. SCAGLIARINI, M. BANDI, L. VEDANA, A. MARZETTI,
G. FERROCCI, M. SANTINI, G. ANANIA, G. CAVALLESCO,
M. BACCARINI

We report a case of sigmoid volvulus post-stapled transanal rectal

resection (STARR) for obstructed defecation. The patient, a 68-year-old woman with chronic constipation and dolichosigma, two days post-STARR presented severe abdominal pain. CT revealed sigmoid ischemia. The patient underwent resection of the sigmoid colon with end colostomy (Hartmann's procedure). Can STARR procedure produce a serious complication as sigmoid volvulus in patient with dolichosigma and obstructed defecation syndrome?

KEY WORDS: Volvulus - STARR - Sigmoid colon - Dolichosigma.

Introduction

The STARR operation may represent an interesting progress in the surgical management of rectocele and internal mucosal prolapse.

Common complications are rectal bleeding, pelvic and anorectal pain, urgency and fecal incontinence. Uncommon complications are rectal perforation and pelvic sepsis, rectal diverticulum, anorectal stricture and rectovaginal fistula (4).

In this case report we propose sigmoid volvulus as another possible complication of STARR.

Case report

A 68-year-old woman presented with a 1-year history of chronic constipation with evacuation just once a week, obtained only by means of enemas and self endoanal digitations. The patient complained of a sensation of incomplete evacuation with painful effort and unsuccessful attempts. Medical history was positive for appendectomy, hysterioansectomy, bilateral inguinal hernioplasty.

Physical examination revealed rectocele, without genital or urological prolapsed, and rectal mucosal prolaps. Defecography confirmed the diagnosis of rectocele and rectal mucosal prolapse without perineal descent (Fig. 1).

After failure of medical therapy, a STARR procedure was performed. The operation was carried out under general analgesia, with the patient in lithotomy position. On the first postoperative day she has an apparently normal stool evacuation. On the second postoperative day the signs and symptoms were dominated by severe abdominal pain associated with severe hypotension and tachycardia. A voluminous mass was palpated on digital rectal examination which could be consistent with fecaloma that was partially removed. Computed Tomography (CT) demonstrated sigmoid ischemia with moderate free fluid, intestinal pneumatosis and mesenteric stranding and dolichosigm (Figs 2, 3). The patients complete blood count showed 2,420 leukocytes/ml with 1,610 neutrophils/ml; Hb 10.5; PCR 34.6 mg/dl.

A segmental resection of the sigmoid colon with end colostomy (Hartmann's procedure) was performed on the fifth postoperative day because of a voluminous sigmoid volvulus with early signs of intestinal infarction.

The histological assessment of the resected segment confirmed an intestinal infarction.

The patient was discharged without any postoperative complications 10 days later.

Discussion

The STARR operation may represent an interesting progress in the surgical management of rectocele and internal mucosal prolapse.

"S. Anna" University Hospital, Ferrara, Italy
Department of General and Thoracic Surgery

© Copyright 2013, CIC Edizioni Internazionali, Roma

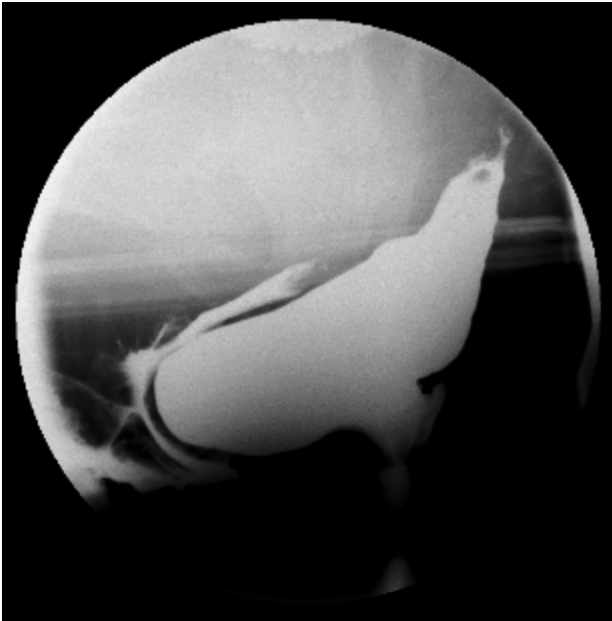


Fig. 1 - Preoperative defecography with anterior rectocele.

Encouraging short-term results have been reported after STARR with good to excellent outcome in 91% of patients (1). Other studies have shown persistence of symptoms in 44% of patients (2) and lack of improvement at mean follow-up of 20 months in 35% of patients (3).

Common complications are rectal bleeding, pelvic and anorectal pain, urgency and fecal incontinence. Uncommon complications are rectal perforation and pel-

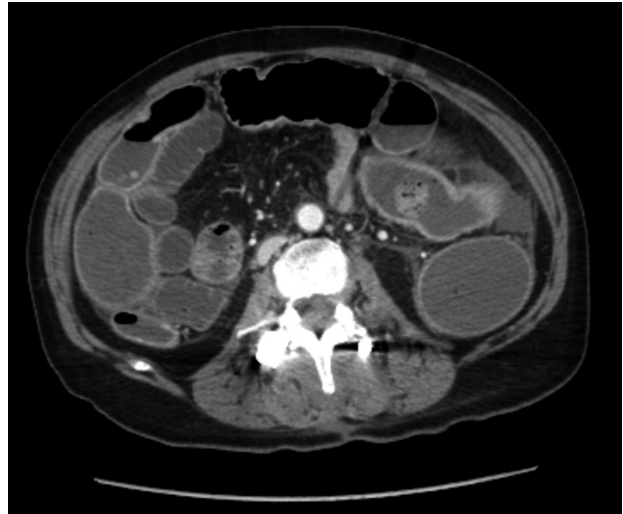

Fig. 3 - Post-STARR abdominal CT: signs of sigmoid ischemia.

vic sepsis, rectal diverticulum, anorectal stricture and rectovaginal fistula (4).

In this case report we propose sigmoid volvulus as another possible complication of STARR.

Sigmoid volvulus is the most common cause of strangulation of the colon and is also the cause for 1% to 7% of all intestinal obstructions in Western countries (5). The main predisposing factor to sigmoid volvulus is a long, redundant sigmoid colon with an elongated mesentery, which is prone to twisting on itself, especially if it is subjected to a contractile persistent stimulus.

Patients undergoing STARR are likely to complain

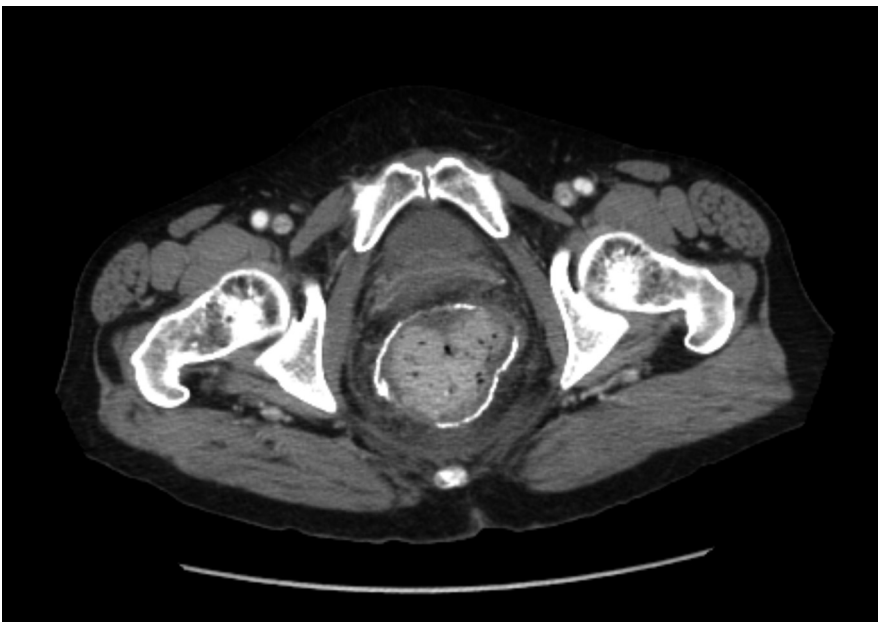


Fig. 2 - Post-STARR abdominal CT: fecaloma in rectal ampulla.

of urgency and frequent defecations, immediately after the procedure, due to a reduced rectal capacity.

Urgency is present in 23% of patients undergoing STARR at a longer follow-up in a large multicentric series (6) due to a significantly decreased maximal tolerable volume (74 instead of 120 ml of air). Also, rectal relaxation related to the fecal mass causes the relaxation of the internal anal sphinctere and the contraction of descending colon in order to activate defecation. So, the combination of postoperative urgency with a fecaloma in rectal ampulla may cause an iper-induction of de-

scending and sigmoid colon contraction. We believe that this combination may cause a sigmoid volvulus in a patient with dolichosigma.

Conclusion

The development of a sigmoid volvulus post-STARR procedure is an unexpected event and surgeons should be aware of such complication because it might be much more frequent than believed.

References

1. Renzi A, Izzo D, Di Sarno G, Izzo G, Di Martino N. Stapled transanal rectal resection to treat obstructed defecation caused by rectal intussusception and rectocele. *Int J Colorectal Dis* 2006;21:661-667.
2. Pechlivanides G, Tsiaoussis J, Athanasakis E, et al. Stapled transanal rectal resection (STARR) to reverse the anatomic disorders of pelvic floor dyssynergia. *World J Surg* 2007;31:1329-1335.
3. Gagliardi G, Pescatori M, Altomare DF, et al. Factors predicting outcome after stapled transanal rectal resection (STARR) procedure for obstructed defecation. *Dis Colon Rectum* 2007;[epub ahead of print] PMID: 18157718.
4. Pescatori M, Gagliardi G. Postoperative complications after procedure for prolapsed hemorrhoids (PPH) and stapled transanal rectal resection (STARR) procedures. *Tech Coloproctol* 2008.
5. Frizelle FA, Wolff BG. Colonic volvulus. *Adv Surg* 1996;29:131-139.
6. Stuto A, Schwander O, Jayne D. Assessing safety of the STARR procedure for ODS: preliminary results of the European STARR Registry. *Dis Colon Rectum* 2007;50:724.