

# Orbital Fractures in Childhood

Luisa Valente, Riccardo Tieghi, Giovanni Elia, Manlio Galiè

Department of Cranio-Maxillofacial Surgery, Unit of Cranio-Maxillofacial Surgery, St. Anna Hospital and University, Ferrara, Italy

## Abstract

Pediatric orbital floor fractures exhibit distinctive features that distinguish them from orbital injuries seen in the adult population. This is mainly due to different anatomy and mechanical properties of the orbital bones in children. The management of pediatric orbital floor fractures requires consideration of these factors, including the age of the patient and therefore child's growth potential, using, if possible, a minimally invasive surgical approach. The aim of this paper is to report a case of a 1-year-old male child with a surgically treated blowout fracture of the orbital floor. To enable early diagnosis and treatment, accurate physical examination is mandatory, but a computed tomographic examination is important, especially in younger patients because of their inability to fully express their symptoms and poor compliance. We discuss the specific presentation and diagnostics of orbital floor fractures in early childhood and the related surgical planning and treatment.

**Keywords:** Blowout fracture, pediatric orbital fracture, trauma

## INTRODUCTION

Pediatric orbital floor fractures carry distinctive features and fracture patterns that distinguish them from orbital injuries seen in the adult population. Therefore, clinical presentation and considerations for diagnosis and treatment differ from adults.

This is mainly due to different anatomy and mechanical properties of the orbital bones in children. In general, the immaturity of the pediatric facial skeleton serves to protect against fracture; there are higher proportions of cancellous bone in children, and the growing sutures retain a cartilaginous structure. This allows pediatric facial bones to absorb more energy during impact without resulting in fracture.<sup>[1]</sup> In very young children, orbital floor fractures are relatively uncommon since most orbital fractures involve the roof.<sup>[1]</sup>

A fracture of orbital floor without fracture of infraorbital rim is referred as pure "blowout fracture."<sup>[2]</sup> This injury is common from frontal blow to orbit causing increased intraorbital tension, with consequent fracture of floor of the orbit with prolapse of orbital content into the maxillary sinus cavity. This causes enophthalmos and diplopia.<sup>[3]</sup>

A well-recognized complication of pediatric orbital floor fractures, due to elasticity of the bones, requiring urgent

surgical repair, is the "trapdoor" fracture,<sup>[4]</sup> where the inferiorly displaced blowout fracture recoils back to its original position and potentially entraps contents of the orbit. Nausea, vomiting, and bradycardia via the oculocardiac reflex, in addition to limitations in ductions, are diagnostic clues to the possibility of extraocular muscles entrapment.<sup>[4]</sup>

Another well-described pediatric phenomenon is the white-eyed blowout fracture, characterized by restriction of upward gaze caused by inferior rectus muscle entrapment within the fracture that occurs with almost no external evidence of trauma.<sup>[4,5]</sup>

Although it has been noted that early pediatric patients tend to present with more trapdoor fractures, open blowout fractures may present too.

There are few reports of open blowout fractures of the orbital floor in children younger than 5 years of age; the authors report a case of a 1-year-old boy with a surgically treated open blowout fracture of the orbital floor.

**Address for correspondence:** Dr. Luisa Valente,  
Unit of Cranio-Maxillofacial Surgery, St. Anna Hospital and University,  
Via Aldo Moro, 8, 44122 Ferrara, Italy.  
E-mail: [luisavalente@outlook.it](mailto:luisavalente@outlook.it)

### Access this article online

#### Quick Response Code:



**Website:**  
[www.amsjournal.com](http://www.amsjournal.com)

**DOI:**  
10.4103/ams.ams\_185\_19

This is an open access journal, and articles are distributed under the terms of the Creative Commons Attribution-NonCommercial-ShareAlike 4.0 License, which allows others to remix, tweak, and build upon the work non-commercially, as long as appropriate credit is given and the new creations are licensed under the identical terms.

**For reprints contact:** [reprints@medknow.com](mailto:reprints@medknow.com)

**How to cite this article:** Valente L, Tieghi R, Elia G, Galiè M. Orbital fractures in childhood. *Ann Maxillofac Surg* 2019;9:403-6.

## CASE REPORT

A 1-year-old male patient presented at the outpatient clinic of Cranio-Maxillo-Facial Surgery Unit of Ferrara with an injury to the left eye occurred after falling from the stairs.

Clinically, the patient was conscious, awake, and reactive. He presented left periorbital edema and ecchymosis, pain on palpation of the left orbital area, and left nostril epistaxis [Figure 1]. Left pupillary reactivity and ocular motility were nonevaluable because of the eyelid swelling. No history of allergy or congenital malformations was noted.

A noncontrast computed tomography (CT) scan of the brain and orbits was performed reporting left orbital floor fracture and left maxillary hem sinus, without prolapse of the inferior rectus muscle [Figure 2].

Ophthalmological evaluation was performed reporting no lesions at fundus oculi, no papilledema or retinal hemorrhages, and no abnormal findings in the vitreous body. Neurosurgical evaluation ruled out associated brain injuries. A thoracic surgeon evaluation excluded chest injuries or pneumothorax.

Routine laboratory investigations were within normal limits.

Surgical correction was planned and performed under general anesthesia. The left orbital floor was approached through a transconjunctival incision. The subperiosteal exposure showed orbital floor fracture displaced in the left maxillary sinus with orbital content herniation [Figure 3]. After retrieving of soft tissues, the orbital floor was reduced and repaired with a polydioxanone sheet (PDS) [Figure 4]. Forced duction test clearly showed no restriction of ocular movements in the left eye. Sutures and dressing completed the operation.

The recovery was uneventful. Postoperative ophthalmological evaluation showed normal ocular movements.

No late complications occurred, and the results were stable at 12-month follow-up [Figure 5].

Considering the good morphological and functional result, a postoperative CT scan was not performed.

## DISCUSSION

Craniofacial development is the result of a complex interaction between intracellular processes, intercellular signaling, and environmental factors. According to the functional matrix hypothesis, the upper face develops secondary to the growth of the brain and eyes; midface growth follows the development of the nasal capsule and teeth.<sup>[6]</sup> The development of orbital volume seems to follow a biphasic pattern. For orbital bone growth, the 1<sup>st</sup> year after birth is often considered to be the critical period. The orbital bones develop most quickly during the first 3 years.<sup>[7]</sup> During the second fast phase, orbital development is closely related to the process of sinus pneumatization.<sup>[8]</sup> The ethmoid sinuses grow gradually to adult size by the age of 12 years.<sup>[7]</sup>

Clinically, when considering timing, indications, and reconstruction options for orbital surgery, it is important to reference these factors, including the age of the patient and therefore child's growth potential. In general, the surgery should be performed as early as possible and preferably using a minimally invasive surgical approach.

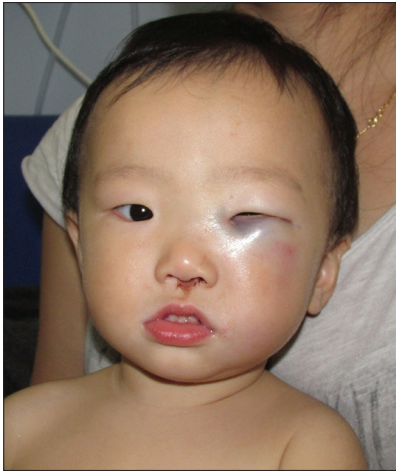Children presenting with minimal or no diplopia and unrestricted extrinsic eye movements, without CT evidence of muscle entrapment, significant fracture, or soft-tissue herniation, no significant enophthalmos, can be managed conservatively,<sup>[9]</sup> with a close follow-up for the next weeks to ensure improvement and detect any developing enophthalmos. General indications for surgery include muscle entrapment evidenced by diplopia within 30° of the primary position or positive forced duction testing, acute enophthalmos >2 mm, or large defects involving more than 50% of the orbital floor or wall. Urgent surgical management (24–48 h) is indicated in patients with trapdoor defect and white-eyed blowout fractures.<sup>[9,10]</sup> Multiple studies indicate that early repair (ideally <48 h) results in improved long-term ocular motility over later intervention.<sup>[11]</sup> Other indications for early surgery intervention include significant hypophthalmos and associated orbital rim or facial fractures.

In our case, there were no clinical signs, besides left periorbital edema and ecchymosis. Because of the young age of the child and the inability to express his symptoms, a complete orthoptic examination to diagnose any eventual diplopia could not be performed. CT examination was diriment for surgery.

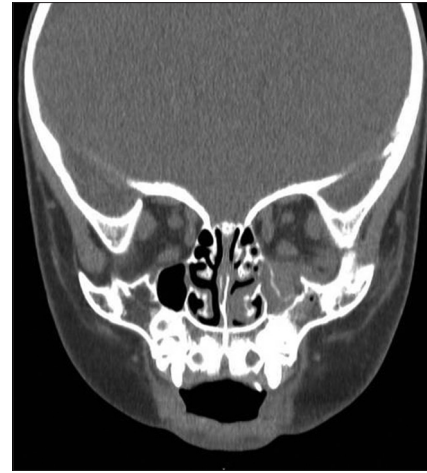
In pediatric patients, a transconjunctival retroseptal incision, with or without lateral canthotomy, is preferred over a cutaneous incision because of its avoidance of external scar. Moreover, the risk of lower-eyelid retraction and ectropion, possible complications after orbital fracture repair, can be minimized with avoidance of the subciliary incision.<sup>[1]</sup>

What kind of material is more suitable in early childhood for orbital floor reconstruction is still an object of debate. A wide variety of implant materials has been described for use in pediatric orbital reconstruction, including autologous bone, resorbable materials, and porous polyethylene sheets. Nonresorbable materials could interfere with the normal growth of the facial bones. Some authors have suggested that thin but strong and resorbable artificial materials would be ideal for orbital floor reconstruction in early childhood (which involves a rapidly growing and changing facial skeleton) and that this could eliminate the need for a second operative site (for the harvesting of an autologous bone graft) and eliminate the risk of complications at the donor site.<sup>[12,13]</sup> In our case, we used a nonthermoplastic flexible PDS trimmed to the size of the bony defect.

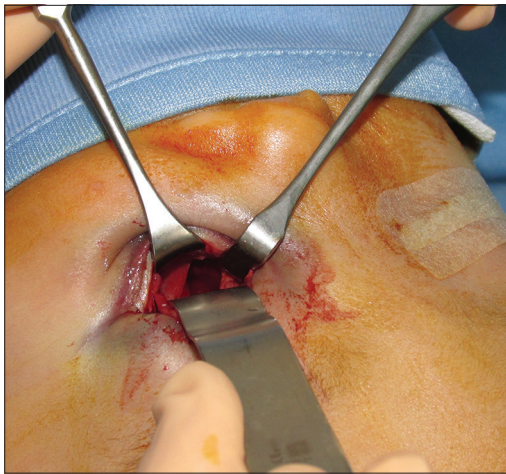
A possible sequela of orbital fractures is enophthalmos, the recession of the ocular globe within the bony orbit. This condition is primarily due to alterations in the configuration of the bony orbit rather than to changes of soft tissue contents.



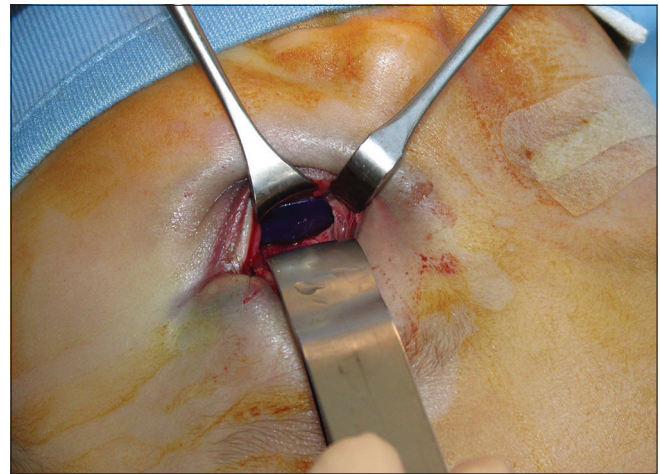
**Figure 1:** Preoperative picture of the patient



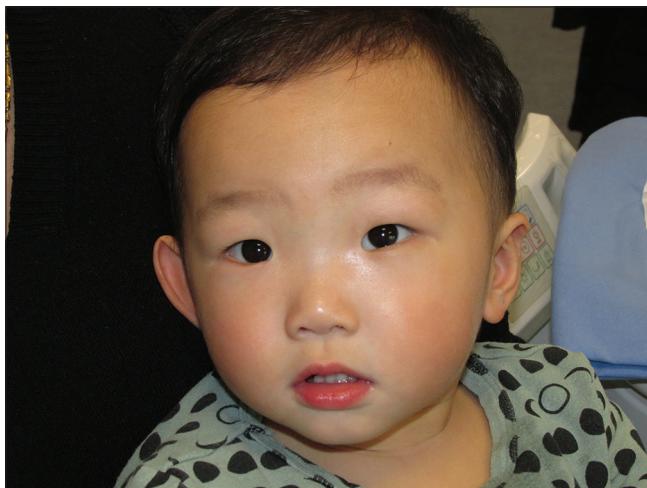**Figure 2:** Preoperative computed tomography scan



**Figure 3:** Intraoperative view of the orbital floor fracture pattern



**Figure 4:** Orbital floor reconstruction with polydioxanone sheet



**Figure 5:** The patient at 12-month follow-up

Since most frequently increased orbital volume results when an implant is incorrectly positioned, the restoration of the pretrauma volume of the internal orbit is the most critical component of orbital reconstruction.<sup>[14,15]</sup> Diplopia is a

common complication of blowout fractures in children and a challenging issue for surgeons. Before and after surgery, an overall ophthalmic examination, including ocular vision, optic nerve function, ocular motility, and forced duction testing, is strongly recommended in younger patients, because of the lack of ability to fully express their symptoms, making diplopia difficult to diagnose. Functional training of the eye muscles should be performed soon after surgery. If necessary, correct training methods should be taught to parents.<sup>[16]</sup>

## CONCLUSIONS

To enable early diagnosis and treatment, accurate physical examination is mandatory, but a CT examination is important, especially in younger patients because of their inability to fully express their symptoms and poor compliance. In our case, by means of early diagnosis and treatment, a good morphological and functional result was achieved.

## Declaration of patient consent

The authors certify that they have obtained all appropriate patient consent forms. In the form the patient(s) has/have

given his/her/their consent for his/her/their images and other clinical information to be reported in the journal. The patients understand that their names and initials will not be published and due efforts will be made to conceal their identity, but anonymity cannot be guaranteed.

### Financial support and sponsorship

Nil.

### Conflicts of interest

There are no conflicts of interest.

## REFERENCES

1. Oppenheimer AJ, Monson LA, Buchman SR. Pediatric orbital fractures. *Craniofac Trauma Reconstr* 2013;6:9-20.
2. Gerber B, Kiwanuka P, Dhariwal D. Orbital fractures in children: A review of outcomes. *Br J Oral Maxillofac Surg* 2013;51:789-93.
3. Thiagarajan B, Ulaganathan V. Blow Out Fracture Orbit Endoscopic Reduction a Novel Management Modality. *WebmedCentral: ENT Scholar* 2012;3:WMC003329.
4. Hink EM, Wei LA, Durairaj VD. Clinical features and treatment of pediatric orbit fractures. *Ophthalmic Plast Reconstr Surg* 2014;30:124-31.
5. Tieghi R, Consorti G, Denes SA, Clauser LC. The white-eyed blow-out fracture: A case report. *Ital J Maxillofac Surg* 2011;47:381-390.
6. Esteve-Altava B, Rasskin-Gutman D. Beyond the functional matrix hypothesis: A network null model of human skull growth for the formation of bone articulations. *J Anat* 2014;225:306-16.
7. Wei N, Bi H, Zhang B, Li X, Sun F, Qian X. Biphasic growth of orbital volume in Chinese children. *Br J Ophthalmol* 2017;101:1162-7.
8. Waitzman AA, Posnick JC, Armstrong DC, Pron GE. Craniofacial skeletal measurements based on computed tomography: Part II. Normal values and growth trends. *Cleft Palate Craniofac J* 1992;29:118-28.
9. Joshi S, Kassira W, Thaller SR. Overview of pediatric orbital fractures. *J Craniofac Surg* 2011;22:1330-2.
10. Clauser L, Galiè M, Pagliaro F, Tieghi R. Posttraumatic enophthalmos: Etiology, principles of reconstruction, and correction. *J Craniofac Surg* 2008;19:351-9.
11. Feldmann ME, Rhodes JL. Pediatric orbital floor fracture. *Eplasty* 2012;12:ic9.
12. Sugamata A, Yoshizawa N. A case of blowout fracture of the orbital floor in early childhood. *Int Med Case Rep J* 2015;8:155-8.
13. Clauser L, Galiè M, Mandrioli S, Sarti E. Severe panfacial fracture with facial explosion: Integrated and multistaged reconstructive procedures. *J Craniofac Surg* 2003;14:893-8.
14. Hazani R, Yaremchuk MJ. Correction of posttraumatic enophthalmos. *Arch Plast Surg* 2012;39:11-7.
15. Koornneef L. Current concepts on the management of orbital blow-out fractures. *Ann Plast Surg* 1982;9:185-200.
16. Su Y, Shen Q, Lin M, Fan X. Diplopia of pediatric orbital blowout fractures: A retrospective study of 83 patients classified by age groups. *Medicine (Baltimore)* 2015;94:e477.