

Editorial Manager(tm) for The Journal of Thoracic and Cardiovascular Surgery
Manuscript Draft

Manuscript Number: JTCVS-05-1404R1

Title: Influence of sternal size and inadvertent paramedian sternotomy on stability of the closure site: A clinical and mechanical study.

Article Type: Original Manuscript

Section/Category: ACD: Acquired Cardiovascular Disease

Keywords:

Corresponding Author: Dr Jacob Zeitani, MD

Corresponding Author's Institution: Tor-Vergata University of Rome,

First Author: Jacob Zeitani, MD

Order of Authors: Jacob Zeitani, MD; Alfonso Penta de Peppo, MD; Marco Moscarelli, MD; Lorenzo Guerrieri Wolf, MD; Antonio Scafuri, MD; Paolo Nardi, MD; Francesca Nanni, PhD; Emanuele Di Marzio, MD; Pasquale De Vico, MD; Luigi Chiariello, MD

Manuscript Region of Origin:

Influence of sternal size and inadvertent paramedian sternotomy on stability of the closure site: A clinical and mechanical study.

J. Zeitani^a, MD, A. Penta de Peppo^b, MD, M. Moscarelli^a, MD, L. Guerrieri Wolf^a, MD, A. Scafuri^a, MD, P. Nardi^a, MD, F. Nanni^c, PhD, E. Di Marzio^d, MD, P. De Vico^d, MD, L. Chiariello^a, MD.

^aDepartment of Cardiac Surgery, ^cDepartment of Clinical Technology, ^dDivision of Anaesthesiology, Tor Vergata University, Rome, Italy and ^bDepartment of Cardiac Surgery, 2nd University of Naples, Italy

Short title: Impact of sternal variables on chest stability

Word count: 3554

Corresponding Author:

Jacob Zeitani, MD

Division of Cardiac Surgery

Tor Vergata University

Via Oxford 85

00133 Rome, Italy

Phone No: +39 06 20903536

Fax: No: + 39 06 20903538

E-mail: zeitani@hotmail.com

Ultramini-abstract

Background: Influence of sternum size and paramedian sternotomy on stability of chest closure is not clear.

Methods: Sternal size, paramedian sternotomy and several risk factors were analysed. An electromechanical test was conducted on sternal models.

Results: Paramedian sternotomy strongly affected stability, as confirmed at electromechanical testing.

Conclusions: Paramedian sternotomy independently affects chest wound stability.

Abstract

Background: The influence of sternum size and of inadvertent paramedian sternotomy on stability of the closure site is not well defined.

Methods: Data of 171 consecutive patients undergoing cardiac surgery through a midline sternotomy were prospectively collected. Intraoperative measurements of sternal dimension included thickness and width at manubrium, the 3rd and 5th intercostal spaces; paramedian sternotomy was defined as width of one side of the sternum $\geq 75\%$ of entire width, at any of the three levels. The chest was closed with simple peristernal steel wires and inspected to detect deep wound infection and/or instability for three postoperative months. The sternal and several patient/surgery related factors were included in a multivariate analysis model to identify factors affecting stability. An electromechanical traction test was conducted on six rewired sternal models after midline or paramedian sternotomy and separation data analysed.

Results: Chest instability was detected in 12 (7%) patients and wound infection in 2 (1.2%). Patient weight ($p=.03$), depressed left ventricular function ($p=.04$), sternum thickness (indexed to body weight, $p=.03$), and paramedian sternotomy ($p=.0001$) were risk factors of postoperative instability; paramedian sternotomy was the only independent predictor ($p=.001$). The electromechanical test showed more lateral displacement of the two rewired sternal halves after paramedian than midline sternotomy ($p=.002$); accordingly, load at fracture point was lower after paramedian sternotomy (220 ± 20 N vs 545 ± 25 N, $p=0.001$).

Conclusions: Inadvertent paramedian sternotomy strongly affects postoperative chest wound stability independently from sternal size, requiring prompt reinforcement of chest closure.

Word count: 248

Midline sternotomy, introduced by Julian in 1957 (1), is the preferred access for operations to the heart and great vessels, allowing good surgical exposure and rapid postoperative wound healing. Nevertheless, wound complications may occur, in particular in patients with concomitant pathologies affecting wound healing, as chronic obstructive pulmonary disease, diabetes, obesity, peripheral arterial disease, or after extensive sternal devascularization due to bilateral internal thoracic artery harvesting (2-8). Deep wound dehiscence and consequent instability of the chest closure undoubtedly represents the most feared complication, facilitating tissue infection and mediastinitis (9-10). Reinforcement of the chest closure, as proposed with different techniques by Robicsek (11) and other Authors (12,13), may prevent postoperative dehiscence in patients at high risk of wound complications; also, titanium plates (14), stainless-steel coils or cables (15,16) have been proposed in substitution of simple steel wires and tested in order to improve postoperative sternum stability. Indeed, routine application of time consuming techniques and/or costly materials depend upon the precise identification of patients who would clearly benefit from reinforcement of the chest closure. Despite the numerous reports on several risk factors of wound complications, the influence of sternal related variables in comparison with the other factors has been poorly investigated. Purpose of this study was to analyse the impact of size of the sternum and inadvertent performance of a paramedian sternotomy on stability of the closure site.

Methods

From June 2004 to November 2004, data of 171 consecutive patients undergoing median sternotomy for coronary artery bypass grafting (n = 99) or valve replacement (n = 72) at our Institution were prospectively collected. Also, a laboratory electromechanical test was conducted on six sternal models to simulate influence of inadvertent paramedian sternotomy on resistance of the rewired sternum to lateral distraction forces.

Pre- and intra-operative characteristics of patients are shown in table 1. Patients undergoing primary reinforcement of the closure site were not included in the study. In coronary patients,

bilateral internal mammary arteries were harvested in a skeletonized fashion. After skin disinfection with 10% Betadine iodine and intravenous antibiotic prophylaxis with 2 grams of Ceftriaxone, sternotomy was performed with an oscillating saw. Sternal measurements were taken at the end of the surgical procedure, before closure of the chest: width and thickness of the two sternal halves were measured with a sterile calibrated ruler at the manubrium, the 3rd and 5th intercostal spaces. Full bone width at the three levels was obtained by addition of measurements of the two halves; the average individual sternal width and thickness was then determined for each patient. Sternal measurements were also indexed to the patient body weight. Paramedian sternotomy was defined as width of one side of the sternum $\geq 75\%$ of the full sternum width, at any of the three measurement levels. Re-approximation of the sternum was then achieved by means of 6-10 (approximately 1 for each 10 Kg of patient weight) single interrupted stainless steel wires, 2-3 through the manubrium and the others in peristernal position at the intercostal spaces. The fascia and the subcutaneous layers were routinely closed with two continuous absorbable 0 polyglycolic acid suture lines and the skin with an intradermic absorbable 4-0 polyglycolic acid suture line. Instability of chest closure was defined as instability of the two rewired halves detected at palpation over the sternum during a brief alternating arm extension exercise; additional deep wound infection was diagnosed, according to the Guidelines for Prevention of Surgical Site Infection of the Hospital Infection Control Practices Committee (17), in case of visual evidence of mediastinitis, isolation of an organism from culture of mediastinal tissue or fluid, fever or instability of the sternum associated with purulent drainage from the mediastinum.

The sternotomy site was inspected monthly for three months after discharge from the hospital. Follow up was 100% complete.

Electromechanical test

The electromechanical test was conducted on six artificial sternal models formed from 20 lbs/ft³ density polyurethane foam (Pacific Research Labs, Inc, Vashon Island, WA), a material which has

been characterized as a model for human cancellous bone (18) and used to construct sternal models, which have been validated for studies of closure methods (19) and are widely adopted in electromechanical studies (14,16). The models were longitudinally divided at the midline ($n = 3$) or at paramedian (75% asymmetrical) line ($n = 3$) with an oscillating saw, rewired by a cardiothoracic surgeon with 5 peristernal number 5 steel wires (AE Medical Corporation Farmingdale, NJ) placed in simple interrupted fashion and then mounted onto an electromechanical testing system (model 8055, Instron Corp, Canton, MA) (Fig 1). In particular, six lateral anchoring holes were made in each side of the sternum, 5 at the costal junctions and one in the manubrium, and lateral distraction forces were applied through pairs of steel cables secured across the holes through small metal hoses. Three strain gauges (Vishay Intertechnology Inc. Malvern, PA) were applied over the closure line on the posterior surface of manubrium, midsternum (at the 3rd intercostal space) and xiphoid, and separation of the two sternal halves was measured with a Spider 8 apparatus in half-bridge configuration (HBM, Marlborough, MA) during a continuously increasing tensile test at 2 mm/min, to generate a load-displacement curve until the construct would break.

Statistical analysis

Influence of variables on stability of the closure site was assessed by the unpaired Student *t* test, the chi-square or Fisher exact test, as appropriate. Sternum related risk factors included sternal width and thickness at the three sternal levels, the mean individual patient width and thickness and occurrence of inadvertent paramedian sternotomy. Other patient and surgery related factors included age, sex, III-IV NYHA functional class, patient weight as a continuous variable and as weight > 80 Kg, obesity (body mass index ≥ 30 Kg/m²), echocardiographic left ventricular ejection fraction lower than 50%, diabetes mellitus, chronic obstructive pulmonary disease, peripheral vascular disease, renal failure (serum creatinine value >1.5 mg/dL), type of surgical procedure (bypass grafting or valve replacement), resident or attending surgeon, bilateral internal thoracic artery harvesting, time of cardiopulmonary bypass, postoperative use of inotropic drugs during the

intensive care stay, reopening for bleeding, transfusion of blood units. Factors with a probability (p) value less than 0.1 were then included in a stepwise logistic regression prediction model.

Separation data of the electromechanical test were compared by two way repeated measurements analysis of variance to detect influence of type of sternotomy and increasing loads on lateral displacement of sternal halves. Ultimate load values at time of fracture of the sternal models were compared by unpaired Student's t test. Variables are presented as mean \pm 1 standard deviation. A p value less than 0.05 was considered statistically significant. Statistical analysis was done by SPSS statistical software package (SPSS Inc, Chicago, IL).

Results

No hospital mortality occurred. Instability of the chest closure was detected in 12 (7%) patients; wound infection was diagnosed in 2 (1.2%) patients. Surgical treatment included chest reopening, debridement of necrotic tissue, rewiring of the sternum according to the Robicsek method (11) in 3 patients or with plain steel wires in 5 patients, or sternal re-approximation by use of bilateral 'pectoralis major' muscle flaps in 4 patients; primary closure of subcutaneous and skin layers was then accomplished by absorbable sutures, as previously reported in patients with superficial wound dehiscence (20), and wide spectrum intravenous antibiotic therapy instituted. All patients experienced complete recovery. At univariate analysis, significant predictors of instability included patient body weight ($p = .03$), body weight > 80 Kg ($p = .03$), preoperative depressed left ventricular function ($p = .04$), the mean individual sternal thickness, indexed to patient's body weight ($p = .03$), and inadvertent paramedian sternotomy ($p = .0001$); no other measurement of sternal size was related to wound instability (table 1 and 2). At multivariate analysis, the paramedian sternotomy was the only risk factor affecting stability of the closure site, independently from the other variables ($p = .001$, odds ratio 11.4, 95% CL 2.5 – 51.7) . All surgeons were right handed: paramedian sternotomy occurred to the right in 11 (69%) and to the left in 5 (31%) patients; correlation of the paramedian incision with the side the internal thoracic artery was

mobilized did not increase the chance of wound instability, which occurred in 2/6 (33%) patients with correlation and in 4/10 (40%) of the other patients. No patient or surgeon related factor influencing occurrence of the off center incision could be identified, including patient sex ($p = .67$), weight ($p = .32$), obesity ($p = .18$), sternal width ($p = .16$) and thickness ($p = .81$), resident or attending surgeon ($p = .27$).

All traction tests were interrupted for transverse fracture of one of the two halves of the rewired sternal models, at the sterno-xiphoid junction in 5 and the lower third in one; break of the construct occurred after steel wires cutting through the casts for a variable extent. Ultimate load values inducing fracture were lower after paramedian sternotomy (220 ± 20 N vs 545 ± 25 N, $p = 0.001$). Lateral displacement at 200 N tensile force (shortly before fracture) after median or paramedian sternotomy was $9,5 \pm 0,4$ vs $11,2 \pm 0,8$ mm at the xiphoid ($p = .016$), $1,5 \pm 0,3$ vs $2,7 \pm 0,4$ mm at midsternum ($p = .008$) and $3,8 \pm 0,6$ vs $4,7 \pm 0,5$ mm at manubrium ($p = .1$). Comparison between mean lateral displacement of sternal halves during traction at increasing loads showed significantly more separation after paramedian than midline sternotomy ($p = .002$) (Fig 2).

Discussion

Midline sternotomy is widely used in open heart surgery, providing prompt access and good surgical exposure at low risk of postoperative wound complications; moreover, sternal closure can be accomplished quickly and efficiently by re-approximation of the two sternal halves with inexpensive simple steel wires. Nevertheless, postoperative sternal instability occurs in some patients, causing deep wound dehiscence and favoring mediastinitis, the most serious wound complication, still producing high morbidity and mortality in up to 2% of patients after cardiac surgery (9-10). Several studies focus on the influence of concomitant pathologies and of surgery related factors on wound healing: advanced cardiac disease, diabetes, peripheral vascular disease, smoking and bilateral internal thoracic artery harvesting are known risk factors (2-8,21). Also, factors increasing forces acting on the sternum, as patient overweight, chronic obstructive

pulmonary disease and prolonged mechanical ventilation, have been frequently related to an increased risk of wound complications (2,3). Accordingly, different techniques and materials have been proposed to enhance stability of sternal closure in high risk patients (11-16). Interestingly, the impact of the anatomic characteristics of the sternum on wound complications has been poorly investigated; also, the precise influence of inadvertent paramedian sternotomy, a technical drawback of longitudinal chest opening, has not been well defined in comparison with other known risk factors of wound complications. We hypothesized that a better knowledge of these aspects might also help to clearly identify those patients who would benefit from routine application of a reinforcement technique of chest closure. Indeed, the various techniques and materials for sternum reinforcement are somewhat time consuming and more expensive than the usual closure with simple wires, and surgeons may hesitate to adopt routinely one of these techniques in all categories of patients at risk.

We found that sternal size did not affect independently chest wound stability; in fact, sternal thickness affected postoperative stability if indexed to the patient body weight, which is a well known risk factor of wound complications. That finding is presumably related to the great variability of sternal width and thickness which is normal between patients. We found, instead, that inadvertent performance of paramedian sternotomy strongly affected postoperative stability at the closure site, as also suggested previously (22). As expected, other known risk factors of deep wound dehiscence were identified, as patient weight and depressed left ventricular function. Interestingly, at multivariate comparisons, paramedian sternotomy was the most powerful risk factor of postoperative chest instability, suggesting that this technical drawback might be as or more important than other already well known risk factors; of note, that influence occurred independently from sternal size and the other analysed variables. That finding was enhanced by the observations at the electromechanical test on the rewired sternal models, showing more separation of the two sternal halves during lateral traction and a consistently lower ultimate load inducing the model

break after paramedian than midline sternotomy. As already shown in previous reports (14-16), the higher lateral displacement was detected at the xiphoid.

These findings have practical implications on the intra-operative choice of the method of chest closure; indeed, occurrence of inadvertent paramedian sternotomy is easily identified by inspection at time of chest opening and may therefore promptly suggest reinforcement of chest closure by using one of the proposed methods. Imperfect sternal opening may not simply depend on surgical skill and experience; for instance, we found the same impact of resident versus attending surgeons on the occurrence of sternal instability, as already reported by others (23). Also, precise sawing at the midline may easily be compromised if the outer sternal border is hardly detectable, as in overweight patients, or when the bone is narrow; nonetheless, patients significantly at risk for a paramedian incision could not be identified in the present study.

In conclusion, occurrence of inadvertent paramedian sternotomy, independently from sternal size or other factors, appears highly significant among factors jeopardizing a successful chest closure and may promptly induce surgeons to routine application of a sternal reinforcement technique.

References

1. Julian OC, Lopez-Belio M, Dye WS, Javid H, Grove WJ. The median sternal incision in intracardiac surgery with extracorporeal circulation: a general evolution of its use in heart surgery. *Surgery*. 1957;42:753-61.
2. The Parisian Mediastinitis Study Group. Risk factors for deep sternal wound infection after sternotomy: a prospective multicenter study. *J Thorac Cardiovasc Surg*. 1996;111:1200-7.
3. Ridderstolpe L, Gill H, Granfeldt H, Ahlfeldt H, Rutberg H. Superficial and deep sternal wound complications: incidence, risk factors and mortality. *Eur J Cardiothorac Surg*. 2001;20:1168-75.
4. Loop FD, Lytle BW, Cosgrove DM, Mahfood S, McHenry MC, Goormastic M, et al. Sternal wound complications after isolated coronary artery bypass grafting: early and late mortality, morbidity, and cost of care. *Ann Thorac Surg*. 1990;49:179-87.
5. Kouchoukos NT, Wareing TH, Murphy SF, Pelate C, Marshall WG. Risks of bilateral internal mammary artery bypass grafting. *Ann Thorac Surg*. 1990;49:210-9.
6. Jonkers D, Elenbaas T, Terporten P, Nieman F, Stobberingh E. Prevalence of 90-days postoperative wound infections after cardiac surgery. *Eur J Cardiothorac Surg*. 2003;23(1):97-102.
7. De Paulis R, de Notaris S, Scaffa R, Nardella S, Zeitani J, Del Giudice C, et al. The effect of bilateral internal thoracic artery harvesting on superficial and deep sternal infection: The role of skeletonization. *J Thorac Cardiovasc Surg*. 2005;129:536-43.
8. Seyfer AE, Shriver CD, Miller GM, Graeber GM. Sternal blood flow after median sternotomy and mobilization of the internal mammary arteries. *Surgery*. 1988;104:899-904.
9. El Oakley RM, Wright JE. Postoperative mediastinitis: classification and management. *Ann Thorac Surg*. 1996;61:1030-6.
10. Bitkover CY, Gardlund B. Mediastinitis after cardiovascular operations: a case-control study of risk factors. *Ann Thorac Surg*. 1998;65:36-40.
11. Robicsek F, Daugherty HK, Cook JW. The prevention and treatment of sternum separation following open heart surgery. *J Thorac Cardiovasc Surg*. 1977;73:267-8.

12. Chlosta WF, Elefteriades JA. Simplified method of reinforced sternal closure. *Ann Thorac Surg.* 1995;60(5):1428-9.
13. Al Ebrahim K. Reinforced sternal closure: the bilateral straight longitudinal wire technique. *Asian Cardiovasc Thorac Ann.* 2003;11(1):90-1.
14. Pai S, Gunja NJ, Dupak EL, McMahon NL, Roth TR, Lalikos JF, et al. In vitro comparison of wire and plate fixation for midline sternotomies. *Ann Thorac Surg.* 2005;80:962-8.
15. McGregor WE, Payne M, Trimble DR, Farkas KM, Magovern JA. Improvement of sternal closure stability with reinforced steel wires. *Ann Thorac Surg.* 2003;76:1631-4.
16. Cohen DJ, Griffin LV. A biomedical comparison of three sternotomy closure techniques. *Ann Thorac Surg.* 2002;73:563-8.
17. Mangram AJ, Horan TC, Pearson ML, Silver LC, Jarvis WR. Guideline for prevention of surgical site infection, 1999. Hospital Infection Control Practices Advisory Committee. *Infect Control Hosp Epidemiol.* 1999;20:250-78.
18. Szivek JA, Thomas M, Benjamin JB. Characterization of a synthetic foam as a model for human cancellous bone. *J Appl Biomater* 1993;4:269-72.
19. Trumble DR, McGregor WE, Magovern JA. Validation of a bone analog model for studies of sternal closure. *Ann Thorac Surg* 2002;74:739-44.
20. Zeitani J, Bertoldo F, Bassano C, Penta de Peppo A, Pellegrino A, El Fakhri FM, et al. Superficial wound dehiscence after median sternotomy: surgical treatment versus secondary wound healing. *Ann Thorac Surg.* 2004;77:672-5.
21. Peivandi AA, Kasper-Konig W, Quinkenstein E, Loos AH, Dahm M. Risk factors influencing the outcome after surgical treatment of complicated deep sternal wound complications. *Cardiovasc Surg.* 2003 Jun;11(3):207-12.
22. Shafir R, Weiss J, Herman O, Cohen N, Stern D, Igra Y. Faulty sternotomy and complications after median sternotomy. *J Thorac Cardiovasc Surg.* 1988;96:310-3.

23. Breyer RH, Mills SA, Hudspeth AS, Johnston FR, Cordell AR. A prospective study of sternal wound complications. *Ann Thorac Surg.*1984;37(5):412-6.

Table 1. Clinical characteristics of patients with and without postoperative instability of the chest closure site

Variables	Instability (n=12)	Stability (n=159)	P value
Age (y)	68.3 ± 6.1	66.5 ± 10.2	.58
Age >70 years	7 (58%)	65 (41%)	.23
Sex (M/F)	7/5	108/51	.49
Diabetes mellitus	4 (33%)	44 (28%)	.67
COPD	4 (33%)	45 (28%)	.71
Renal dysfunction	1 (8%)	23 (14%)	.55
LVEF <50%	5 (42%)	28 (18%)	.04
Weight (Kg)	82.4 ± 10.5	73.8 ± 13.3	.03
Weight >80 Kg	7 (58%)	45 (28%)	.03
Obesity*	5 (42%)	36 (23%)	.13
CABG procedure	8 (67%)	91 (57%)	.52
BITA use	4 (33%)	43 (27%)	.63
CP bypass time (min)	89 ± 25	77 ± 28	.20
Use of inotropic drugs	6 (50%)	44 (28%)	.10
Transfusion of blood units	8 (67%)	101 (63%)	.82

COPD, chronic obstructive pulmonary disease; *LVEF*, left ventricular ejection fraction; *CABG*, coronary artery bypass grafting; *BITA*, bilateral internal thoracic artery; *CP*, cardiopulmonary.

*Obesity is defined as body mass index (weight/height²) > 30.0

Table 2. Sternum related variables in patients with and without postoperative instability of the chest closure site

Variable	Instability (n=12)	Stability (n=159)	P value
Sternum width, mean (mm)	36.1 ± 6.5	32.9 ± 5.8	.09
Sternum width / body weight (mm/Kg)	0.43 ± 0.07	0.46 ± 0.11	.49
Sternum thickness, mean (mm)	10.8 ± 1.4	11.2 ± 2.2	.48
Sternum thickness / body weight (mm/Kg)	0.13 ± 0.03	0.16 ± 0.03	.03
Paramedian sternotomy	6 (50%)	10 (6.2%)	.0001

Figure Legends

Figure 1. Photograph of the electromechanical testing system providing lateral distraction forces to the anchoring points on the rewired polyurethane sternal model.

Figure 2. Separation data of the rewired sternal models after midline ($n = 3$) or paramedian ($n = 3$) sternotomy, up to forces causing fracture. *Displacement differs significantly from other group ($p = 0.02$). Fracture occurred earlier in models divided by paramedian sternotomy (220 ± 20 N vs 545 ± 25 N, $p = .001$).

Table 1. Clinical characteristics of patients with and without postoperative instability of the chest closure site

Variables	Instability (n=12)	Stability (n=159)	P value
Age (y)	68.3 ± 6.1	66.5 ± 10.2	.58
Age >70 years	7 (58%)	65 (41%)	.23
Sex (M/F)	7/5	108/51	.49
Diabetes mellitus	4 (33%)	44 (28%)	.67
COPD	4 (33%)	45 (28%)	.71
Renal dysfunction	1 (8%)	23 (14%)	.55
LVEF <50%	5 (42%)	28 (18%)	.04
Weight (Kg)	82.4 ± 10.5	73.8 ± 13.3	.03
Weight >80 Kg	7 (58%)	45 (28%)	.03
Obesity*	5 (42%)	36 (23%)	.13
CABG procedure	8 (67%)	91 (57%)	.52
BITA use	4 (33%)	43 (27%)	.63
CP bypass time (min)	89 ± 25	77 ± 28	.20
Use of inotropic drugs	6 (50%)	44 (28%)	.10
Transfusion of blood units	8 (67%)	101 (63%)	.82

COPD, chronic obstructive pulmonary disease; *LVEF*, left ventricular ejection fraction; *CABG*, coronary artery bypass grafting; *BITA*, bilateral internal thoracic artery; *CP*, cardiopulmonary.

*Obesity is defined as body mass index (weight/height²) > 30.0

Table 2. Sternum related variables in patients with and without postoperative instability of the chest closure site

Variable	Instability (n=12)	Stability (n=159)	P value
Sternum width, mean (mm)	36.1 ± 6.5	32.9 ± 5.8	.09
Sternum width / body weight (mm/Kg)	0.43 ± 0.07	0.46 ± 0.11	.49
Sternum thickness, mean (mm)	10.8 ± 1.4	11.2 ± 2.2	.48
Sternum thickness / body weight (mm/Kg)	0.13 ± 0.03	0.16 ± 0.03	.03
Paramedian sternotomy	6 (50%)	10 (6.2%)	.0001

Figure 1
[Click here to download high resolution image](#)


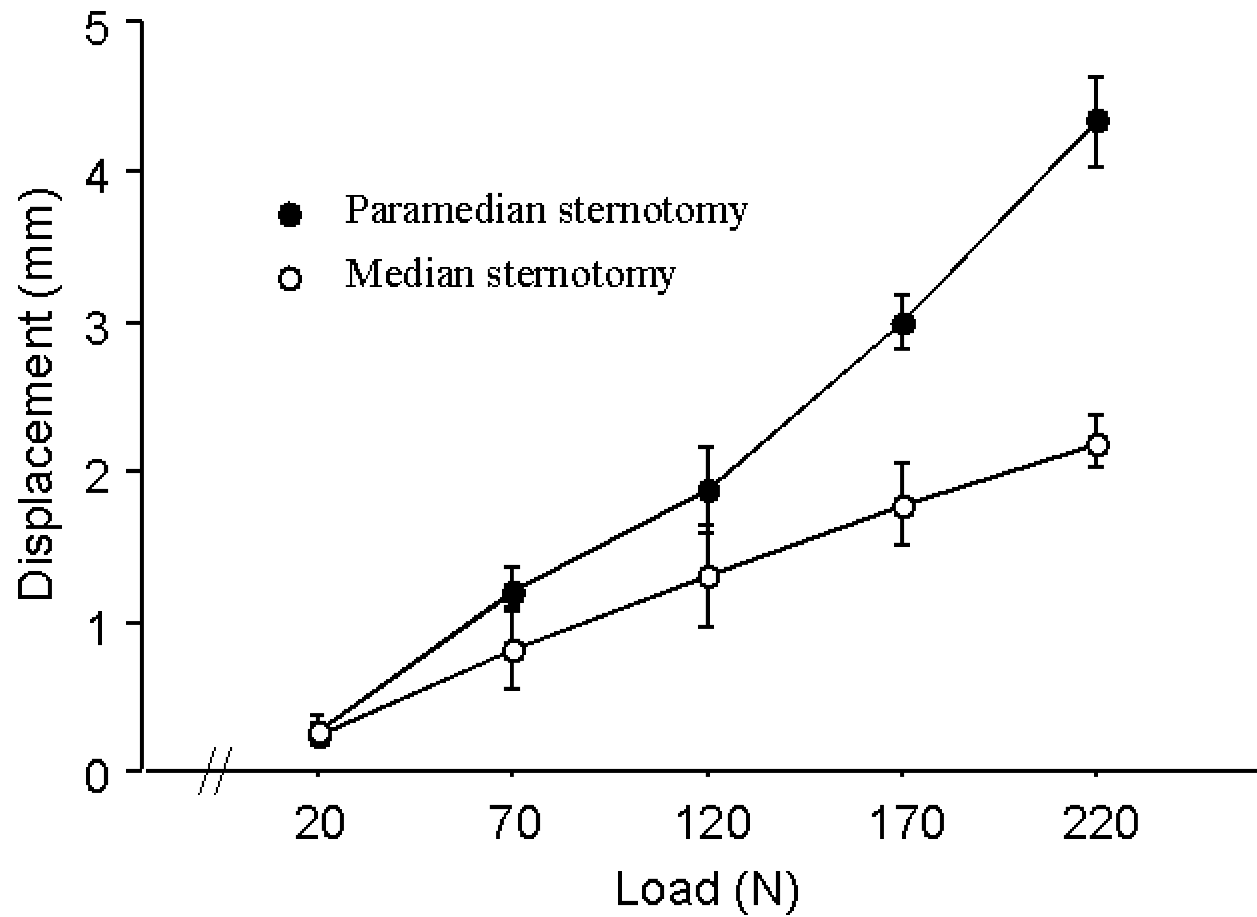


Figure 2

[Click here to download high resolution image](#)



Your MS Word document "disclosure statments.doc" cannot be opened and processed. Please see the common list of problems, and suggested resolutions below.

Common Problems When Creating a PDF from Microsoft Word Documents

When you open your document in MS Word, an alert box may appear with a message. This message may relate to margins or document size. You will need to find the piece of your Word document that is causing the problem. Selectively remove various pieces of the file, saving the modified file with a temporary file name. Then try to open modified file. Repeat this process until the alert box no longer appears when you open the document.

Embedded Macros

Your submission should not contain macros. If they do, an alert box may appear when you open your document (this alert box prevents EM from automatically converting your Word document into the PDF that Editors and Reviewers will use). You must adjust your Word document to remove these macros.

Corrupted Tables

Your document may contain a table that cannot be rendered correctly. This will be indicated by a warning alert box. Correct the content of the table that causes the problem, so that the alert box no longer appears.

Word 2002/Word XP files

At the present time, EM supports Word files in Word 2000 and earlier formats. If you are using a more recent version of MS Word, try saving your Word document in a format compatible with Word 2000, and resubmit to EM.

Other Problems

If you are able to get your Word document to open with no alert boxes appearing, and you have submitted it in Word 2000 (or earlier) format, and you still see an error indication in your PDF file (where your Word document should be appearing). please contact the journal via the 'Contact Us' button on the Navigation Bar.'

You will need to reformat your Word document, and then re-submit it.

Photo of author(s)

[Click here to download high resolution image](#)

