

Case Report

Cochlear Implant Electrode Migration due to Cholesterol Granuloma: Cues from a Case

Andrea Di Laora, Isabelle Mosnier, Andrea Ciorba , Stefano Pelucchi, Olivier Sterkers, Daniele Bernardeschi

Department of Otology, Auditory Implants and Skull Base, Pitié Salpêtrière Hospital, Paris, France (ADL, IM, OS, DB)
ENT and Audiology Clinic, University Hospital of Ferrara, Ferrara, Italy (ADL, AC, SP)

ORCID IDs of the authors: A.C. 0000-0003-3455-2295.

Cite this article as: Di Laora A, Mosnier I, Ciorba A, Pelucchi S, Sterkers O, Bernardeschi D. Cochlear Implant Electrode Migration due to Cholesterol Granuloma: Cues from a Case. J Int Adv Otol 2019; 10.5152/iao.2019.6072.

This paper aims to describe a rare case of cochlear implant (CI) failure due to electrode array migration and review the literature on the topic. A 72-year-old woman complained of retroauricular pain two years after receiving a left CI, with deterioration of the auditory skills and an increased impedance of electrodes. Temporal bone computed tomographic scans revealed a soft density tissue involving the left mastoid and the middle ear. It also revealed a lateral displacement of the array into the middle ear. Surgery with CI re-implantation was performed. The specimen examination disclosed the presence of a cholesterol granuloma. According to the literature, array migration after CI due to cholesterol granuloma is very rare. When patient's auditory performances decline and electrodes impedance increases, computed tomography (CT) scans should be performed to detect possible electrode issues, as in this case. Middle ear and mastoid cholesterol granuloma represent a possible, rare, cause of electrode array migration, even in absence of cochlear erosions.

KEYWORDS: Cholesterol granuloma, cochlear implant, array migration

INTRODUCTION

Nowadays, cochlear implants (CIs) can be considered a safe treatment for severe to profound sensorineural hearing loss, both in children and adults. Nonetheless, despite the worldwide recognized safety of these devices, a re-implantation procedure can occur for many reasons, such as wound infection, CI failure, trauma, skin flap necrosis, and electrode array dysfunction^[1,2]. Electrode array failures, such as misplacement, migration, or extrusion, occur very rarely: 0.7% of all complications after CI surgery^[3].

This paper aims to present a case of partial migration of the electrode array to the middle ear due to a cholesterol granuloma (CG), and also review the literature on the topic.

CASE PRESENTATION

A 72-year-old woman was referred to the University ENT Department in January 2017, due to left CI dysfunction since few months including the perception of noise and echo sounds on the left ear.

The patient was affected by a bilateral otosclerosis. She developed a left severe-profound sensorineural hearing loss in 1968 due to a stapedectomy. Unfortunately, she also developed a severe sensorineural hearing loss, progressively, in the untreated ear.

She was wearing a hearing aid in the right ear since 1970. In 2007, she underwent a left cochlear implantation, with a cochlear device (CI 24RE Freedom, Cochlear, Sydney, Australia), since the presence of a severe hearing loss in her right hear. Surgical procedure was uneventful; three weeks after surgery, the device was regularly activated; and three months later, she reported a successful comprehension of daily sentences without lip reading.

In 2012, she was affected by left recurrent otorrhea episodes, which were firstly treated by local antibiotic treatment. Microotoscopy disclosed an attic cholesteatoma with a posterior mesotympanic retraction pocket. Temporal bone computed tomography (CT)

Corresponding Address: Andrea Ciorba E-mail: andrea.ciorba@unife.it

Submitted: 20.09.2018 • **Revision Received:** 14.01.2019 • **Accepted:** 25.01.2019 • **Available Online Date:** 24.07.2019
Available online at www.advancedotology.org



Content of this journal is licensed under a
Creative Commons Attribution-NonCommercial
4.0 International License.

scans showed a left cholesteatoma involving the electrodes array. She underwent a subtotal petrosectomy with middle ear exclusion, and a new CI (CI 24RE Freedom, Cochlear, Sydney, Australia) was re-implanted. Auditory performances remained stable until January 2017, when she reported the perception of noise and echo sounds in the left ear, which did not resolve after processor replacement. She progressively developed a tiny bulging in correspondence of the pre-existing retroauricular scar. No inflammatory signs were present on the outer skin. Vocal threshold showed no intelligibility with CI. Electrically evoked compound action potential presented no responses at the basal electrodes. Temporal bone CT scan showed partial extrusion of the electrodes array from the cochlea and a normal antrum and mastoid obliteration (Figure 1). The revision petrosectomy disclosed a CG involving the left mastoid and the middle ear. It also revealed a lateral displacement of the array into the middle ear. The lesion was removed, and it was then sent for microbiological and histological exams. A new CI (CI 512, Cochlear, Sydney, Australia) was placed, and the mastoid was obliterated with abdominal adipose tissue.

Final histological exam was CG. There was no microbial growth at the cultural exam; in particular, polymerase chain reaction and histochemical stains for mycobacteria were also negative. Postoperative CT scan demonstrated a correctly positioned implant cochlear in left cochlea, without complications.

A year after surgery, there was no evidence of recurrence at a temporal bone CT scan, and CI parameters were absolutely normal (follow-up was planned by checking CI function—i.e., electrodes impedance—and performing a temporal bone CT scan, every year for the first three years, and then every five years).

The patient gave her consent for publication of the data.

DISCUSSION

Following a successful cochlear implantation, device failures, including electrode array, can occur. We present a rare case of electrode array migration as consequence of a CG treated by device removal. A possible classification of electrode array extrusion causes has been

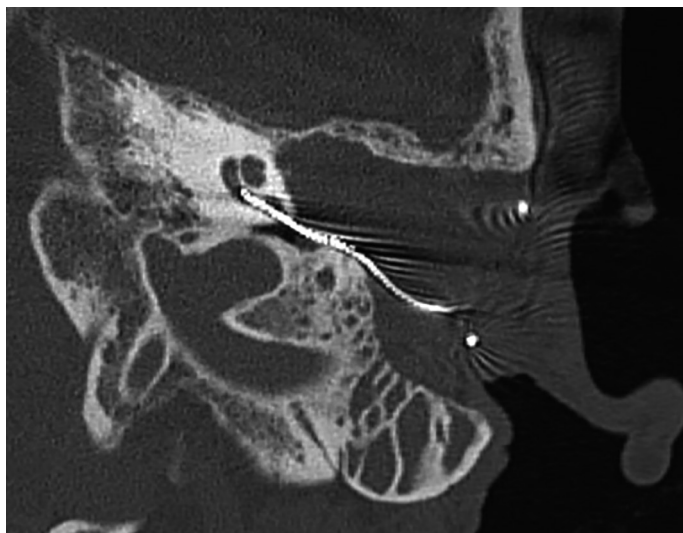


Figure 1. Temporal bone CT scan, axial section, showed a partial extrusion of the electrodes array from the cochlea.

reported in Table 1. Currently, the mechanisms of electrode migration are poorly understood and less studied; it is reported to occur more frequently in children due to intracochlear fibrosis, mastoid growth, or head trauma ^[4].

Cholesterol granuloma has been described as an expansive, intraosseous cyst containing cholesterol crystals surrounded by foreign body giant cells and chronic inflammation, covered by a thick fibrous capsule. The cyst has no true epithelial lining, so a complete surgical excision is not required ^[5]. CG usually involves the petrous apex; however, tympanomastoid CG has also been described ^[6,7]. The latter is typically observed after middle ear surgery (so-called blue domed cyst sometimes observed in a canal wall down procedure) ^[6]. It can develop up to 10 years after surgery ^[7]. Traditionally, it has been reported that CG can occur due to the “obstruction-vacuum theory”; cholesterol crystals are released from an anaerobic catabolism of blood vessels. These enter the pneumatic air cell system of temporal bone because of a negative pressure. Negative pressure, generated by gas absorption, arises because of an obstruction to the passage of air through the air cell system due to a Eustachian tube dysfunction or mucosal edema ^[8]. However, Jackler et al. ^[9] proposed a new hypothesis for the CG pathogenesis, which they called “the exposed marrow theory.” They suggested that CG can originate from the bone marrow of the clivus. They noticed at a radiologic investigation that in six out of 13 patients with CG, there was a contralateral dehiscence of the bony partition between the petrous apex air cell system and bone marrow of the clivus. Control patients with a highly pneumatized petrous apex but without CG had not such dehiscence.

Few cases of electrode extrusion due to CG have been reported in the literature. Neilan et al. ^[10] described a case of CI device failure secondary to a CG. However, in this case, electrode displacement in the middle ear space was secondary to a large erosion of the cochlea mediated by CG ^[10]. Nadol et al. ^[11] noticed that CGs can cause extensive osteitis and widespread erosion of the temporal bone, and they can acquire the characteristics of a locally destructive process. The authors presented a case of necrotizing granuloma, after cochlear implantation in a 71-year-old man, developing along the electrode

Table 1. Proposed classification of electrode extrusion causes

- | |
|---|
| 1) Intracochlear factors: may push the electrode array out of the cochlea |
| a. Fibrosis |
| b. Ossification |
| c. Cochlear malformations |
| 2) Extracochlear factors: may pull the electrode array out of the cochlea |
| a. Scar formation and fibrosis at the round window |
| b. middle ear, mastoid adhesions |
| c. cholesteatoma |
| d. cholesterol granuloma |
| 3) Skull growth (children) |
| 4) Extrinsic causes: |
| a. Trauma |
| b. Infections |

through the mastoid into the cochlea. This led to osteolysis of the otic capsule, with presumed migration of the electrode array from the basal turn into the carotid canal ^[11]. In both the reports, the CT scans were crucial to identify the problem, as in the presented case.

CONCLUSION

Electrode migration is a rare delayed complication of CI, which can occur in both children and adults. CG represents another potential cause for a CI failure. In presence of auditory performances deterioration and an increased impedance of electrodes, a CT scan should be always performed to rule out possible electrode misplacement. Middle ear and mastoid CG represent a potential cause of electrode array migration, even without cochlear erosions.

Informed Consent: Written informed consent was obtained from the patient who participated in this study.

Peer-review: Externally peer-reviewed.

Author Contributions: Concept – B.D., S.O., M.I.; Design - S.O., M.I., P.S.; Supervision - S.O., M.I., P.S.; Resource - B.D., M.I., B.D.; Materials - D.A., M.I., C.A., P.S., S.O., B.D.; Data Collection and/or Processing - D.A., C.A., B.D.; Analysis and/or Interpretation - C.A., D.A., B.D.; Literature Search - C.A., D.A.; Writing - C.A., D.A.; Critical Reviews - D.A., M.I., C.A., P.S., S.O., B.D.

Conflict of Interest: The authors have no conflict of interest to declare.

Financial Disclosure: The authors declared that this study has received no financial support.

REFERENCES

1. Postelmans JT, Cleffken B, Stokroos RJ. Post-operative complications of cochlear implantation in adults and children: five years' experience in Maastricht. *J Laryngol Otol* 2007; 121: 318-23. [\[CrossRef\]](#)
2. Patnaik U, Sikka K, Agarwal S, Kumar R, Thakar A, Sharma SC. Cochlear re-implantation: lessons learnt and the way ahead. *Acta Otolaryngol* 2016; 136: 564-7. [\[CrossRef\]](#)
3. Terry B, Kelt RE, Jeyakumar A. Delayed Complications After Cochlear Implantation. *JAMA Otolaryngol Head Neck Surg* 2015; 141: 1012-7. [\[CrossRef\]](#)
4. Diets A, Wennestrom M, Lehtimaki A, Lopponen H, Valtonen H. Electrode migration after cochlear implant surgery: more common than expected? *Eur Arch Otorhinolaryngol* 2016; 73: 1411-8. [\[CrossRef\]](#)
5. Isaacson B, Kutz JW, Roland PS. Lesions of the Petrous Apex: Diagnosis and Management. *Otolaryngol Clin N Am* 2007; 40: 479-519. [\[CrossRef\]](#)
6. Hamilton ST, Gadre SA, Gadre AK. Cholesterol granuloma and recurrent cholesteatoma after canal-wall-down mastoidectomy. *Ear Nose Throat J* 2010; 89: 298-300.
7. Meyer DR, Bui HX, Carlson AJ, Ratliff CD, Guevarra MC, Del Rosario AD, et al. Silicone granulomas and dermatomyositis-like changes associated with chronic eyelid edema after silicone breast implant. *Ophthalmic Plast Reconstr Surg* 1988; 14: 182-8. [\[CrossRef\]](#)
8. Nager GT, Vanderveen TS. Cholesterol granuloma involving the temporal bone. *Ann Otol Rhinol Laryngol* 1976; 85: 204-9. [\[CrossRef\]](#)
9. Jackler RK, Cho M. A New Theory to Explain the Genesis of Petrous Apex Cholesterol Granuloma. *Otol Neurotol* 2003; 24: 96-106. [\[CrossRef\]](#)
10. Neilan RE, Pawlowski K, Isaacson B, Roland PS. Cochlear Implant Device Failure Secondary to Cholesterol Granuloma Mediated Cochlear Erosion. *Otol Neurotol* 2012; 33: 733-5. [\[CrossRef\]](#)
11. Nadol JB, Eddington DK, Burgess BJ. Foreign Body or Hypersensitivity Granuloma of the Inner Ear following Cochlear Implantation. One possible cause of a soft failure? *Otol Neurotol* 2008; 29: 1076-84. [\[CrossRef\]](#)