

Bubble technique for Descemet membrane endothelial keratoplasty tissue preparation in an eye bank: air or liquid?

Alessandro Ruzza,¹ Mohit Parekh,¹ Gianni Salvalaio,¹ Stefano Ferrari,¹ Davide Camposampiero,¹ Marie-Claude Amoureux,^{2,3} Massimo Busin⁴ and Diego Ponzin¹

¹International Center for Ocular Physiopathology (ICOP), The Veneto Eye Bank Foundation, Zelarino, Venice, Italy

²Institute of Neurosciences de la Timone, UMR 7289, CNRS-AMU, Marseille, France

³Eurobio, Les Ulis, Courtaboeuf Cedex B, France

⁴Department of Ophthalmology, Villa Igea, Forlì, Italy

ABSTRACT.

Purpose: To compare the big-bubble method using air and liquid as medium of separation for Descemet membrane endothelial keratoplasty (DMEK) lenticule preparation in an eye bank.

Methods: Donor corneas ($n = 20$) were immersed in liquid [tissue culture medium (TCM)]. Air and liquid was injected using a 25-gauge needle in the posterior stroma or as near to the stroma–Descemet membrane (DM) phase as possible to create a complete bubble of larger diameter. The endothelial cell density and mortality were checked pre- and postbubble after deflating the tissue. Four pairs of tissues were used to analyse the intracellular tight junctions and three pairs for histological examination and DNA integrity studies, respectively.

Results: The yield obtained using air was 80%, whereas that with liquid was 100%. Single injection was required in six cases; twice in two cases; three and four times in one case each with air bubble, whereas seven cases required single injection; twice in two cases; and thrice in just one case with liquid bubble. The average diameter of the final lenticule was $9.12 (\pm 1.71)$ mm for air bubble and $9.78 (\pm 1.75)$ mm for liquid bubble with $p = 0.4362$ (no statistical significance). Endothelial cell mortality postbubble preparation was $8.9 (\pm 12.38)$ % for air and $6.25 (\pm 9.57)$ % for liquid ($p = 0.6268$).

Conclusions: DM and endothelium could be separated exclusively using air or liquid bubble. However, liquid bubble seems to have certain advantages over air such as the generation of yield, larger diameter and higher maintenance of endothelial cell density and integrity.

Key words: big bubble – DMEK – eye bank

Acta Ophthalmol. 2015; 93: e129–e134

© 2014 Acta Ophthalmologica Scandinavica Foundation. Published by John Wiley & Sons Ltd

doi: 10.1111/aos.12520

Introduction

In the recent years, endothelial keratoplasty (EK) has become a popular surgical practice to treat the endothelial dysfunctions of the cornea. EK

replaces the diseased stroma (in some cases), Descemet membrane (DM) and endothelium of the patient, with a healthy donor tissue. Currently, there are various methods that are used for EK such as Descemet stripping

automated endothelial keratoplasty (DSAEK), ultra thin (UT) DSAEK and Descemet membrane endothelial keratoplasty (DMEK). DSAEK and UT DSAEK involve medium to small stromal layer, respectively, whereas with DMEK, it is the DM and the endothelium, usually without any stromal layer, that is transplanted. With increase in EK popularity, DSAEK is considered as the most common technique due to its advantages that include ease of tissue harvest and manipulation along with a more standardized transplant. For DMEK tissues, the big-bubble technique which is primarily used for deep anterior lamellar keratoplasty (DALK) (Anwar & Teichmann 2002) may now be used to separate the Descemet endothelial graft (DEG). DMEK is, however, emerging in terms of graft survival, generation of larger diameter lenticules, reduced damage to corneal interface, less expenses due to minimal requirements of the surgical instruments and early rehabilitation rate (Dapena et al. 2009; Ham et al. 2009a,b).

There are various methods that are described in the literature, which explain mechanical dissection and harvest of a DMEK lenticule from the donor corneal tissue (Melles et al. 2004; Ignacio et al. 2005; Zhu et al. 2006; Lie et al. 2008; Busin et al. 2010; Studeny et al. 2010; Zarei-Ghanavati et al. 2010; Dua & Said 2011; Groeneveld-van Beek et al. 2013; Muraine

et al. 2013). However, all the studies either show how to prepare a lenticule by stripping, scraping or separating the stroma and DM using an air bubble or hydro-dissection. Air bubble was primarily intended for DALK for excising the anterior cornea with stroma, and therefore, the endothelial damage was never a point of discussion. However, for DMEK, it is important to maintain the endothelial integrity and viability; therefore, it is necessary to understand the effect of the bubble on the endothelial cells.

As the air and the liquid bubbles are prepared using a similar technique, that is, using pressure, as compared to the other currently available techniques such as peeling or hydro-separation, the two methods were compared to understand the mechanical stress and its effects on the endothelial cell viability. This paper describes a technique of using liquid bubble as a medium of separation prepared using immersion method and its pros and cons over air bubble. Therefore, we set out to find if air bubble was actually helpful or could there be other possibilities too, like liquid.

Methods

Collection of samples and pre-evaluation

Human cadaveric donor corneas ($n = 20$) deemed unsuitable for transplantation due to, (i) corneal pathologies that were found during the preservation, (ii) unsuitable donor or (iii) lower endothelial cell density (ECD) (<2200 cells/mm²) were collected from The Veneto Eye Bank Foundation (Mestre, Italy) with written consent from the next of kin for using the tissues for research. The corneal ECD and viability were evaluated using a vital trypan blue stain (0.25%). The corneas were washed with sterile PBS and placed in a hypotonic sucrose solution (1.8%) to determine the intercellular borders, the ECD and mortality. These parameters were further evaluated using 50 \times and 100 \times magnification of an inverted light microscope (Axiovert 25; Carl Zeiss, Germany). A 10 \times 10 calibrated reticule was inserted in the eye piece of the microscope to manually determine central (6–8 mm) and peripheral (4–2 mm) ECD and mortality. The mean of five counts was considered suitable for this study.

Submerged hydro-separation technique

The donor tissues were immersed in a sterile basin containing 15–20 ml of sterile tissue culture medium (TCM) [2% newborn calf serum with MEM-Earle as a base medium along with 25 mM Hepes buffer, 26 mM sodium bicarbonate, 1 mM pyruvate, 2 mM glutamine, 250 ng/ml amphotericin B, 100 IU/ml penicillin G, and 100 μ g/ml streptomycin]. The sclera was held firmly with sterile forceps. A 25-gauge needle (bent with bevel up at an angular position of 90°) connected to a 1-ml syringe was used to inject air/liquid (TCM) into the cornea through the sclera using trabecular meshwork as primary point of reference for needle insertion (Parekh et al. 2014a). The needle was moved radially beneath the endothelium approximately up to 3 mm towards the central cornea. Using the conventional ‘big-bubble’ technique, the air and the liquid were forced in the cornea between the DM and stroma or in the posterior stroma to enhance the separation. For multiple injection sites or higher quantity of air/liquid required, the syringe was disengaged with the needle keeping the needle fixed inside the cornea. The syringe was refilled and re-engaged, and the medium was reinjected. The bubble was enlarged further up to 9–11 mm diameter. The air/liquid was removed using the same needle, and the ECD and viability were determined.

Tight junction analysis ($n = 8$) using *Zonula Occludens-1 (ZO-1)* immunostaining

The tissues were fixed in 4% PFA (Paraformaldehyde) at 4°C overnight. A 9-mm DMEK lenticule was excised using a Moria punch (Moria, Antony, France) and was further washed in 10 \times PBS for 2 min. The lenticules were treated with 0.5% Triton-X-500 (Sigma-Aldrich, St. Louis, MO, USA) and incubated at room temperature on a shaking table for 30 min and washed twice with 10 \times PBS with a gap of 10 min each. 2% goat serum was used for blocking (Sigma-Aldrich) at 31°C for 2 hr. The lenticules were incubated with ZO-1 (1:500; Invitrogen, Camarillo, CA, USA) at 31°C overnight and washed three times (next day) with 10 \times PBS for 15, 20 and 25 min, respectively. FITC-conjugated goat anti-mouse (1:500; Sigma-Aldrich) second-

ary antibody was used along with 20% goat serum and incubated at 31°C for 3 hr. The samples were covered with aluminium foil to avoid bleaching. PBS washing was carried out three times for 10 min each in dark to avoid bleaching. The samples were dried and mounted with mounting medium containing DAPI (Vectashield, Burlingame, CA, USA) and further preserved in dark at 4°C for 20 min before viewing it using a confocal microscope (Zeiss) at 400 \times magnification.

DNA integrity ($n = 6$) with DNAQual kit
DNA integrity is a new method to determine the DNA damage. It was checked as an additional parameter to measure the amount of DNA damage using each of the two methods. After the tissues were bubbled, the lenticules were punched (as above), gently separated and placed in lysis buffer with proteinase K overnight at 56°C. DNA was isolated as per the manufacturer’s protocol using QIAamp DNA Mini kit (50) (Qiagen, Hilden, Germany). Human DNA quality was checked using the DNAQual kit (Eurobio, Paris, France), which measures a DNA Quality index by qPCR duplex using VIC and Texas red labelled probes. Three microlitres of extracted DNA were mixed with 12 μ l of DNAQual kit master mix and quantitative real-time PCR was performed following manufacturer’s instructions. The sample DNA quality is evaluated using a standard curve obtained from very high-quality DNA by the Delta Delta C_t method. Standard high-quality DNA has a DNAQual index of 1. Samples with a DNAQual >0.8 are considered undegraded, between 0.6 and 0.8 medium degraded, and <0.6 as highly degraded. The test was performed in triplicates on each DNA sample using a CFX96 Bio-Rad qPCR instrument on the VIC and Texas red channels.

Histological analysis ($n = 6$) using *Periodic Acid-Schiff (PAS)* staining

The tissues were deflated following the bubble generation and were preserved in 10% formalin. Histological examination was carried out using PAS staining and the samples were observed at 400 \times magnification.

Statistical analysis

Student’s *t*-test was employed for determining the statistical difference

between the two groups, air and liquid. The groups showing $p < 0.05$ were considered as statistically significantly different.

Results

Corneal donor characteristics

Average age of the donor corneas was $65.3 (\pm 7.5)$ years. Average post-mortem time (time between death and retrieval of the cornea) was $10.8 (\pm 5.9)$ hr, whereas the average preservation time (preservation time in organ culture at 31°C) was $13.5 (\pm 4.2)$ days. Prebubble endothelial cell density did not show any statistical significance ($p = 1$) as the corneas were used from the same donor (right and left) to study the air and liquid separation without any tissue bias as showed in Fig. 1.

Parametrical status

Air bubble showed 80% yield, whereas that with liquid bubble was 100%. Six cases required single injection, two cases with double injections, one case each with triple and four times with air separation with an average of $1.9 (\pm 1.08)$, whereas seven cases required single injection, two cases with double and just one case with triple injection with liquid separation with an average of $1.4 (\pm 0.69)$, $p = 0.3317$. However, the data were not statistically significant. The average quantity required with the liquid bubble was $0.77 (\pm 0.52)$ ml as compared to air which required $1.11 (\pm 1.33)$ cm^3 , $p = 0.4055$. The average diameter that was obtained with air bubble was $9.12 (\pm 1.71)$ mm and that with liquid was $9.78 (1.75)$ mm, $p = 0.4362$. Although the data were not statistically significant, it was observed that the bubbles created using liquid as a medium of separation showed larger diameters overall, with min of 9.5 mm and max of 11 mm diameter, whereas the maximum diameter that was obtained with air was 10 mm. 8.9% (± 12.38) trypan blue positive cells were observed with air and that with liquid was 6.25% (± 9.57) with $p = 0.6268$. Although the ECD did not change much, the viable endothelial cell density (Parekh et al. 2014a,b) was calculated postbubble which resulted in $2004.2 (\pm 639.0)$ cells/mm^2 for the bubbles that were prepared using air as a medium of separation and 2062.5

(± 652) cells/mm^2 in an average without any statistical significance ($p = 0.2171$). The above data are represented in Fig. 1. However, higher sample size may be required to confirm these data on statistical grounds.

Trypan blue staining results

It was difficult to observe the intercellular borders of the lenticule prepared using air bubble (Fig. 2A,B), which limits the preshipment endothelial cell survival analysis. Mortality or trypan blue positive cells were identified at higher magnification, and the viable endothelial cell density was calculated as previously described (Parekh et al. 2014b). This could be a possible reason due to stromal oedema. However, with liquid bubble, the intercellular borders were easily observed and the cells were clearly identified (Fig. 2C,D). This may be due to the absence of interference or blocking of the sucrose flow between hypotonic to hypertonic environments in case of liquid bubble, whereas air blocks this movement and therefore, it is difficult for sucrose solution to pass between the intercellular borders and hence the cells are not clearly visualized.

Immunostaining with ZO-1

Immunostaining showed the expression of tight junction proteins in both lenticules prepared with air and liquid with higher presence of DAPI-integrated cells in the lenticules prepared using liquid bubble, as showed in Fig. 3A,B.

DNA integrity analysis

DNAQual for all the samples was obtained by the Delta Delta C_t method using the standard curve presented in Fig. 4 showing C_t values for high-quality grade DNA (12, 5, 25 and 50 $\text{ng}/\mu\text{l}$ – round symbol). DNAQual for these standards were about 1. C_t values for the samples are shown as cross-symbols. The positive control included in the kit was a degraded DNA and showed a very low DNAQual index as expected. The DNAQual index for samples was plotted for individual samples. On duplicate cornea, there is no statistically significant difference between the two methods used, although the air method seems to give a more consistently degraded DNA (Fig. 4).

Histological analysis

It was found that the samples prepared using liquid showed very low or no traces of stromal residue. However, a small amount of collagen fibrils was found in a few samples as showed in the representative images. The DM and the endothelium were separated from the stroma precisely (Fig. 5A). On the other hand, the samples prepared using air bubble showed presence of a slight stromal residue (Fig. 5B). Higher sample size is required to prove if this is the usual trend.

Discussion

DM and endothelium can be separated from the overlying stroma with a simple technique using air dissection. The major issue with this preparation, however, remains still critical in terms of graft preparation and manipulation as it requires high surgical skills to generate a lenticule without perforating it and also maintaining the endothelial integrity. The air dissection allows monitoring the insertion site and maintains the cell integrity considering the appropriate depth required beneath the endothelium. However, one of the important benefits that we found using liquid as a medium of separation was the generation of higher yield, and none of the corneas was wasted maintaining the yield rate at 100% as compared to 80% with air separation but had a statistical insignificant trend. Although the endothelial cell loss encountered in this study was similar in either of the preparation methods, comparative studies and long-term follow-up are required to determine if it is significant.

We believe that there may be potential endothelial damage with prolonged air exposure and hence to reduce any possible interference the corneas were submerged in the TCM for this study. Submerged hydro-separation method helps to keep the cornea moist throughout the procedure and therefore does not allow drying of the endothelium, if any. It was also found that if air bubble separation fails then the tissue is lost in most of the cases. However, if the liquid bubble fails with the primary injection site, then, it could be reinjected from a different site of injection or simply can be shifted to air separation. This gives a further chance

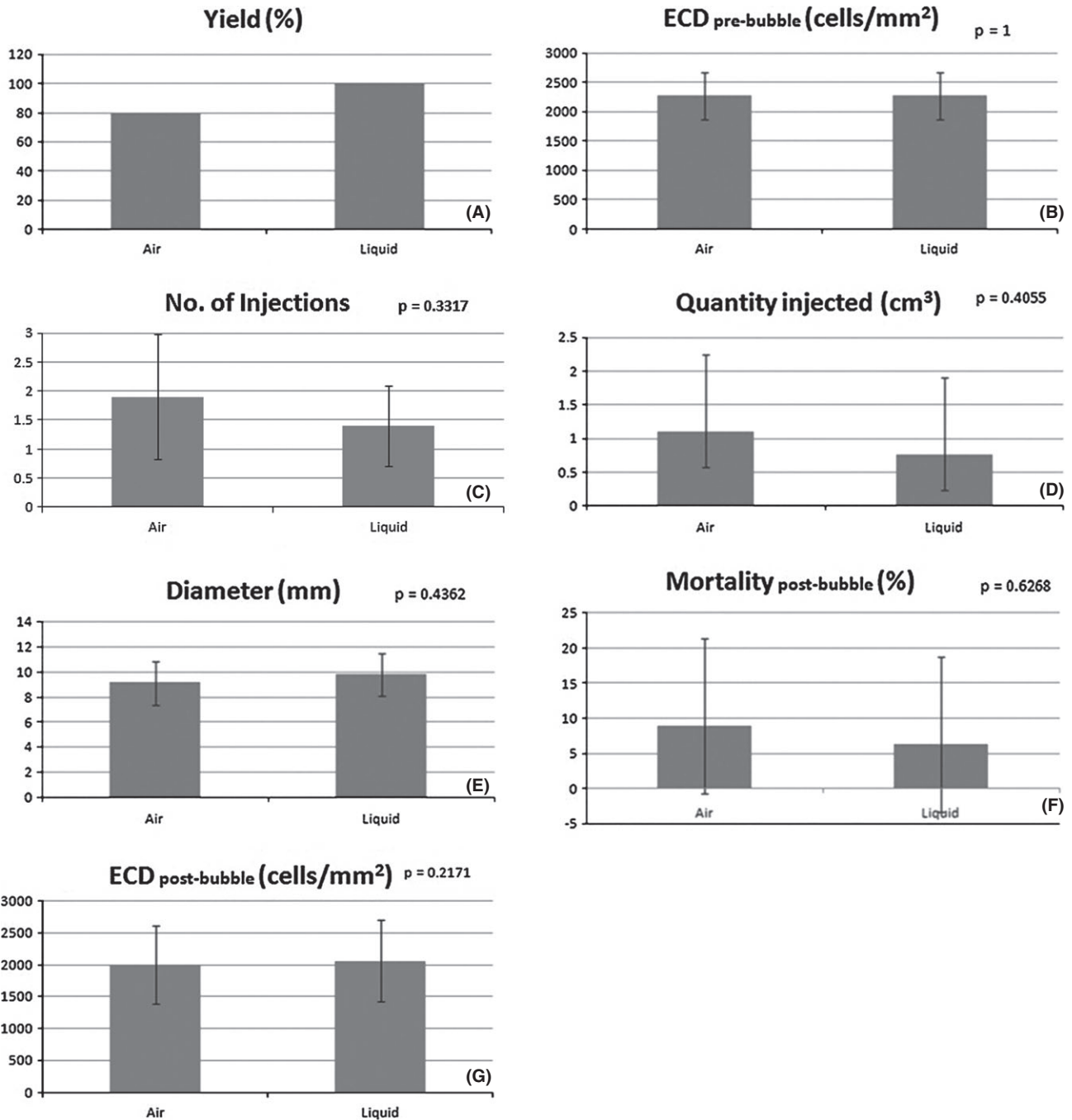


Fig. 1. Parametrical status of the bubbles created using air and liquid. (A) Yield generated; (B) ECD prebubble; (C) number of injections required for creating the respective bubbles; (D) quantity of air and liquid injected for generating the bubbles; (E) diameter obtained with either of the bubbles; (F) amount of trypan blue positive cells (mortality) that were observed postbubble; and (G) ECD postbubble. None of the parameters was statistically significant.

to reduce tissue wastage. It was also observed that it is easy to separate the lenticule after the liquid bubble as compared to air bubble. As there is no medium keeping the stroma and DM separated (unlike liquid separation), the two layers stick back together, and hence, it becomes slightly difficult to separate them without compromising the endothelial viability, a step which is easier with liquid separation. Another observation was that

with liquid bubble, the force applied to generate the bubble is less as compared to air bubble. It is hypothesised that the liquid enters at one point and enlarges from that particular point, and therefore, it becomes easier to inject the liquid and also to monitor the threshold of the bubble injection.

Once the liquid is injected in the cornea, it spreads eventually through one point extending to the rest of the cornea, this may also cut the stroma if

the liquid is injected in the stromal layer, and it results in less oedema and hence higher yield with less residual stroma as compared to air injection. One of the important questions raised is how the liquid finds its way. When the liquid was inserted exactly between the DM and the stroma, a precise separation was achieved which was expected. But even when the liquid was injected in the posterior stroma, a reasonable separation was obtained. A

possible hypothesis could be that air injection increases the stromal oedema and uses the extra space in the stroma to settle down, whereas with the high viscosity and force of the liquid bubble, the stromal oedema is lowered. More-

over, with increase of the liquidity in the stromal lamellae, the posterior stroma is punctured at one of the sites, which help the liquid to flow from the stroma and reach the gap between the DM and the stroma. Although the

corneal dynamics is not yet proved, this explanation is just a hypothesis. As explained earlier, this further reduces the manipulations and damages.

Also, the peripheral punctures (near the limbus region) do not allow successful air injection/separation, whereas due to higher viscosity of the liquid, the bubble is usually generated as it does not ooze out of these small punctures, which are usually seen with air. As per our experience, it was difficult to create an air bubble in a peripherally punctured cornea as the air is easily released out of these holes, but if the same cornea is injected with liquid, a liquid bubble was obtained without any further damages or manipulations. This is an additional advantage considering the reduction of the tissue wastage in surgical theatre or eye banks.

The authors also compared the technique with a standard peeling method to excise the DMEK lenticule. According to our experience with the stripping technique, liquid bubble separation may have following advantages: (i) the acquired graft size was higher as compared to the air (type I) (Dua et al. 2013) and peeling technique, and this is because the stripping technique (scuba) allows the excision of the central zone and rejects the peripheral area, whereas the liquid bubble separates the entire

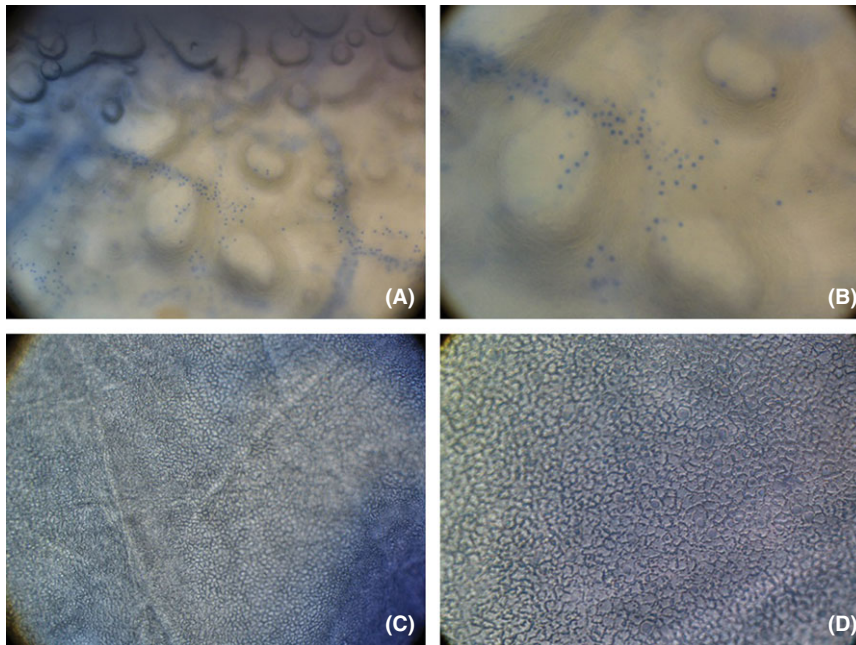


Fig. 2. Trypan blue staining on the endothelial cells post-bubble preparation. (A) Air bubble, 50× – only the trypan blue positive staining was observed; (B) air bubble, 100× – the scattered mortality was observed at higher magnification; (C) liquid bubble, 50× – endothelial cells were clearly observed with defined endothelial borders, cell counting and visualization could be performed using liquid but not with air bubble; (D) liquid bubble, 100× – further clarification of cellular morphology and mortality was confirmed at higher magnification.

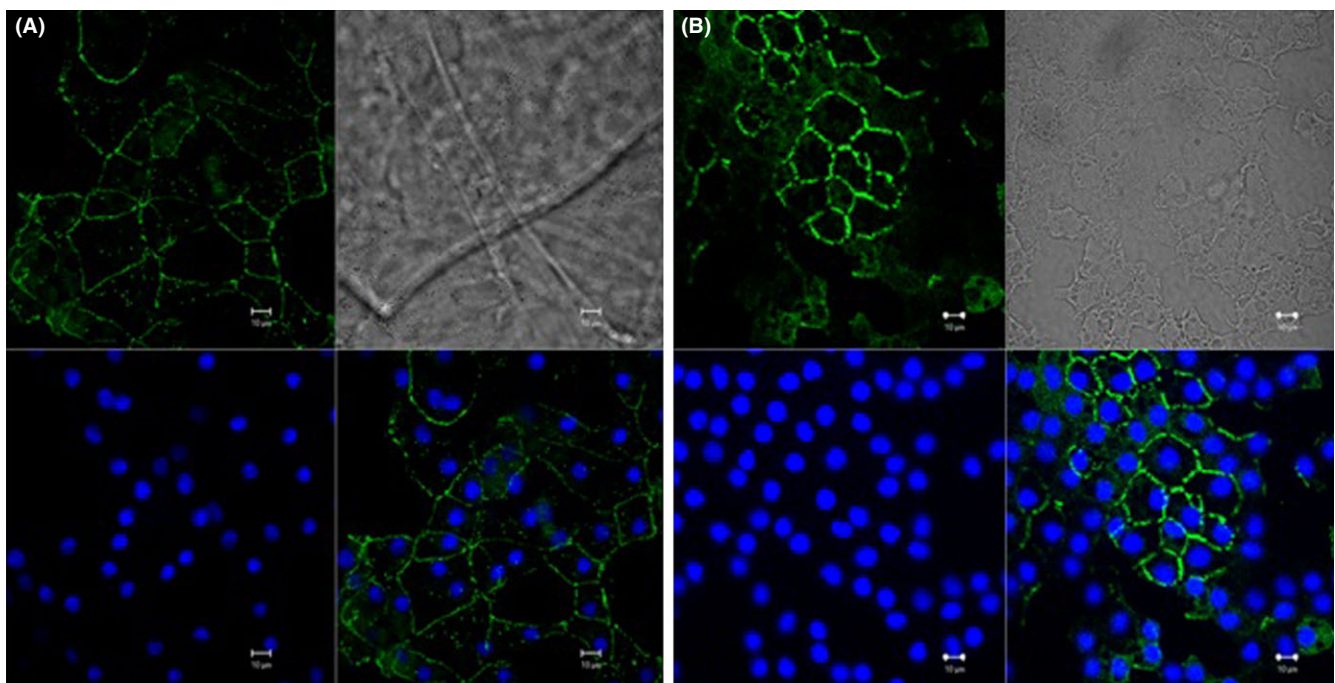


Fig. 3. Immunostaining using zonula occludens 1 (ZO-1) at 400× magnification. Intercellular tight junctional assessment and expression of the ZO1 using (A) air bubble and (B) liquid bubble [Scale = 10 μm]. Top left-expression of ZO-1; top right-phase contrast; bottom left-DAPI positive cells; and bottom right-merge of ZO-1 and DAPI.

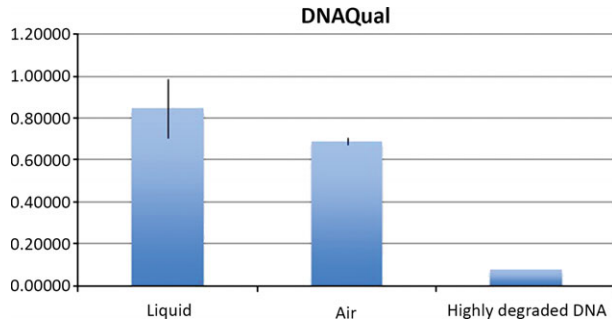


Fig. 4. DNA integrity analysis using DNAQual kit. (A) DNA quality analysis for the lenticules created using air as a medium of the bubble versus liquid. The control showed a highly degraded DNA, whereas the lenticule prepared using liquid bubble showed a higher maintenance of the DNA as compared to air.

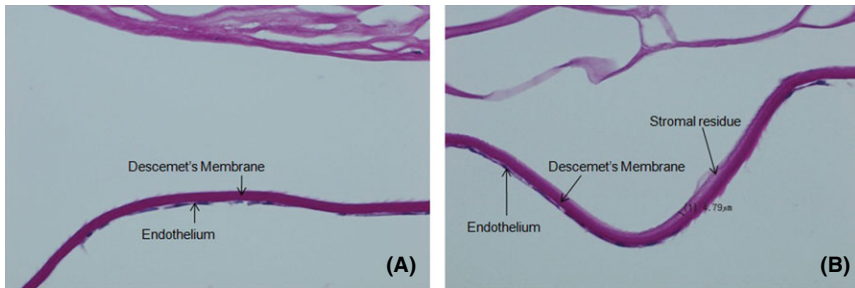


Fig. 5. Histological analysis using Periodic Acid-Schiff (PAS) staining at 400× magnification. (A) Liquid bubble separation of the Descemet membrane and endothelium with stroma. There were very low to no traces of the stroma; (B) separation with air bubble showed slightly thick stromal residue. If the anterior stroma is well observed, it is seen that with air bubble the stroma opens wide, therefore, creating more oedema as compared to liquid.

tissue with >9 mm diameter which could be punched using a 9-mm trephine to obtain a larger graft diameter, (ii) liquid bubble and peeling technique allow preshipment endothelial cell survival analysis, (iii) time required to prepare the graft is less as compared to peeling technique and (iv) a prevalidated graft can be obtained for the surgery. However, no statistical analysis was carried out with peeling method due to lower sample size and multiple variants as compared to air and liquid. Although the graft detachment was easy with either technique, the liquid separation allows the presence of a liquid interface which helps to keep the DM and the stroma separated which may be easier for the separation and loading of the tissue. The endothelial cell survival after either of the techniques (air, liquid or peeling) was not found to be statistically significant. However, peeling technique has a unique advantage over air and liquid in terms of preparing DMEK lenticules from the donors that have undergone a cataract surgery. The yield generation in liquid was higher, and moreover, the liquid bubble can be created with controlled pressure.

Thus, the major advantages that were found with the liquid separation include reduced drying of the endothelium, number of injections are lower, higher generation of yield and better separation in terms of graft diameter and histology. However, all listed hypothesis needs a further verification. For corneal surgeons and eye bank personnel who are accustomed to handling donor tissue, no particular additional skills are required to master the technique as it is only the replacement of air with liquid. We expect that the above advantages and the approach of this technique would facilitate uptake of the DMEK procedure.

References

Anwar M & Teichmann KD (2002): Big-Bubble technique to base Descemet's membrane in anterior lamellar keratoplasty. *J Cataract Refract Surg* **28**: 398–403.
 Busin M, Scorcina V, Patel AK, Salvalaio G & Ponzin D (2010): Pneumatic dissection and storage of donor endothelial tissue for Descemet's membrane endothelial keratoplasty. *Ophthalmology* **117**: 1517–1520.
 Dapena I, Ham L & Melles GRJ (2009): Endothelial keratoplasty: DSEK/DSAEK or DMEK—the thinner the better? *Curr Opin Ophthalmol* **20**: 299–307.

Dua HS & Said DG (2011): Much froth over bubbles. *Br J Ophthalmol* **95**: 1041–1042.
 Dua H, Faraj L, Said D, Gray T & Lowe J (2013): Human corneal anatomy redefined: a novel pre-Descemet's layer (Dua's layer). *Ophthalmology* **120**: 1778–1785.
 Groeneveld-van Beek EA, Lie JT, van der Wees J, Bruinsma M & Melles GR (2013): Standardized 'no-touch' donor tissue preparation for DALK and DMEK: harvesting undamaged anterior and posterior transplants from the same donor cornea. *Acta Ophthalmol* **91**: 145–150.
 Ham L, Balachandran C, Verschoor CA et al. (2009a): Visual rehabilitation rate after Descemet membrane transplantation: Descemet membrane endothelial keratoplasty. *Arch Ophthalmol* **127**: 252–255.
 Ham L, Dapena I, Van Lujik C, van der Wees J & Melles GR (2009b): Descemet membrane endothelial keratoplasty (DMEK) for Fuchs endothelial dystrophy: review of the first 50 consecutive cases. *Eye* **23**: 1990–1998.
 Ignacio TS, Nguyen TT, Sarayba MA et al. (2005): A technique to harvest Descemet's membrane with viable endothelial cells for selective transplantation. *Am J Ophthalmol* **139**: 325–330.
 Lie JT, Birbal R, Ham L et al. (2008): Donor tissue preparation for Descemet membrane endothelial keratoplasty. *J Cataract Refract Surg* **34**: 1578–1583.
 Melles GR, Wijdh RH & Nieuwendaal CP (2004): A technique to excise the Descemet membrane from a recipient cornea (descemetorhexis). *Cornea* **23**: 286–288.
 Muraine M, Gueudry J, He Z, Piselli S, Lefevre S & Toubeau D (2013): Novel technique for the preparation of corneal grafts for descemet membrane endothelial keratoplasty. *Am J Ophthalmol* **156**: 851–859.
 Parekh M, Ruzza A, Salvalaio G et al. (2014a): Descemet membrane endothelial keratoplasty tissue preparation from donor corneas using a standardized submerged hydro-separation method. *Am J Ophthalmol* [Epub ahead of print].
 Parekh M, Salvalaio G, Ferrari S et al. (2014b): A quantitative method to evaluate the donor corneal tissue quality used in a comparative study between two hypothermic preservation media. *Cell Tissue Bank* [Epub ahead of print].
 Studeny P, Farkas A, Vokrojova M et al. (2010): Descemet membrane endothelial keratoplasty with a stromal rim (DMEK-S). *Br J Ophthalmol* **94**: 909–914.
 Zarei-Ghanavati S, Khakshoor H & Zarei-Ghanavati M (2010): Reverse big bubble: a new technique for preparing donor tissue of Descemet membrane endothelial keratoplasty. *Br J Ophthalmol* **94**: 1110–1111.
 Zhu Z, Rife L, Yiu S et al. (2006): Technique for preparation of the corneal endothelium-Descemet membrane complex for transplantation. *Cornea* **25**: 705–708.

Received on February 20th, 2014.
 Accepted on July 3rd, 2014.

Correspondence:

Diego Ponzin, MD
 The Veneto Eye Bank Foundation
 Padiglione Rama, Via Paccagnella 11
 30174 Zelarino, Venice, Italy
 Tel: +0039 0419656413
 Fax: +0039 0419656471
 Email: diego.ponzin@fbov.it