

ORIGINAL ARTICLE

Supracricoid partial laryngectomy: oncological and functional results

Antonio Pastore, Francesco Stomeo, Chiara Bianchini, Andrea Ciorba, Stefano Savini, Roberto Merlo, Giulia Chiarello, Nicola Malagutti, Stefano Pelucchi

ENT & Audiology Department, University Hospital of Ferrara, Ferrara, Italy

Summary

Purpose: The purpose of this study was to evaluate the oncological and functional results of patients affected by laryngeal squamous cell carcinoma (SCC) and surgically treated by supracricoid partial laryngectomy (SCPL) at the ENT Department of the University Hospital of Ferrara.

Methods: In this retrospective study a total of 155 patients (149 males/96.1% and 6 females/3.9%), have been included. All patients were treated between January 1st 1998 and December 31st 2010, by SCPL, including 126 cricohyoidopexies (CHP) and 29 cricohyoidoepiglottopexies (CHEP).

Results: The overall survival (OS) at 3 and 5 years was 88.77 and 83.24%, respectively and the disease-free survival (DFS) at 3 and 5 years was 84.4 and 81.55%, respectively. The recurrence rate was 17.5%, with local recurrences in 12.1% of the cases, regional in 4.7% and distant metastasis in 0.7% of the cases. Synchronous second primary tumors

were 0.7% and metachronous second primary cancers (MSPCs) 5.4%. Removal of nasogastric feeding tube (NGT) or percutaneous endoscopic gastrostomy (PEG) was performed in 98.7% of the patients and lasted 22 days on average after SCPL (range 9-60), while decannulation was performed in all of patients at the 27th day on average after surgery.

Conclusions: Oncological outcomes of this series are consistent with those of the literature, showing that SCPL is an effective and safe procedure in terms of survival rate and disease control. Functional outcomes confirmed that SCPL allows a good organ preservation and recovery of laryngeal functions.

Key words: cricohyoidoepiglottopexy, cricohyoidopexy, laryngeal cancer, squamous cell carcinoma, supracricoid partial laryngectomy, surgery

Introduction

Laryngeal SCC is one of the most common head and neck tumors and represents 1-2% of all cancers [1]. Nowadays, several options are available to treat laryngeal SCC, varying on tumor localization, cartilage involvement and local extension [2,3].

The concept of "organ preservation" was initially referred for radiotherapy (RT) and chemotherapy or concurrent chemoradiotherapy (CCRT) protocols [4,5]. However, many studies have recently demonstrated that these therapeutic options can lead to important long-term effects [6] and often require further salvage surgery [7].

Several surgical conservative strategies, also allowing laryngeal partial preservation, have been developed and are available today for the treatment of laryngeal SCC, including partial vertical and horizontal supraglottic laryngectomies, and transoral laser endoscopic surgery [8,10]. SCPL is also a partial laryngeal operation that allows complete tumor removal in selected cases of glottic and supraglottic SCC while preserving laryngeal function. SCPL can be performed with cricohyoidopexy (SCPL-CHP) or with cricohyoidoepiglottopexy (SCPL-CHEP), on the basis of the different types of reconstruction achieved to create a hyoid

pexis. SCPL is indicated in the treatment of T2 and T3 glottic or supraglottic cancer, and selected T4a [10,11].

The purpose of our study was to evaluate the oncological and functional results of a series of 155 patients affected by laryngeal SCC and surgically treated by SCPL.

Methods

In this retrospective study 155 patients affected by laryngeal SCC and treated by SCPL at the ENT Department of the University Hospital of Ferrara between January 1st 1998 and December 31st 2010, have been included. There were 149 male (96.1%) and 6 female (3.9%) patients, with mean age of 63.5 years (range 30-81).

All patients underwent the same diagnostic protocol: direct laryngoscopy followed by microlaryngoscopy with biopsy, thorax imaging assessment, CT of the larynx and neck and/or neck ultrasonography. In particular, thoracic CT and/or bronchoscopy or esophagoscopy were performed in selected cases.

Written informed consent was obtained from each patient prior to surgery in order to collect the clinical data, according to the Italian law.

All patients included in this series were affected by glottic or supraglottic laryngeal SCC staged according to the TNM UICC 2009 classification [8]. Laryngeal SCC was clinically classified as cT1b (2%), cT2 (70.9%), cT3 (27.1%), while no cT4 cases were registered. All patients underwent SCPL with CHP or with CHEP.

During the postoperative period all patients were treated by the same protocol: on day 5-6 after SCPL, logopedic exercises started with the aim of mobilizing the neolarynx and particularly the residual crico-arytenoid unit (CAU(s)). Since day 7-8, a deglutitory rehabilitation also started. NGT was subsequently removed as soon as patients reached the ability of swallowing food of semisolid consistence and liquids. Then, tracheotomy was definitively closed as soon as deglutitory and respiratory functions were completely reestablished.

The study had a minimum follow-up period of 36 months after SCPL (range 36-137).

Oncological and survival evaluation

To define the oncological outcomes of the studied

group, survival outcomes were investigated through the Kaplan-Meier method [9] in order to evaluate the OS and the DFS in the follow-up period (36-137 months from SCPL).

Functional evaluation

Counting from the day of surgery, the functional evaluation and the success in achieving several skills were evaluated. These included: (1) the beginning of the deglutitory rehabilitation; (2) the removal of NGT/PEG with recovery of oral feeding; (3) the permanent tracheotomy closure; and (4) hospital stay.

Statistics

The SPSS software (v.12.0; SPSS Inc, Chicago, Ill) for Windows was used for the statistical analyses. The analysis of biological and clinical variables was conducted using the chi-square test. The Kaplan-Meier method with log-rank test were used to evaluate survival data and to measure significance of differences in survival between different tumor T stages [9]. A p value <0.05 was considered as statistically significant.

Results

SCPL was the primary treatment of laryngeal SCC for 135/155 patients (87.1%) and salvage surgery for 20/155 (12.9%) after failure of previous laser surgery (11/155 cases) or RT (9/155 cases). In particular SCPL with CHP were performed in 126 (81.3%) patients, and SCPL with CHEP in 29 (18.7%) patients. Both arytenoids were conserved in 111/155 SCPL (71.6%), including 91/126 CHP-2 (72.2% of CHPs) and 20/29 CHEP-2 (69% of CHEPs).

Neck dissection (ND) was performed at the same time with SCPL in 43/155 patients (27.9%). ND had a curative purpose in 27/43 patients (pre-operatively evaluated as cN+, 62.8%) while it was performed as prevention in 16/43 patients (pre-operatively evaluated as cN0, 37.2%). NDs performed were a type III modified radical neck dissection (MRND), therefore saving spinal nerves, sternocleidomastoid muscle and internal jugular vein.

Table 1. Results of the histopathologic exams (pT and pN). Numbers represent number of patients

| | p N0 | p N1 | p N2a | p N2b | p N2c | Total |
|-------|------|------|-------|-------|-------|-------|
| p T1a | / | / | / | / | / | / |
| p T1b | 3 | / | / | / | / | 3 |
| p T2 | 89 | / | / | / | / | 89 |
| p T3 | 34 | 3 | 1 | 2 | 3 | 43 |
| p T4 | 17 | 2 | / | / | 1 | 20 |
| Total | 143 | 5 | 1 | 2 | 4 | 155 |

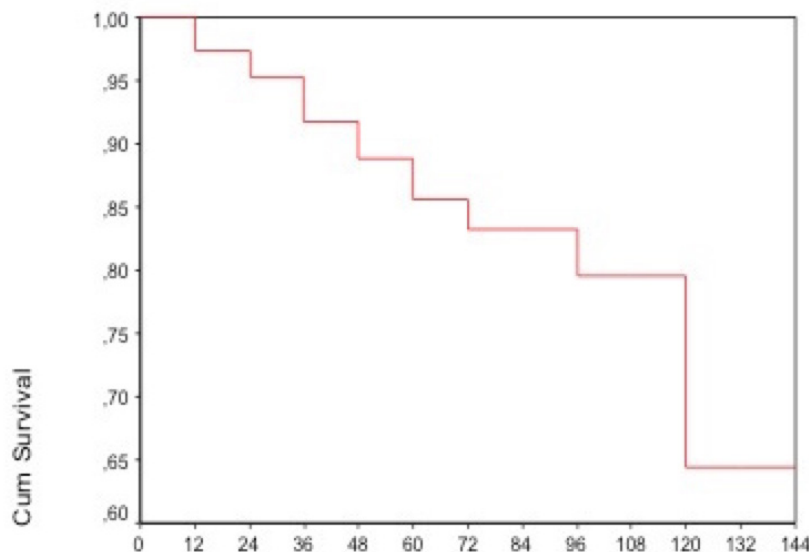


Figure 1. Overall survival of patients in the examined group.

The postoperative histopathologic examination showed regional metastasis in 12 out of the 43 (27.9%) patients that underwent ND. In 3 cases positive resection margins were observed and therefore total laryngectomy (TL) was performed. The results of the histopathologic examinations (pT and pN) are shown in Table 1.

Oncological results

Oncological outcomes were investigated in 149/155 patients as 6 were excluded from SCPL follow-up: 3 of them underwent TL due to positive resection margins on histopathologic examination and 3 because it was necessary to treat a severe postoperative dysphagia.

During follow-up, local recurrences (on T) developed in 18/149 patients (12.1%) and 7 of them died due to the T recurrence, while 11 were treated by TL plus RT and survived at least for the following 60 months of follow-up since that treatment. Regional recurrences (on N) developed in 7/149 patients (4.7%); 4 of them died due to the N recurrence, while 3 underwent radical neck dissection (RND) and survived at least for 60 months of follow-up since that treatment. Distant metastasis was found in 1/149 patient (0.7%). A synchronous tonsillar tumor was detected in 1/149 patient (0.7%) and it was surgically treated at the same time with the SCPL. Metachronous cancers were detected in 8/149 patients (5.4%) in the lung (3), pancreas (2), kidney (1), thyroid (1) and lymphoma. Moreover, laryngeal SCC represented the

second primary tumor for 1/149 patient, as he was previously affected by an oral SCC.

Overall, 26/149 (17.4%) deaths were registered, due to recurrence on T (7), on N (4), distant metastasis (1), lung SCC (3), cardiovascular (2) or cerebrovascular (1) diseases, cachexia (2), lymphoma (1), pancreatic cancer (1), kidney cancer (1), and unknown causes (3).

Survival evaluation

OS after 3 and 5 years since SCPL was 88.77 and 83.24% (Figure 1). DFS after 3 and 5 years from SCPL was 84.41 and 81.55% (Figure 2). OS based on the pT stage (Figure 3), showed no statistical significance (log rank, $p=0.2072$), hence the disease stage didn't affect the OS. DFS based on the pT stage (Figure 4), showed statistical significance (log rank, $p=0.0049$), confirming that the DFS was worse in patients with advanced laryngeal SCC.

Functional results

A) Deglutitory rehabilitation. The deglutitory rehabilitation started 11.5 days on average after SCPL (range 7-28). Sixty percent of patients began the deglutitory rehabilitation up to the 10th day, 29% between the 11th and the 20th day, while the remaining 11% up to the 30th day.

B) Recovery of oral feeding. The mean time to remove NGT/PEG was 22.1 days (range 9-60). In 3 patients the deglutitory rehabilitation was post-

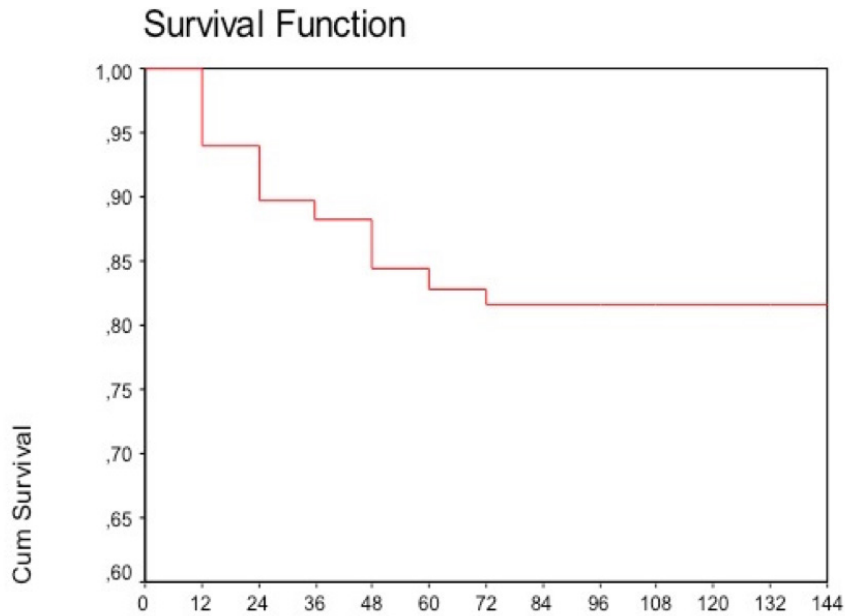


Figure 2. Disease-free survival after 3 and 5 years of the examined group

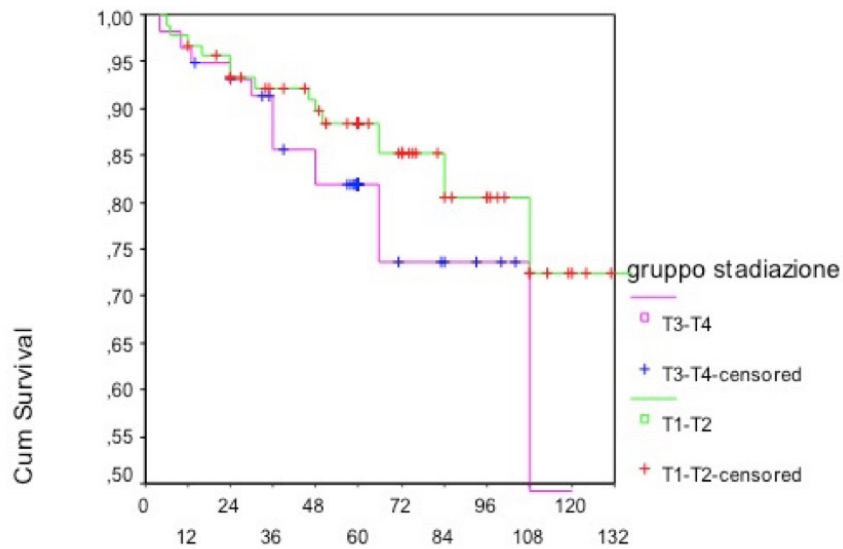


Figure 3. Overall survival based on pT stage between low (T1-T2) and advanced stages (T3-T4), showing no significant differences between the two groups (log rank, $p=0.2072$).

poned due to recurrent aspiration that complicated the postoperative course: 2 of them needed to have a PEG placed, that was removed on day 50 in a case and on day 60 in the other one; another patient developed an ab-ingestis pneumonia and was capable of oral feeding only on day 60 after SCPL. Three patients developed severe dysphagia making TL unavoidable.

C) Decannulation. The group for decannulation was reduced to 149/155 patients (6 TLs have

been excluded). All 149 patients (100%) were efficiently decannulated at 27.2 days on average after SCPL (range 13-90).

D) Time of hospitalization. The mean time of hospitalization was 31.1 days (range 15-90).

Complications

During the postoperative period, 22/155 (14.2%) patients developed immediate complications (on the 1st or 2nd day after SCPL) including

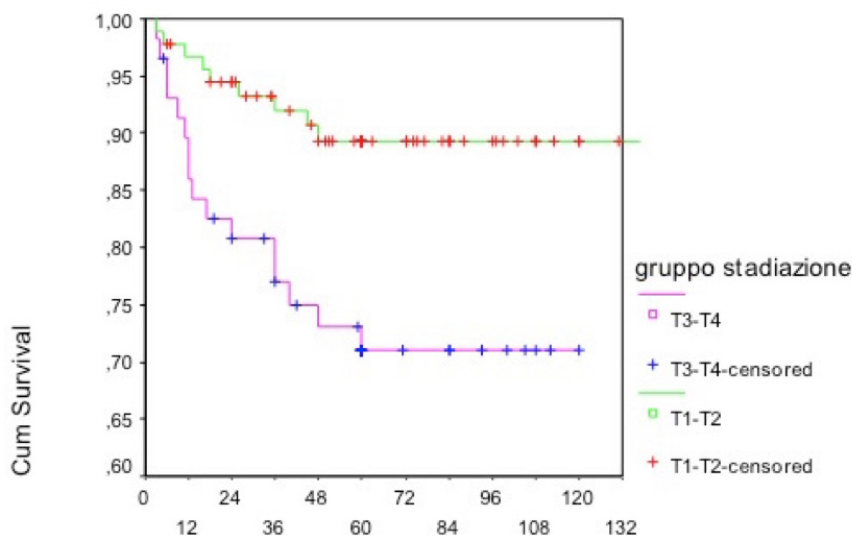


Figure 4. Disease-free survival based on pT stage showing significantly worse survival (log rank, $p=0.0049$) in patients with advanced (T3-T4) stages.

hemorrhage or subcutaneous supraclavicular emphysema.

Non-immediate complications occurred in 12/155 (7.7%) patients including ab-ingestis pneumonia, exudative pleuritis and peritracheostomal infection.

Late sequelae were: neoglottic stenosis due to arytenoid flaps or fibrotic changes (both conditions treated with CO₂ laser), pexis necrosis, and parapharyngeal abscess (treated with drainage). Interestingly, 7 patients that showed late sequelae, previously developed an early complication.

Discussion

SCPL was firstly described by Majer and Rieder in Austria in 1959 [10], then diffused by Arslan and Serafini, and Labayle and Bismuth since 1971 [11,12]. Subsequently modified by Piquet and Chevalier in 1974 [13], it was introduced in Italy by Calearo and Bignardi in 1986 [14,15]. Laccourreye et al. [16] further classified SCPL in CHP and CHEP, and therefore the technique was largely diffused all over the world [17-19]. Since then, several studies had already evidenced the oncological and functional validity of this technique in treating glottic and supraglottic laryngeal SCC.

The oncological results of the presented series are consistent with those of the literature. In particular, OS after 5 years is reported to range between 66.6% [20] and 95.6% [21-23]; in our study, the OS after 5 years was 83.24%. DFS ranged be-

tween 75% [24] and 95.4% [25-28] after 3 years; in the current study the DFS after 3 years was 84.4%.

Survival after SCPL is reported to be related to the recurrence of disease and to the development of secondary tumors in other sites. Previous reports showed that several parameters such as duration of follow-up, tumor stage and eventual variations of surgical techniques can influence the recurrence rate. De Virgilio et al. in a series of patients with advanced laryngeal SCC treated by SCPL, reported high rates of local and regional recurrence (28%) [22]. Karatzanis et al. reported a local disease control of 65.5%, due to a high rate of positive surgical margins [29]. Also Adamopoulos et al. [23] reported a high rate of local control (76.9%) at 3 years and a regional control of 69.2%, probably due to the modified CHP performed in that study, aiming to preserve a portion of the paraglottic space. On the other hand, Laccourreye et al. [17] and Nakayama et al. [5], reported in their studies no cases of local recurrences after 3 years and 28 months of follow-up, respectively. Chevalier and Piquet [25], in a series of 61 patients affected by supraglottic laryngeal SCC treated by CHP, reported a local control rate of 97%. In the series presented, the local recurrence rate was 12.1%, with 4.7% regional and 0.7% distant metastasis. Among those that developed local recurrence (12.1%), 7.4% were subjected to TL or RT and were living after 5-year follow-up. Also, of those that developed a regional recurrence (4.7%) 2% were operated with RND, and survived after a

5-year follow-up. Similar results have also been described by Bron et al. [26] (11.9 %), Sun et al. [27] (13%), Park et al. [18] (11.3%), Schwaab et al. [28] (5%) and Lima et al. [30] (4.7%).

Overall, the analysis of oncological outcomes reported in the literature demonstrates that SCPL decreases the need of TL in selected cases of laryngeal SCC in pT3-pT4 stages. SCPL can also guarantee an optimal local disease control and a higher laryngeal preservation in comparison to other reconstructive surgical techniques like vertical and horizontal supraglottic partial laryngectomies, in selected cases of laryngeal SCC staged as pT1b-pT2 [7]. Moreover, survival rates with SCPL are comparable to those estimated after RT from the data available in the literature [31].

Also, the functional outcomes from our series are consistent with those of the literature. In our experience, the NGT/PEG was successfully removed in 98.7% of the patients; in the literature, the success of NGT (or PEG) removal ranges between 81% (Lewin et al. [32]) and 100% (Castro et al. [33]), and it is usually performed 15-70 days

after SCPL [33]. In our study the NGT removal occurred 22 days on average after SCPL (range 9-60). Similar data in the literature have been reported by Nakayama et al. [24] and Cho et al. [34]. Decannulation was possible in all of our patients; decannulation rate in literature is reported to range between 86% [33] and 100% [24,27].

In conclusion, our study confirms the effectiveness of SCPL, which can be considered a valuable and safe procedure in terms of better survival rate and disease control. Functional outcomes, in particular, confirm that SCPL allows good organ preservation and a quick recovery of laryngeal functions. Since RT and CCRT are associated with multiple long-term side effects and can also lead to functional debilitation [34], SCPL should be always taken in consideration when treating pT2-pT3 glottic tumors.

Acknowledgements

The authors thank Dr Monica Rosignoli for her valuable contribution with the statistical analysis.

References

1. Starmer HM, Tippet DC, Webster KT. Effects of laryngeal cancer on voice and swallowing. *Otolaryngol Clin N Am* 2008;41:793-818.
2. Agrawal N, Ha PK. Management of early-stage laryngeal cancer. *Otolaryngol Clin N Am* 2008;41:757-769.
3. Forastiere A, Goepfert H, Maor M et al. Concurrent chemotherapy and radiotherapy for organ preservation in advanced laryngeal cancer. *N Engl J Med* 2003;349:2091-2098.
4. Matchay M, Moughan J, Trotti A et al. Factor associated with severe late toxicity after concurrent chemoradiation for locally advanced head and neck cancer: an RTOG analysis. *J Clin Oncol* 2008;26:3582-3589.
5. Nakayama M, Okamoto M, Seino Y et al. Delayed wound infection after supracricoid partial laryngectomy following failure of high dose radiation. *Eur Arch Otorhinolaryngol* 2001;268:273-279.
6. Nakayama M, Laccourreye O, Holsinger CF et al. Functional organ preservation for laryngeal cancer: past, present and future. *Jpn J Clin Oncol* 2012;42:155-160.
7. Gallo A, Manciooco V, Simonelli M et al. Supracricoid partial laryngectomy in the treatment of laryngeal cancer. *Arch Otolaryngol Head Neck Surg* 2005;131:620-625.
8. Sobin LH, Gospodarowicz M, Wittekind C (Eds): UICC International Union Against Cancer, TNM Classification of Malignant Tumors (7th Ed). Wiley-Blackwell, West Sussex UK 2009. Prima edizione italiana a cura di Carbone A., Zanetti R., Raffaello Cortina, Milano 2010.
9. Kaplan EL, Meier P. Nonparametric estimation from incomplete observations. *J Am Stat Assoc* 1958;53:457-481.
10. Majer EH, Rieder W. Technique de laryngectomie permettant de conserver la perméabilité respiratoire: la crico-hyoido-épiglotto-pexie. *Ann Otolaryngol Chir Cervicofac* 1959;76:677-683.
11. Arslan M, Serafini I. La laryngectomie totale avec rétablissement de la phonation et de la respiration naturelles. Premières résultats (4 cas). *Ann Otolaryngol (Paris)* 1970;87:509-518.
12. Labayle J, Bismuth R. Laryngectomie totale avec reconstruction. *Ann Otolaryngol Chir Cervicofac* 1971;88:219-228.
13. Piquet JJ, Desaulty A, Decroix G. Crico-hyoido-épiglotto-pexy. Surgical technique and functional results. *Ann Otolaryngol Chir Cervicofac* 1974;91:681-686.

14. Calearo C, Bignardi L. A personal experience with subtotal and conservation surgery as treatment for laryngeal cancer. *Arch Otorhinolaryngol* 1986;243:174-179.
15. Calearo C, Bignardi L. Subtotal reconstructive laryngectomy: author's experience. *Acta Otorhinolaryngol Ital* 1989;9:281-295.
16. Laccourreye H, Laccourreye O, Weinstein G et al. Supracricoid laryngectomy with cricothyroidopexy: a partial laryngeal procedure for selected supraglottic and transglottic carcinomas. *Laryngoscope* 1990;100:735-741.
17. Laccourreye H, Laccourreye O, Weinstein G et al. Supracricoid laryngectomy with cricothyroidopexy: a partial laryngeal procedure for glottic carcinoma. *Ann Otol Rhinol Laryngol* 1990;99:421-426.
18. Park JO, Joo YH, Cho KJ et al. Functional and oncologic results of extended supracricoid partial laryngectomy. *Arch Otolaryngol Head Neck Surg* 2011;137:1124-1129.
19. Rizzotto G, Crosetti E, Lucioni M et al. Subtotal laryngectomy: outcomes of 469 patients and proposal of a comprehensive and simplified classification of surgical procedures. *Eur Arch Otorhinolaryngol* 2012;269:1635-1646.
20. Lima R, Freitas EQ, Kligerman J et al. Supracricoid laryngectomy with CHEP: functional results and outcome. *Otolaryngol Head Neck Surg* 2001;124:258-260.
21. Topaloğlu İ, Bal M, Salturk Z. Supracricoid laryngectomy with cricothyroidopexy: oncological results. *Eur Arch Otorhinolaryngol* 2012;269:1959-1965.
22. De Virgilio A, Fusconi M, Gallo A et al. The oncologic radicality of supracricoid partial laryngectomy with cricothyroidopexy in the treatment of advanced NO-N1 laryngeal squamous cell carcinoma. *Laryngoscope* 2012;122:826-833.
23. Adamopoulos G, Yiotakis J, Stavroulaki P et al. Modified supracricoid partial laryngectomy with cricothyroidopexy: series report and analysis of results. *Otolaryngol Head Neck Surg* 2000;123:288-293.
24. Nakayama M, Okamoto M, Miyamoto S et al. Supracricoid laryngectomy with cricothyroidopexy or cricothyroidopexy: experience on 32 patients. *Auris Nasus Larynx* 2008;35:77-82.
25. Chevalier D, Piquet JJ. Subtotal laryngectomy with cricothyroidopexy for supraglottic carcinoma: review of 61 cases. *Am J Surg* 1994;168:472-473.
26. Bron L, Brossard E, Monnier P et al. Supracricoid partial laryngectomy with cricothyroidopexy and cricothyroidopexy for glottic and supraglottic carcinomas. *Laryngoscope* 2000;110:627-634.
27. Sun DI, Cho KJ, Cho JH et al. Pathological validation of supracricoid partial laryngectomy in laryngeal cancer. *Clin Otolaryngol* 2009;34:132-139.
28. Schwaab G, Kolb F, Julieron M et al. Subtotal laryngectomy with cricothyroidopexy as first treatment procedure for supraglottic carcinoma: Institut Gustave-Roussy experience (146 cases, 1974-1997). *Eur Arch Otorhinolaryngol* 2001;258:246-249.
29. Karatzanis AD, Waldfahrer F, Psychogios G et al. Resection margins and other prognostic factors regarding surgically treated glottic carcinomas. *J Surg Oncol* 2010;101:131-136.
30. Lima RA, Freitas EQ, Dias FL et al. Supracricoid laryngectomy with cricothyroidopexy for advanced glottic cancer. *Head Neck* 2006;28:481-486.
31. Bussu F, Paludetti G, Almadori G et al. Comparison of total laryngectomy with surgical (cricothyroidopexy) and nonsurgical organ preservation modalities in advanced laryngeal squamous cell carcinomas: a multicenter retrospective analysis. *Head Neck* 2013;35:554-561.
32. Lewin J, Hutcheson KA, Barringer DA et al. Functional analysis of swallowing outcomes after supracricoid partial laryngectomy. *Head Neck* 2008;30:559-566.
33. Castro A, Sanchez-Cuadrado I, Bernaldez R, Del Palacio A, Gavilan J. Laryngeal function preservation following supracricoid partial laryngectomy. *Head Neck* 2012;34:162-167.
34. Cho KJ, Joo YH, Sun DI et al. Supracricoid laryngectomy: oncologic validity and functional safety. *Eur Arch Otorhinolaryngol* 2010;267:1919-1925.