

Myoma migration: an unexpected “effect” with Ulipristal acetate treatment

A. WILLAME¹, R. MARCI^{1,2}, P. PETIGNAT¹, J. DUBUISSON¹

¹Department of Gynecology and Obstetrics, University Hospital of Geneva, Switzerland

²Department of Morphology, Surgery and Experimental Medicine, University of Ferrara, Italy

Alexia Willame and Roberto Marci contributed equally to this work

Abstract. – OBJECTIVE: Uterine myomas are one of the most common benign tumours, occurring in 20-40% of women of reproductive age. Ulipristal acetate (UPA) is a possible option for medical treatment of myomas. It induces amenorrhea and can reduce myoma volume before surgical treatment. Since its introduction in our department, we uncovered an unknown effect: migration of myoma.

CLINICAL CASE REPORTS: We describe three clinical case of myoma migration following three months UPA pre-operative treatment. The first woman presented with a FIGO 2 myoma, which migrated in FIGO 3. A previously planned hysteroscopy converted into a laparoscopy. The second woman also presented with a FIGO 2 myoma, which migrated in FIGO 3. Initially, a hysteroscopy was planned, but ultimately surgery was no longer required. The third woman presented with a FIGO 2-5 myoma, which migrated in FIGO 1. The previously planned laparoscopy converted into a vaginal myomectomy.

CONCLUSIONS: UPA induces a proapoptotic and anti proliferative effect of leiomyoma cells. It reduces expression of VEGF and reduces collagen deposition in the extracellular matrix. These mechanisms could induce migration of myoma. UPA as pre-operative treatment can induce migration of myoma and, therefore, can lead to preoperative conversion of surgery.

Key Words:

Ulipristal acetate, Myoma, Migration, Side effect, Expulsion.

Introduction

Uterine myomas are one of the most common benign tumours, occurring in 20-40% of women of reproductive age¹. They represent one of the main causes of anaemia among young women. Myomas can alter fertility and cause abnormal

uterine bleeding, dysmenorrhoea and pelvic pain, as well as seriously reducing quality of life (QoL)²⁻⁴. Surgery is currently the treatment of choice⁵. Hysterectomy remains the only radical therapy and is the most common treatment strategy⁶. It is, however, not suitable for women wishing to preserve their fertility. Surgical myomectomy represents an alternative treatment strategy, although it does not prevent recurrence and it may not be appropriate in the case of a polymyomatous uterus. Perioperative haemorrhagic risks must be taken into consideration, as those women also suffer from anaemia. Uterine embolization has proven to be effective with relatively minor long-term morbidity^{7,8}. It represents an alternative to surgery, but only for women who have no desire to conceive, as its impact on fertility is still a matter of debate⁹⁻¹¹. Medical treatments have also been developed^{5,7}. They are generally used preoperatively, but in specific cases, they can also be an alternative to surgery.

Ulipristal acetate (UPA) is a possible option for medical treatment of myomas. As myoma growth is dependent on estrogen and in particular on progesterone, a selective progesterone receptor modulator (SPRM) UPA was certified in 2012 by the European Medicines Agency for preoperative treatment of a three-month duration¹²⁻¹⁴. It induces amenorrhea in 80% of patients after only 3.5 days of treatment¹⁵, and it reduces myoma volume by 45%¹⁵. It does not reduce the estrogen circulating rate¹³. Persistent amenorrhea and stabilization of the size of the myoma six months after discontinuation of treatment make UPA an alternative to surgery¹⁵. At the moment, the drug has been studied for a maximum of 4 cycles of 12 weeks¹⁶. UPA seems to represent a good medical treatment alternative for women with symptomatic my-

oma¹⁷⁻²² and particularly for those suffering from submucosal myoma scheduled for *in vitro* fertilization²³. Although endometrial thickening can be observed in some patients, several studies indicate that this is benign and reversible following discontinuation of the treatment²⁴⁻²⁶.

Since the introduction of UPA as a certified treatment in Switzerland, we have administered Ulipristal Acetate at over a three months period to women suffering from myoma. Indications for UPA treatment followed the relevant Swiss Guidelines²⁷, which at that time only authorized UPA as a preoperative treatment. We have uncovered an unexpected secondary effect, which is myoma migration. We describe three clinical case reports of myoma migration.

Clinical Cases

Case History No. 1

This first case involved a nulliparous woman of 31 years of age who was originally from Russia. She suffered from primary infertility and was known to have a myoma that was first detected 2 years prior. She had no abnormal uterine bleeding. An MRI revealed a 37×32×25 mm-sized FIGO 2 myoma (Figure 1. Cross-sectional MRI T2 may 2015: myoma FIGO 2 of 37×32×25 mm 6 mm away from the serosa= volume of 21 cm³). A pre-operative treatment with Ulipristal Acetate followed by a hysteroscopic myomectomy was planned because of patient's infertility with a fast growth rate of the myoma. After three months, a control MRI revealed a smaller-sized FIGO 2 myoma, with a maximal dimension of 28 mm (Figure 2. Sagittal MRI T2 august 2015: myoma FIGO 2 of 28 mm = volume of 7 cm³). One

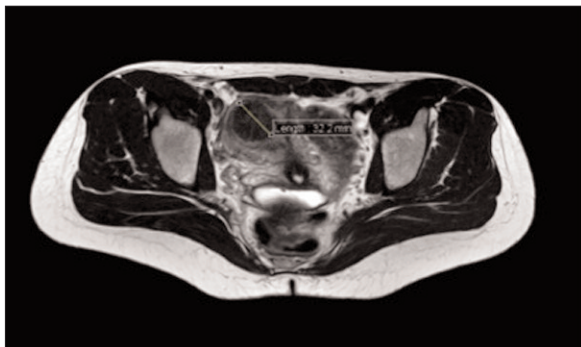


Figure 1.

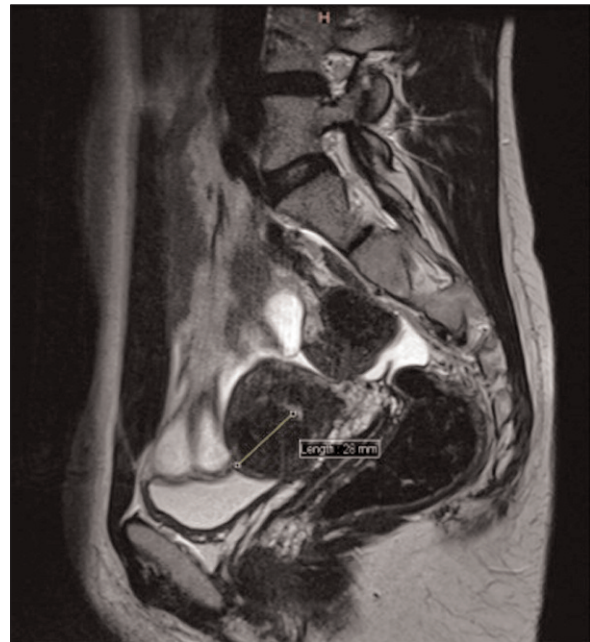

Figure 2.

month later, per-operative ultrasound assessed a FIGO 3 myoma measuring 38×10×12 mm (equating to a volume of 7 cm³). Hysteroscopy confirmed a FIGO 3 with an empty cavity (no impact of the myoma on the mucosa). Because of patient's infertility and its wish to get pregnant quickly, surgery was performed but a laparoscopy approach was chosen to remove the entire myoma, without opening the endometrial cavity. The resulting loss of blood amounted to 200 ml.

Case History No. 2

This case involved a 28 years-old multiparous woman who was originally from Serbia. She had no immediate desire for pregnancies. She suffered from abnormal uterine bleeding that was associated with mild anaemia (i.e. a haemoglobin level of 104 g/l). A transvaginal ultrasound revealed a massive 54 mm-sized FIGO 2 myoma (Figure 3. Ultrasound June 2015: myoma FIGO 1 of 54 mm 4 mm away from the serosa = volume of 119 cm³). A diagnostic hysteroscopy confirmed a FIGO 2 grade, with a posterior impact on the endometrial cavity. Treatment of Ulipristal Acetate was initiated to reduce the size of the myoma and to obtain amenorrhea prior to perform a hysteroscopic resection. Three months later, a vaginal ultrasound revealed a smaller-

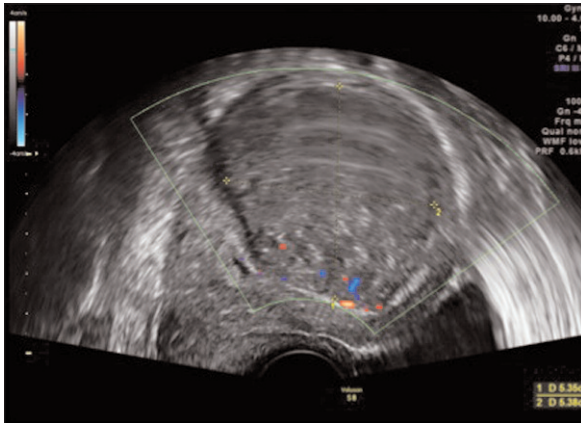


Figure 3.

sized myoma, with a maximal dimension of 44 mm (Figure 4. Three-dimensional ultrasound October 2015: myoma 44 mm = volume of 53 cm³). Amenorrhea was achieved. After one month, the perioperative ultrasound assessment revealed a 25 mm-sized FIGO 3 myoma that was confirmed by hysteroscopy (there was no longer impact on the mucosa). The patient’s haemoglobin level at this time was 141 g/l. The surgery was cancelled (no desire to conceive).

Case History No. 3

The final report provided here involved a 26 years old virgin female who was originally from the Philippines. She had no relevant prior medical history. She had suffered from abnormal uterine bleeding for 1 year. She presented with severe anaemia that required iron injection. Her

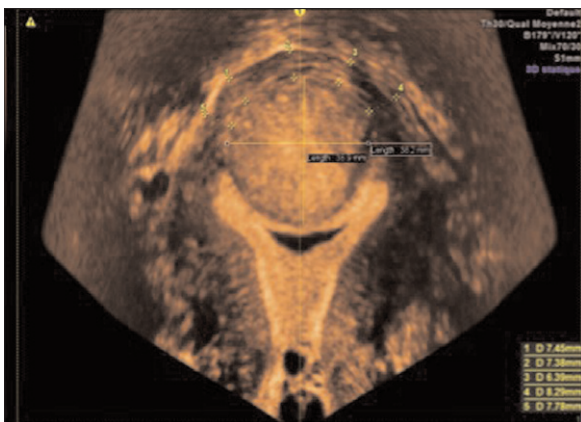


Figure 4.

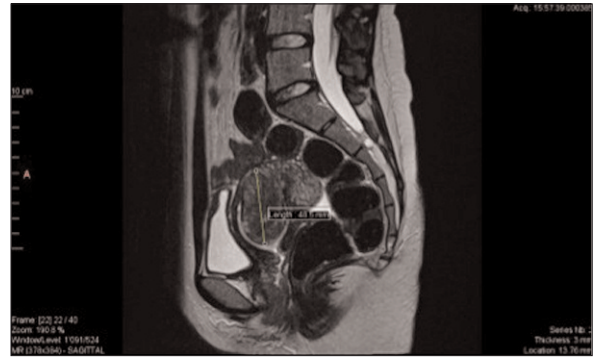

Figure 5.

lowest haemoglobin level was 60 g/l. An MRI revealed a 48×38×31 mm-sized FIGO 2-5 myoma (Figure 5. MRI T2 august 2015: myoma FIGO 2-5 of 48×38×31 mm = volume of 30 cm³). Ulipristal Acetate was prescribed to treat this anemia. Amenorrhea was not achieved. After three months, a control MRI revealed an isthmic FIGO 1 myoma of 46×35×31 mm in size that had migrated into the endometrial cavity (Figure 6. MRI T2 November 2015: myoma FIGO 1 isthmic of 46×35×31 mm which protrudes in the cavity = volume of 22 cm³). As this woman was a virgin, and she wanted to preserve this status, a complex laparoscopy was scheduled to achieve myomectomy, instead of relying on a hysteroscopic approach. One month later, during the per-operative vaginal examination, a myoma expelled through the cervix into the vagina was discovered (Figure 7. Per-operative status myoma expelled in the vagina). The surgical procedure was switched from a laparoscopic to a vaginal approach, thus entailing a risk of breaking the hymen, of which the patient was informed pre-operatively. The surgery was entirely successful.

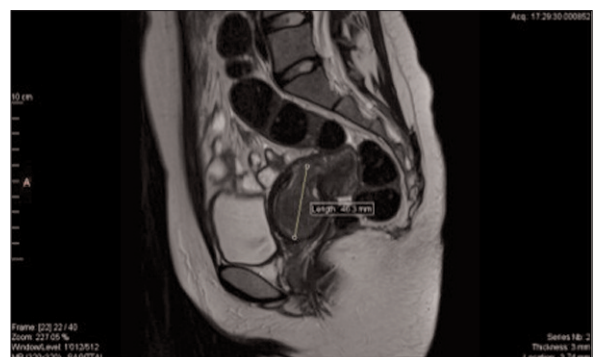


Figure 6.

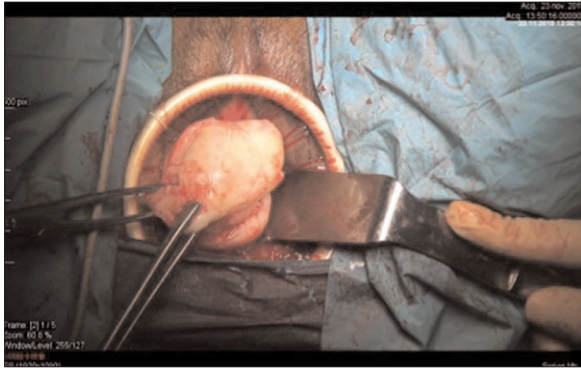


Figure 7.

Blood loss was estimated to be 250 ml, but the patient received a blood transfusion because of her low pre-operative hemoglobin level.

Discussion

Among women treated with UPA prior to surgery in our department, we observed three cases of myoma migration.

The first woman (i.e. case history No. 1) presented with a FIGO 2 myoma, which migrated in FIGO 3 after a 70% reduction in size. Initially, a hysteroscopy was planned, but the patient ultimately underwent a laparoscopy. The second woman (i.e. case history No. 2) presented with a FIGO 2 myoma, which migrated in FIGO 3 after a 55% reduction in size. Initially, a hysteroscopic myomectomy was planned, but surgery was ultimately no longer required. The third woman (i.e. case history No. 3) presented with a FIGO 2-5 myoma, which migrated in FIGO 1 after a 27% reduction in size. This patient was initially scheduled to receive a laparoscopy, but she finally benefited from a vaginal myomectomy.

To our knowledge, there is only one published case regarding myoma migration following pre-operative medical treatment with UPA²⁸. Myoma migration has, however, been described following uterine artery embolization and GNRHa treatment²⁹⁻³¹. Necrosis following artery embolization induces cytokine production, which causes myometrial contraction, and ultimately migration of the myoma. Regarding GNRHa, its anti-proliferative effect results in the reduction of the myoma volume. This decrease in size causes separation of myometrium from the adjacent en-

dometrium resulting in ischemic myoma. This leads to myometrial contraction and thus its migration.

UPA acts as a progesterone antagonist, with partial agonist activity depending on the tissue site. By blocking progesterone, which acts as a transcriptional activator, UPA increases the level of cleaved caspase-3, inducing a proapoptotic effect^{32,33}. Like GNRHa, it also inhibits proliferation of leiomyoma cells. These mechanisms induce the reduction in the size of the myoma and, therefore, its migration³⁴. UPA reduces expression of VEGF, suppressing neovascularization and cell proliferation. This mechanism leads to ischemic myoma, followed by its migration^{35,36}. UPA also reduces collagen deposition in the extracellular matrix. It can thereby impair the stability and structural integrity of myomas, thus favouring myoma migration³⁷. In our series, only submucosal myomas migrated (hybrid myoma FIGO 2-5, FIGO 2). Submucosal myoma has a smaller implantation area in the myometrium than intramural myoma. Matrix instability provoked by Ulipristal Acetate could favour myoma migration in case of submucosal myoma.

Conclusions

Our results reflect those from the literature supporting UPA treatment as efficient and safe to reduce the size of myoma. However, our series revealed an important effect that must be taken into consideration before planning a surgery with preoperative UPA treatment. We recommend precise selection of women with a detailed cartography of the myoma. Women should be informed about the possibility of perioperative conversion of surgery and a pre-operative ultrasound should be performed systematically to confirm the surgical approach.

Conflict of Interest

The Authors declare that there are no conflicts of interest.

References

- 1) WALLACH E, VLAHOS N. Uterine myomas: an overview of development, clinical features, and management. *Obstet Gynecol* 2004; 104: 393-406.

- 2) ZIMMERMANN A, BERNUIT D, GERLINGER C, SCHAEFERS M, GEPPERT K. Prevalence, symptoms and management of uterine fibroids: an international internet-based survey of 21,746 women. *BMC Womens Health* 2012; 12: 6.
- 3) LAM S, BEST S, KUMAR S. The impact of fibroid characteristics on pregnancy outcome. *Am J Obstet Gynecol* 2014; 211: 395.e1-5.
- 4) DONNEZ J, JADOU L. What are the implications of myomas on fertility? A need for debate? *Hum Reprod* 2002; 17: 1424-1430.
- 5) SRIVIDHYA S. Medical Management of fibroids. *Best Pract Res Clin Obstet Gynaecol* 2008; 22: 655--76.
- 6) STEWART E. Uterine fibroids and evidence based medicine not an oxymoron. *N Engl J Med* 2012; 366: 471-473.
- 7) MARRET H, FERNANDEZ H. Therapeutic management of uterine fibroid tumors: updated French guidelines. *Eur J Obstet Gynecol Reprod Biol* 2012; 165: 156-164.
- 8) GUPTA J, LUMSDEN M, SINHA A, HICKEY M. Uterine artery embolization for symptomatic uterine fibroids. *Cochrane Data Base Syst Rev* 2014; 12: CD005073.
- 9) MARA M, FUCIKOVA Z, MASKOVA J. Uterine fibroid embolization versus myomectomy in women wishing to preserve fertility: preliminary results of a randomised controlled trial. *Eur J Obstet Gynecol Reprod Biol* 2006; 126: 226-233.
- 10) DUHAN N. Current and emerging treatments for uterine myoma - an update. *Int J Womens Health* 2011; 3: 231-241.
- 11) PRON G, MOCARSKI E, BENNETTE J. Pregnancy after uterine embolization for leiomyomata, the Ontario multicenter trial. *Obstet Gynecol* 2005; 105: 67-76.
- 12) DONNEZ J, TATARCHUK T, BOUCHARD P, PUSCASIU L. Ulipristal acetate versus placebo for fibroid treatment before surgery. *N Engl J Med* 2012; 366: 409-420.
- 13) DONNEZ J, TOMASZEWSKI J, VAZQUEZ, FRANCISCO, BOUCHARD, PHILIPPE, LEMIESZCZUK B, LOUMAYE, ERNEST. Ulipristal acetate versus leuprolide acetate for uterine fibroids. *N Engl J Med* 2012; 366: 421-432.
- 14) KALAMPOKAS T, KAMATH M, BOUTAS I, KALAMPOKAS E. Ulipristal acetate for uterine fibroids: a systematic review and meta-analysis. *Gynecol Endocrinol* 2016; 32: 91-96.
- 15) DONNEZ J, VAZQUEZ F, TOMASZEWSKI J, NOURI K. Long term treatment of uterine fibroids with ulipristal acetate. *Fertil Steril* 2014; 101: 1565-1573.
- 16) DONNEZ J, HUDECEK R, DONNEZ O, MATULE D, ARHENDT HJ, ZATIK J, KASIOVSKIENE Z, DUMITRASCU MC, FERNANDEZ H, BARLOW DH, BOUCHARD P, FAUSER BC, BESTEL E, TERRILL P, OSTERLOH I, LOUMAYE E. Efficacy and safety of repeated use of ulipristal acetate in uterine fibroids. *Fertil Steril* 2015; 103: 519-527.
- 17) DONNEZ J, DONNEZ O, DOLMANS MM. With the advent of selective progesterone receptor modulators, what is the place of myoma surgery in current practice? *Fertil Steril* 2014; 102: 640-648.
- 18) DONNEZ J, ARRIAGADA P, DONNEZ O, DOLMANS M. Current management of myomas: the place of medical therapy with the advent of selective progesterone receptor modulators. *Curr Opin Obstet Gynecol* 2015; 27: 422-431.
- 19) BIGLIA N, CARINELLI S, MAIORANA A, D'ALONZO M, LO MONTE G, MARCI R. Ulipristal acetate: a novel pharmacological approach for the treatment of uterine fibroids. *Drug Des Devel Ther* 2014: 285-292.
- 20) BOUCHARD P, CHABBERT-BUFFET N, FAUSER BCJM. Selective progesterone receptor modulators in reproductive medicine: pharmacology, clinical efficacy and safety. *Fertil Steril* 2011; 96: 1175-1189.
- 21) CHABBERT-BUFFET N, PINTIAUX A, BOUCHARD P. The imminent dawn of SPRMs in obstetrics and gynecology. *Mol Cell Endocrinol* 2012; 358: 232-243.
- 22) BOURDET AT, LUTON D, KOSKAS M. Clinical utility of ulipristal acetate for the treatment of uterine fibroids: current evidence. *Int J Gynecol Obstet* 2015; 7: 321-330.
- 23) LO MONTE G, PIVA I, GRAZIANO A, ENGL B, MARCI R. Ulipristal acetate prior to in vitro fertilization in a female patient affected by uterine fibroids: a case report. *Eur Rev Med Pharmacol Sci* 2016; 20: 202-207.
- 24) WILLIAMS A, BERGERON C, BARLOW D, FERENCZY. Endometrial morphology after treatment of uterine fibroids with the selective progesterone receptor modulator, ulipristal acetate. *Int J Gynecol Pathol* 2012; 31: 556-569.
- 25) MUTTER G, BERGERON C, DELIGDISCH L, FERENCZY A, GLANT M, MERINO M, WILLIAMS AR, BLITHE DL. The spectrum of endometrial pathology induced by progesterone receptor modulators. *Mod Pathol* 2008; 21: 591-598.
- 26) TAFI E, SCALA C, LEONE ROBERTI U, BIZZARRI N, CANDIANI M, VENTURINI PL. Drug safety evaluation of ulipristal acetate in the treatment of uterine fibroids. *Expert Opin Drug Saf* 2015; 14: 1-13.
- 27) STUTE P, BÜRKI R, HONEGGER C, STREULI I, BITZER J, SURBEK D. Ulipristal acétate pour la thérapie de myomes (fibromes) utérins. *Avis Expert N°43 Société Suisse Gynécologie Obstétrique* 2015; 43: 1-4.
- 28) CHANTRAINE F, POISMANS G, NWACHUKU J, ELKE B, NISOLEE M. Expulsion of a uterine myoma in a patient treated with ulipristal acetate. *Clin Case Rep* 2015; 3: 240-242.
- 29) WEN L, TSENG J-Y, WANG P-H. Vaginal expulsion of a submucosal myoma during treatment with long acting gonadotropin-releasing hormone agonist. *Taiwan J Obstet Gynecol* 2006; 45: 173-175.

- 30) YU K-J, LAI C-R, SHEU M-H. Spontaneous expulsion of a uterine submucosal leiomyoma after administration of a gonadotropin releasing hormone agonist. *Eur J Obstet Gynecol Reprod Biol* 2001; 96: 223-225.
- 31) KRIPLANI A, AGARWAL N, PARUL D, BHATLA N, SAXENA AK. Prolapsed leiomyoma with severe haemorrhage after GnRH analogue therapy. *J Obstet Gynaecol* 2002; 22: 449-451.
- 32) MARUO T, MATSUO H, SAMOTO T, SHIMOMURA Y, KURACHI O, GAO Z, WANG Y, SPITZ IM, JOHANSON E. Effects of progesterone on uterine leiomyoma growth and apoptosis. *Steroids* 2000; 65: 585-592.
- 33) YUN BS, SEONG SJ, CHA DH, KIM JY, KIM M-L, SHIM JY, PARK JE. Changes in proliferating and apoptotic markers of leiomyoma following treatment with a selective progesterone receptor modulator of gonadotropin releasing hormone agonist. *Eur J Obstet Gynecol Reprod Biol* 2015; 191: 62-67.
- 34) COURTOY GE, DONNEZ J, MARBAIX E, DOLMANS MM. In vivo mechanisms of uterine myoma volume reduction with ulipristal acetate treatment. *Fertil Steril* 2015; 104: 1-9.
- 35) HAGUE S, ZHANG L, OEHLER M, MANEK S, MACKENZIE I, BICKNELL R, REES MC. Expression of the hypoxically regulated angiogenic factor adrenomedullin correlates with uterine leiomyoma vascular density. *Clin Cancer Res* 2000; 6: 2808-2814.
- 36) GENTRY C, OKOLO S, FONG L, CROW J, MACLEAN A, PERRET C. Quantification of vascular endothelial growth factor-A in leiomyomas and adjacent myometrium. *Clin Sci* 2001; 101: 691-695.
- 37) MARUO T, OHARA N, YOSHIDA S, NAKABAYASHI K, SASAKI H, XU Q, MATSUO H, SITRUK-WARE R, YAMADA H. Lessons learned from the preclinical drug discovery of asoprisnil and ulipristal for non-surgical treatment of uterine leiomyomas. *Expert Opin Drug Discov* 2011; 6: 897-911.