

Acute necrotizing pancreatitis: can tigecycline be included in a therapeutic strategy?

S. OCCHIONORELLI¹, L. MORGANTI¹, R. CULTRERA², D. ANDREOTTI¹, S. MACCATROZZO¹, L. CAPPELLARI³, R. STANO³, G. VASQUEZ³

SUMMARY: Acute necrotizing pancreatitis: can tigecycline be included in a therapeutic strategy?

S. OCCHIONORELLI, L. MORGANTI, R. CULTRERA, D. ANDREOTTI, S. MACCATROZZO, L. CAPPELLARI, R. STANO, G. VASQUEZ

Introduction. Acute necrotizing pancreatitis is a severe and life-threatening disease. Infection, which occurs in about 30% of cases, is the most feared complication. Antibiotic therapy is still discussed and there are no clear recommendation in literature. These clinical series underline the importance of having a clear antibiotic protocol, including tigecycline, in the management of acute necrotizing pancreatitis.

Clinical series. Six patients with clinical and radiological diagnosis of necrotizing acute pancreatitis are treated in Emergency Surgery Department, following a conservative management, which includes fluid resuscitation, intensive care unit and radiological monitoring, ultrasound-guided percutaneous drainage and an antibiotic treatment

protocol, that includes tigecycline. No one of the six patient undergo surgery (mean hospital stay: 44 days). In a six months follow-up all patients are alive and in good clinical conditions.

Discussion. Infection is the most important factor which determine prognosis and outcome of acute necrotizing pancreatitis. Antibiotic prophylaxis is still discussed and there are no clear antibiotic treatment guidelines in literature. Despite its side effects on pancreatic gland, tigecycline is successful in resolution of sepsis, caused by infected pancreatic necrosis.

Conclusions. Collaboration with infectiologist and a clear antibiotic protocol is fundamental to solve infected necrosis. Antibiotic treatment, set up as soon as possible, is successful in our six patients, as they recover without undergoing surgical procedures. Tigecycline offers broad coverage and efficacy against resistant pathogens for the treatment of documented pancreatic necrosis infection. However, further studies are necessary to fully understand the safety profile and efficacy of tigecycline.

KEY WORDS: Acute necrotizing pancreatitis - Infection - Antibiotic.

Introduction

Acute necrotizing pancreatitis (ANP) is a severe and life-threatening disease whose prevalence is increasing nowadays. Necrotizing pancreatitis, which is associated with an 8 to 39% rate of death, develops in approximately 20% of patients (1). A subgroup of patients with severe acute pancreatitis (SAP) has early severe acute pancreatitis or fulminant acute pancreatitis with extended pancreatic necrosis and organ failure at admission or within 72 hours. Both have a high mortality rate of 25-30 %

(2, 3). The major cause of death, next to early organ failure, is secondary infection of pancreatic or peripancreatic necrotic tissue, leading to sepsis and multiple organ failure (4, 5). Although Atlanta International Symposium on Acute Pancreatitis (6) overhauls this pathology definition, a worldwide full agreement concerning the therapeutic strategies is still lacking in antibiotic management and surgical procedure time-line. Treatment of necrotizing pancreatitis has changed: it is now accepted that sterile necrosis should be managed conservatively and the main indication for surgery is infected necrosis and abdominal compartment syndrome (ACS) (7). Infection is the most feared complication and occurs in about 30% of patients with necrotizing pancreatitis, above all in the late phase of disease (1, 8). Without radiologic, endoscopic or surgical intervention, infected necrosis leads to death in nearly every patient (9). The so-called "step-up approach" has introduced in 2006 with the "PANTER" study that consisted of percutaneous drainage, followed, if it is necessary, by minimally invasive retroperitoneal necrosectomy (10). Antibiotic therapy is still discussed

¹ Department of Morphology, Surgery and Experimental Medicine-University of Ferrara, Ferrara, Italy

² Department of Medicine, Infectious Disease Division, Sant'Anna Hospital, Ferrara, Italy

³ Department of Surgery, Emergency Surgery Service, Sant'Anna Hospital, Ferrara, Italy

Corresponding Author: Lucia Morganti, e-mail: lucymorg@hotmail.it

© Copyright 2015, CIC Edizioni Internazionali, Roma

and there are no clear recommendation (11). The use of prophylactic antibiotics in SAP is justified by the major risk of infection in patients with organ failure. Indication for starting prophylactic antibiotics should be based on clinical judgment (12). These case series underline the importance of having a clear antibiotic protocol, including tigecycline, in the management of ANP.

Clinical series

In our Emergency Surgery Department, tigecycline was included in the antibiotic protocol for treating six cases of acute necrotizing pancreatitis. Three male and three female, with an overall mean age of 62.53 years old, were admitted to our Department with clinical signs of severe acute pancreatitis: characteristic abdominal pain, neutrophil leucocytosis (mean total white blood cells: $15.98 \times 10^3/\text{mL}$; mean neutrophil: $14.46 \times 10^3/\text{mL}$), pancreatic serum enzyme increase (mean amylase: 1214,6 U/l; mean lipase: 1144,6 U/l), fever (mean body temperature 37.5°C), reactive C-proteins increase (mean values: 26 mg/dl), first signs of systemic inflammation response syndrome (SIRS) and/or multi-organ failure/dysfunctions (MOF/MODS).

All patients underwent thoracic and abdominal contrast-enhanced computed tomography (CECT) to assess acute pancreatitis severity; a further CECT scan was made also after 76-96 hours to check radiological pathology evolution, useful for further planning of the treatment strategy, as showed in literature (13) (Figures 1-3).

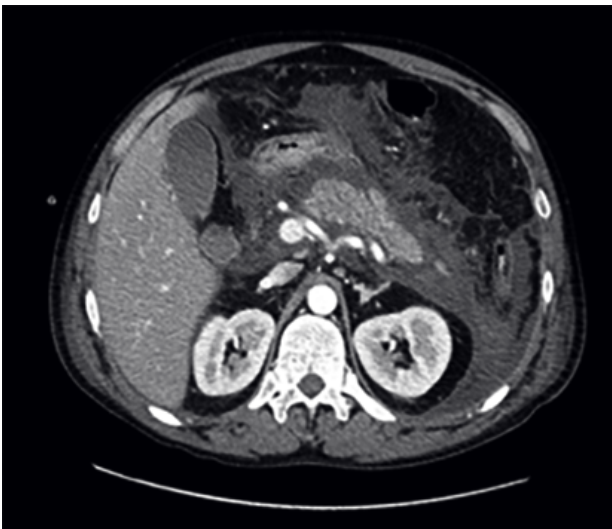


Fig. 1 - 41-years-old man: severe acute pancreatitis CT-scan image. Acute necrotizing process involves the pancreas with extensive alteration of pancreatic structure. There is a wide low density structure of the body and the head. Pancreatic lodge infarction involves celiac vascular structures and lead to initial dislocation of the duodenal C.

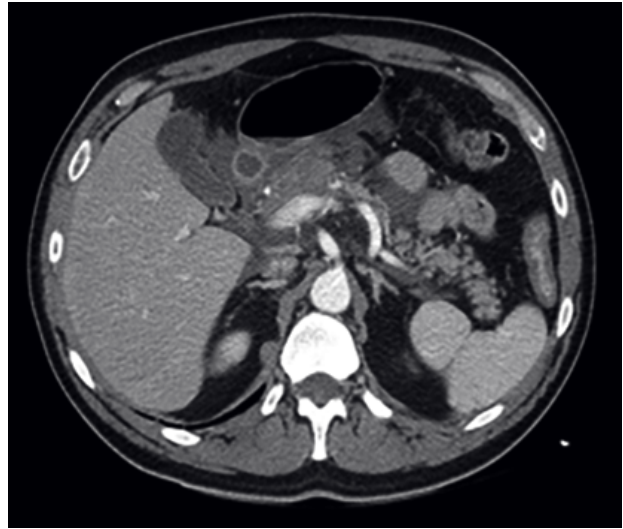


Fig. 2 - 48-years-old man: severe acute pancreatitis CT-scan image. Acute pancreatitis characterized by large area of pancreatic swelling (cephalic) which is suitable for necrotic process. This is associated with peripancreatic fluid collections partly embedding vascular branches (celiac district, mesenteric-portal system) and occupy the para-renal space and the parietocolic lodge.

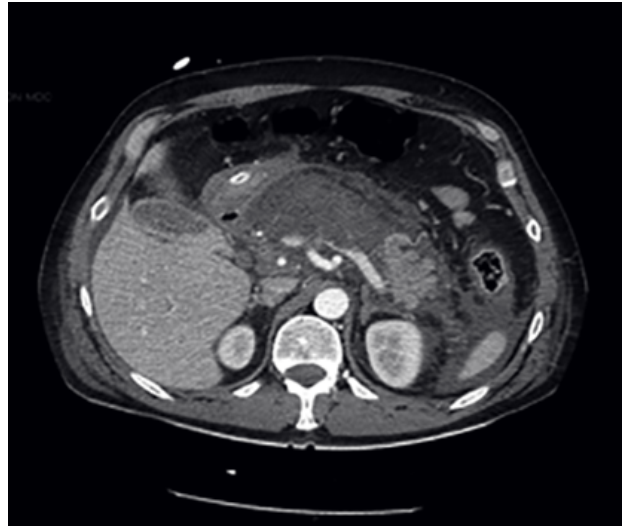


Fig. 3 - 77-years-old woman: severe acute pancreatitis CT-scan image. Pancreatic structure is almost totally changed by necrotic process. Focus on the fluid, which is spread between the bowel loops.

During the first 24-48 hours, four of the six patients were transferred to Intensive Care Unit (ICU) because of worsening of general clinical conditions and they remained there for a mean time of 19.5 days. Two of them developed SIRS, three developed MOF and only one acute renal failure. First, big amounts of liquids to restore fluid and electrolyte balance were given; all patients had a central venous catheter (CVC) for total parenteral nutrition and for checking central venous pressure (CVP).

Patients were clinically followed and blood tests, in particular white blood cells and reactive C protein, were daily monitored. In addition, blood cultures were made

in all patients when fever appeared or increased. Administration of a broad-spectrum antibiotic therapy (ampicillin/sulbactam 3g q8hr i.v. or ciprofloxacin 400 mg q12hr i.v. or levofloxacin 500 mg q12hr i.v. and/or metronidazole 500 mg q6hr i.v.) started not more than 24-48 hours from hospital admission. Four patients were also treated with ultrasound -guided percutaneous catheter drainage of intra- abdominal peripancreatic and pancreatic fluid collection to solve them and to collect fluid for further cultures. This invasive technique was taken into consideration when radiological controls showed the persistence of fluid collections in the pancreatic and peripancreatic lodge, or if this fluid was infected, or if there was infected necrotic tissue. Blood cultures were positive for *Escherichia coli*, *Staphylococcus epidermidis*, *Staphylococcus hominis*, *Enterococcus faecium*. Drained fluid cultures were positive for *Escherichia coli*, *Acinetobacter Baumannii*, *Staphylococcus epidermidis*, *Staphylococcus aureus*, *Enterococcus faecalis*. With the infectiologist, we planned an antibiotic treatment strategy that followed the increasing level of surgeon's aggressiveness in treating acute pancreatitis (Table 1).

As the first step, we administered broad spectrum antibiotics (to control SIRS and sepsis); we reached the second step if blood cultures were positive and so we administered targeted antibiotic; third step was necessary in case of pancreatic fluid, drained by US-guided percutaneous catheter drainage. Second line antibiotics treatment was set up with third generation cephalosporins (ceftriaxone 2 g qd i.v.), carbapenems (imipenem 1 g q8hr i.v.), aminoglycosides (amikacin 1 g qd i.v.) and piperacillin/tazobactam 4.5 g q8hr i.v. Antibiotic strategy switched in favour of tigecycline (loading dose 100 mg i.v. then 50 mg q12hr i.v.) after 7 to 10 days of treatment failure and in case of associated positive cultural results. We introduced tigecycline alone, or in association with antibiotics already in therapy if cultures were sensible or if clinical conditions got worse or did not change after

a week of conventional antibiotic treatment or whenever there were evidences of intra-abdominal infection. Tigecycline was administered in conventional dosage (50 mg q12hr i.v.) for a medium period of 10 days. We strictly checked every change in symptoms and laboratory index during the administration of tigecycline, aware of the known side effects. Tigecycline antibiotic treatment would be stopped in case of aggravation of pancreatitis-related symptoms. Our patients benefited from this kind of antibiotic strategy that led to a complete resolution of pancreatitis related intra-abdominal infection. It was not necessary in any patients to give up with tigecycline treatment. However, antibiotic treatment could not be separated from ultrasound- guided percutaneous drainage, which removed the infected fluid and, in this way, mitigated sepsis. No one of the six patient underwent surgery during hospital stay. The mean hospital stay was 44 days. In a six months follow-up all the patients were alive and in good clinical conditions; one patient was re-admitted for onset of intestinal fistula surgically treated. Two patients underwent elective cholecystectomy 3 to 6 months after discharge.

Discussion

Patients should be classified as having severe acute pancreatitis based on the presence of the persistent systemic inflammatory response syndrome (SIRS) and/or developing organ failure. Potential risk factors of acute pancreatitis severity are: age, serum levels of C-reactive protein and multi-organ failure onset. It should be stressed that serum amylase and lipase activities, while important in the diagnosis of "acute pancreatitis", are not of any clinical importance in defining the severity of acute pancreatitis (6, 14). In acute pancreatitis, multiple organ failure is a consequence of excessive activation of a systemic inflammatory response cascade (15). Over half of

TABLE 1 - ANTIBIOTIC TREATMENT STRATEGY. ANTIBIOTIC TREATMENT STRATEGY FOLLOWS THE INCREASING LEVEL OF SURGEON'S AGGRESSIVENESS IN TREATING ACUTE PANCREATITIS.

STEP	EVIDENCE	ANTIBIOTIC
STEP 1	WBC+Clinical Conditions	Broad spectrum
STEP 2	Positive blood cultures	Targeted
STEP 3	Drained fluid cultures	Targeted

the patients with severe pancreatitis have signs of organ dysfunction on hospital admission (16) and most of the organ dysfunctions develops within the first four days after admission (17). Over half of the deaths occur within the first week from onset of the disease, and deaths usually occur within a week after manifestation of MODS (5).

Infection is the most important factor which determines prognosis and outcome of ANP and it is present in about 30% of patients with necrotizing pancreatitis, above all in the late phase of disease (1, 8, 18-20). It is often polymicrobial and involves both aerobic and anaerobic bacteria (21). Many authors try to prove the effectiveness of antibiotic prophylaxis in acute pancreatitis: a Cochrane Review of Villatoro et al. includes seven randomised controlled trials (404 patients) in which pancreatic necrosis is proven by CT scan. The results still appear not so clear: intravenous antibiotic prophylaxis is indeed associated with significantly decreased mortality in patients with pancreatic necrosis, but there is no significant reduction in the rates of infected pancreatic necrosis. Finally, this review states that beta lactam agents (i.e. imipenem) is associated to a significant decrease in pancreatic infection. However, further better designed studies are needed if the use of antibiotic prophylaxis is to be recommended (22).

A more recent review of 2009 states that antibiotic prophylaxis of SAP does not reduce mortality or protect against infected necrosis, or leads to surgical intervention (23).

According to the last guidelines about acute pancreatitis treatment the intravenous antibiotic prophylaxis is not recommended for the prevention of infectious complications in acute pancreatitis (grade 1B, strong agreement) (24, 25). Otherwise, in patients with infected necrosis, antibiotics known to penetrate pancreatic necrosis, such as carbapenems, quinolones, and metronidazole, may be useful in delaying or sometimes totally avoiding intervention, thus decreasing morbidity and mortality (24). Some authors declare that imipenem (carbapenems) is the drug of choice for single-drug prophylaxis in acute necrotizing pancreatitis (26). However, there are no clear recommendation: trials have not provided evidence that prophylactic antibiotic are effective otherwise they have not proved that they are not effective (11).

Tigecycline is the first member of the glycylicycline class of antimicrobials. It was approved in June 2005 by US Food and Drug Administration (FDA) for the treatment of complicated skin and skin-structure infections (cSSSIs) and complicated intra-abdominal infections caused by susceptible Gram-positive, Gram-negative and anaerobic organisms. It has activity towards methicillin-resistant *Staphylococcus aureus*, vancomycin-resistant enterococci; concerning the intra-abdominal infection, it is active toward *Citrobacter freundii*, *Enterobacter cloacae*, *Escherichia coli*, *Klebsiella oxytoca*, *Klebsiella*

pneumoniae, *Enterococcus faecalis*, *Staphylococcus aureus*, *Streptococcus anginosus*, *Bacteroides fragilis*, *Bacteroides thetaiotaomicron*, *Bacteroides uniformis*, *Bacteroides vulgatus*, *Clostridium perfringens*, e *Peptostreptococcus micros*. Moreover, it is good in penetrating necrotic pancreatic tissue (27).

Recently, some authors pay attention on tigecycline-induced pancreatitis, trying to describe the possible pathogenesis and some clinical cases about this topic are been published (28-32). On the other side, McGovern presented a study that identified hospitalized subjects who developed pancreatitis in Phase 3 and 4 tigecycline trials: only 0.24% of 3,788 tigecycline-treated patients developed pancreatitis. Tigecycline-induced acute pancreatitis is still a rare and under study phenomenon and it is considered an uncommon event, with an occurrence < of 1% (33). Because of the structural similarity between tigecycline and tetracycline, it is possible that the same mechanism for tetracycline-induced pancreatitis could be the rationale for the episode of pancreatitis. None has clearly explained the exact mechanism of this reaction. Tetracycline induces hypertriglyceridemia, which cause pancreatitis (34). Elmore and Rogger hypothesized that tetracycline block protein synthesis by disrupting the uptake of aminoacyl-transfer RNA on 30S ribosomal units. This results in accrual of triglycerides that precipitates an episode of pancreatitis (35).

Tigecycline is a derivative of tetracycline, and the two drugs have significant structural similarities, therefore it is quite plausible that the tigecycline molecule may react with the 30S ribosomal units, via the mechanism as tetracycline molecule, to precipitate an acute episode of pancreatitis (31).

High frequency of exposure to other medications associated with pancreatitis occurred in tigecycline: prior and concomitant medications should be taken into consideration, but may not discriminate those patients who will develop pancreatitis (36).

Conclusions

The management of acute necrotizing pancreatitis is a challenge for surgeons and needs a multidisciplinary approach. Surgeon monitors patients' clinical conditions and intervenes in case of complications (haemorrhages, abdominal compartment syndrome, infected necrosis impossible to treat with percutaneous drainage) (7).

Collaboration with infectiologist and a clear antibiotic protocol, which is tailored to patients' clinical condition, is fundamental to solve infected necrosis. The antibiotic treatment set up as soon as possible was successful in our six patients, as they recovered without undergoing any surgical procedures. So we agree with Leppäniemi et al., stating that indication for starting prophylactic an-

tibiotics should be based on clinical judgment (12).

It is important to search for involved pathogens with blood and fluids cultures, drained by ultrasound - guided percutaneous catheters, as antimicrobial treatment should not be continued without evidence of infection provided by bacterial growth on culture (1). When such evidences exist, appropriate antibiotic therapy should be guided by the result of sensitivity testing in accordance with critical care guidelines (27).

Due to the raising of nosocomial bacterial agent resistance to carbapenems antibiotics (37, 38), we try using tigecycline as an alternative to these.

In our patients, tigecycline has been safe and successful in treating infected necrotizing pancreatic fluid collection; the therapeutic success is microbiologically docu-

mented, and patients rapidly improve with the use of tigecycline, with reduction of complications. In literature, there are evidences about the efficacy of using tigecycline in treating complex intra-abdominal infection after acute pancreatitis complicated by intra-abdominal abscess. This is a new drug offering broad coverage and efficacy against resistant pathogens, and it can be added to clinical therapeutic arsenal (39). However, large trials and multicentric studies are still necessary to fully understand the safety profile and efficacy of tigecycline.

Disclosure statement

The Authors declare that they have no competing interests.

References

1. Banks PA, Freeman ML, Practice Parameters Committee of the American College of Gastroenterology. Practice guidelines in acute pancreatitis. *Am J Gastroenterol.* 2006;101(10):2379-400.
2. Whitcomb DC. Acute pancreatitis. *N Engl J Med.* 2006;354(20):2142-50.
3. Isemann R, Rau B, Beger HG. Early severe acute pancreatitis: characteristics of a new subgroup. *Pancreas.* 2001;22(3):274-8.
4. Bradely EL 3rd. A clinically based classification system for acute pancreatitis. Summary of the International Symposium on Acute Pancreatitis, Atlanta, Ga, September 11 through 13, 1992. *Arch Surg.* 1993;128(5):586-90.
5. Mole DJ, Olabi B, Robinson V, et al. Incidence of individual organ dysfunction in fatal acute pancreatitis: analysis of 1024 death records. *HPB (Oxford)* 2009;11(2):166-70.
6. Banks PA, Bollen TL, Dervenis C, et al. Classification of acute pancreatitis - 2012: revision of the Atlanta classification and definitions by international consensus. *Gut.* 2013;62(1):102-11.
7. Nathens AB, Curtis JR, Beale RJ, et al. Management of the critical ill patient with severe acute pancreatitis. *Crit Care Med.* 2004;32(12):2524-36.
8. Besselink MG, van Santvoort HC, Boermeester MA, et al. Timing and impact of infections in acute pancreatitis. *Br J Surg.* 2009;96(3):267-73.
9. Van Santvoort HC, Bakker OJ, Bollen TL, et al. A conservative and minimally invasive approach to necrotizing pancreatitis improves outcome. *Gastroenterology.* 2011;141(4):1254-63.
10. Besselink MG, van Santvoort HC, Nieuwenhuijs VB, et al. Minimally invasive 'step-up approach' versus maximal necrosectomy in patients with acute necrotizing pancreatitis (PANTER trial): design and rationale of a randomised controlled multicenter trial [ISRCTN13975868]. *BMC Surgery.* 2006;6:6.
11. Imrey PB, Law R. Antibiotic prophylaxis for severe acute pancreatitis. *Am J Surg.* 2012;203(4):556-7.
12. Leppäniemi A, Mentula P. Position paper: timely interventions in severe acute pancreatitis are crucial for survival. *World J Emerg Surg.* 2014;9(1):15.
13. Balthazar EJ, Freeny PC, vanSonnenberg E. Imaging and intervention in acute pancreatitis. *Radiology.* 1994;193:297-306.
14. Dellinger EP, Forsmark CE, Layer P, et al. Determinant-based classification of acute pancreatitis severity: an international multidisciplinary consultation. *Ann Surg.* 2012;256(6):875-80.
15. Mayer J, Rau B, Gansauge F, et al. Inflammatory mediators in human acute pancreatitis: clinical and pathophysiological implications. *Gut.* 2000;47(4):546-52.
16. Buter A, Imrie CW, Carter CR, et al. Dynamic nature of early organ dysfunction determines outcome in acute pancreatitis. *Br J Surg.* 2002;89:298-302.
17. Mentula P, Kylänpää-Bäck ML, Kempainen E, et al. Decreased HLA (human leucocyte antigen)-DR expression on peripheral blood monocytes predicts the development of organ failure in patients with acute pancreatitis. *Clin Sci.* 2003;105(4):409-17.
18. Isenmann R, Rau B, Berger HG. Bacterial infection and extent of necrosis are determinants of organ failure in patients with acute necrotizing pancreatitis. *Br J Surg.* 1999;86(8):1020-4.
19. Gloor B, Müller CA, Wormi M, et al. Late mortality in patients with severe acute pancreatitis. *Br J Surg.* 2001;88(7):975-9.
20. Beger HG, Rau B, Mayer J, et al. Natural course of acute pancreatitis. *World J Surg.* 1997;21:130-5.
21. Beger HG, Bittner R, Block S, et al. Bacterial contamination of pancreatic necrosis. A prospective clinical study. *Gastroenterology.* 1986;91(2):433-8.
22. Villatoro E, Mulla M, Larvin M. Antibiotic therapy for prophylaxis against infection of pancreatic necrosis in acute pancreatitis. *Cochrane Database of Systematic Reviews.* 2010; Issue 5. Art. No.: CD002941.
23. Jafri NS, Mahid SS, Idstein SR, et al. Antibiotic prophylaxis is not protective in severe acute pancreatitis: a systematic review and meta-analysis. *Am J Surg.* 2009;197:806-13.
24. Tenner S, Baillie J, DeWitt J, et al; American College of Gastroenterology. American College of Gastroenterology Guideline: management of Acute Pancreatitis. *Am J Gastroenterol.* 2013;108(9):1400-15.
25. Working Group IAP/APA Acute Pancreatitis Guidelines. IAP/APA evidence-based guidelines for the management of acute pancreatitis. *Pancreatol.* 2013;13:e1-e15.
26. Bassi C, Falconi M, Talamini G, et al. Controlled Clinical Trial of Pefloxacin Versus Imipenem in Severe Acute Pancreatitis. *Ga-*

- stroenterology. 1998;115(6):1513-7.
27. Dellinger RP, Carlet JM, Masur H, et al. Surviving Sepsis Campaign guidelines for management of severe sepsis and septic shock. *Crit Care Med.* 2004;32(3):858-73.
 28. Hung WY, Kogelman L, Volpe G, et al. Tigecycline-induced acute pancreatitis: case report and literature review. *Int J Antimicrob Agents.* 2009;34(5):486-9.
 29. Gilson M, Moachon L, Jeanne L, et al. Acute pancreatitis related to tigecycline: case report and review of the literature. *Scand J Infect Dis.* 2008;40:681-3.
 30. Lipshitz J, Kruh J, Cheung P, et al. Tigecycline-induced pancreatitis. *J Clin Gastroenterol.* 2009;43:93.
 31. Mascarello M, Papa G, Arnez ZM, et al. Acute necrotizing pancreatitis related to tigecycline. *J Antimicrob Chemother.* 2012;67(5):1296-7.
 32. Marot JC, Jonckheere S, Munyentwali H, et al. Tigecycline-induced acute pancreatitis: about two cases and review of the literature. *Acta Clin Belg.* 2012;67(3):229-32.
 33. McGovern PC, Wible M, Korth-Bradley JM, et al. Pancreatitis in tigecycline Phase 3 and 4 clinical studies. *J Antimicrob Chemother.* 2014;69(3):773-8.
 34. Marshall SR. Tigecycline-induced pancreatitis. *Hosp Pharm.* 2009;44:239-41.
 35. Elmore MF, Rogge JD. Tetracycline-induced pancreatitis. *Gastroenterology.* 1981;81(6):1134-6.
 36. Badalov N, Baradaran R, Iswara K, et al. Drug-Induced Acute Pancreatitis: An Evidence-Based Review. *Clin Gastroenterol Hepatol.* 2007;5(6):648-61.
 37. Corbella X, Montero A, Pujol M, et al. Emergence and Rapid Spread of Carbapenem Resistance during a Large and Sustained Hospital Outbreak of Multiresistant *Acinetobacter baumannii*. *J Clin Microbiol.* 2000;38(11):4086-95.
 38. Deshpande P, Rodrigues C, Shetty A, et al. New Delhi Metallo- β lactamase (NDM-1) in Enterobacteriaceae: Treatment options with Carbapenems Compromised. *J Assoc Physicians India.* 2010;58:147-9.
 39. Taccone FS, Rodriguez-Villalobos H, De Backer D, et al. Successful treatment of septic shock due to pan-resistant *Acinetobacter baumannii* using combined antimicrobial therapy including tigecycline. *Eur J Clin Microbiol Infect Dis.* 2006;25(4):257-60.
-