

Recurrent myocarditis in a patient with active ulcerative colitis: a case report and review of the literature

Giacomo Caio ,^{1,2} Lisa Lungaro ,^{1,3} Fabio Caputo,^{1,3} Maria Muccinelli,³ Maria Caterina Marcello,³ Eleonora Zoli,³ Umberto Volta,⁴ Roberto De Giorgio,¹ Giorgio Zoli^{1,3}

To cite: Caio G, Lungaro L, Caputo F, *et al.* Recurrent myocarditis in a patient with active ulcerative colitis: a case report and review of the literature. *BMJ Open Gastro* 2021;**8**:e000587. doi:10.1136/bmjgast-2020-000587

GC and LL are joint first authors.

Received 17 December 2020
Revised 27 January 2021
Accepted 2 February 2021

ABSTRACT

Inflammatory bowel diseases such as ulcerative colitis (UC) may be complicated by several extraintestinal manifestations. These involve joints, skin, eyes and less commonly lungs and heart. Myocarditis may result from the toxic effect of drugs (ie, mesalazine) commonly used for the treatment of UC or due to infections (eg, Coxsackieviruses, enteroviruses, adenovirus). Here, we report a case of a 26-year old man affected by UC and complicated by two episodes of myocarditis. Both episodes occurred during two severe exacerbations of UC. However, in both cases the aetiology of myocarditis remains uncertain being ascribable to extraintestinal manifestation, drug toxicity or both.

than Crohn's disease patients.⁷ In addition, in patients with IBD myocarditis could be triggered by drugs currently used to treat this condition^{8–19} such as mesalazine (MSZ) or biological agents,²⁰ and in newly diagnosed IBD.²¹ Last but not least, Coxsackie viruses, Parvovirus B19, Adenoviruses and enteroviruses can be aetiological agents for myocarditis.

Here, we report a clinical case of a young man affected by UC who had two episodes of myocarditis.

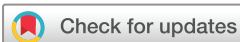CASE REPORT

A 26-year-old male patient was admitted to our Internal Medicine Unit of SS Annunziata Hospital in Cento (Ferrara, Italy) in July 2018 because of fever, bloody diarrhoea (up to 10 bowel movements per day) and abdominal pain. His medical history reported a previous diagnosis of pancolitis in July 2017 successfully treated with oral MSZ (4.8 g/day) and beclomethasone (5 mg/day). The patient had no cardiovascular risk factors. On admission, laboratory tests showed an increase in white cell count (WCC) ($18.28 \times 10^9/L$; normal value (n.v.): $4.00–11.00 \times 10^9/L$), C reactive protein (CRP) (8.51 mg/dL; n.v.: <0.5 mg/dL) and faecal calprotectin (4763 mg/kg; n.v.: <50 mg/kg). During the hospitalisation, the patient reported several episodes of severe chest pain associated with dyspnoea with no ECG abnormalities. Due to the persistence of these episodes, the patient was tested for troponin I (TnI) that turned to be positive (0.24 ng/mL; n.v.: <0.04 ng/mL). Echocardiography showed a hypokinetic area of the apical anterior aspect of the myocardium with a reduced ejection fraction (50%). Thus, a cardiac MRI was performed. According to Lake Louis Criterion, cardiac MRI, with at least 2 (oedema and necrosis) positive criteria, confirmed a diagnosis of myocarditis (figure 1A). The patient was tested for common infective causes of

INTRODUCTION

Inflammatory bowel diseases (IBD), such as ulcerative colitis (UC) and Crohn's disease, are chronic inflammatory intestinal disorders, characterised by alternating periods of remission and relapse. It is well known that many factors including genetics, immune system, environment and gut microbiome may contribute to the onset of IBD.^{1–4} The incidence of IBD is increasing worldwide with 6,8 million cases in 2017.⁵

Moreover, IBD can be associated with several extra-intestinal manifestations, mainly during acute exacerbations, in up to 30% of patients.⁶ Extraintestinal complications of IBD include joints (ankylosing spondylitis and spondyloarthropathies), eyes (uveitis), skin (pyoderma gangrenosum and erythema nodosum) and less commonly lungs (pleuritis) and heart (pericarditis and myocarditis) disorders.⁶ Myocarditis is a rare extraintestinal complication of IBD with a reported incidence of 6 cases over 15 000 patients.⁷ Interestingly, the incidence of myocarditis was slightly higher among patients with IBD compared with the general population.² Despite rare, cardiac extraintestinal manifestations, such as pericarditis and myocarditis, are more commonly reported to occur in UC



© Author(s) (or their employer(s)) 2021. Re-use permitted under CC BY-NC. No commercial re-use. See rights and permissions. Published by BMJ.

¹Department of Translational Medicine, University of Ferrara, Ferrara, Italy

²Mucosal Immunology and Biology Research Center, Harvard Medical School, Boston, Massachusetts, USA

³Department of Internal Medicine, SS. Annunziata Hospital, Cento, University of Ferrara, Ferrara, Italy

⁴Department of Medical and Surgical Sciences (DIMEC), University of Bologna, Bologna, Italy

Correspondence to
Professor Giorgio Zoli;
giorgio.zoli@unife.it

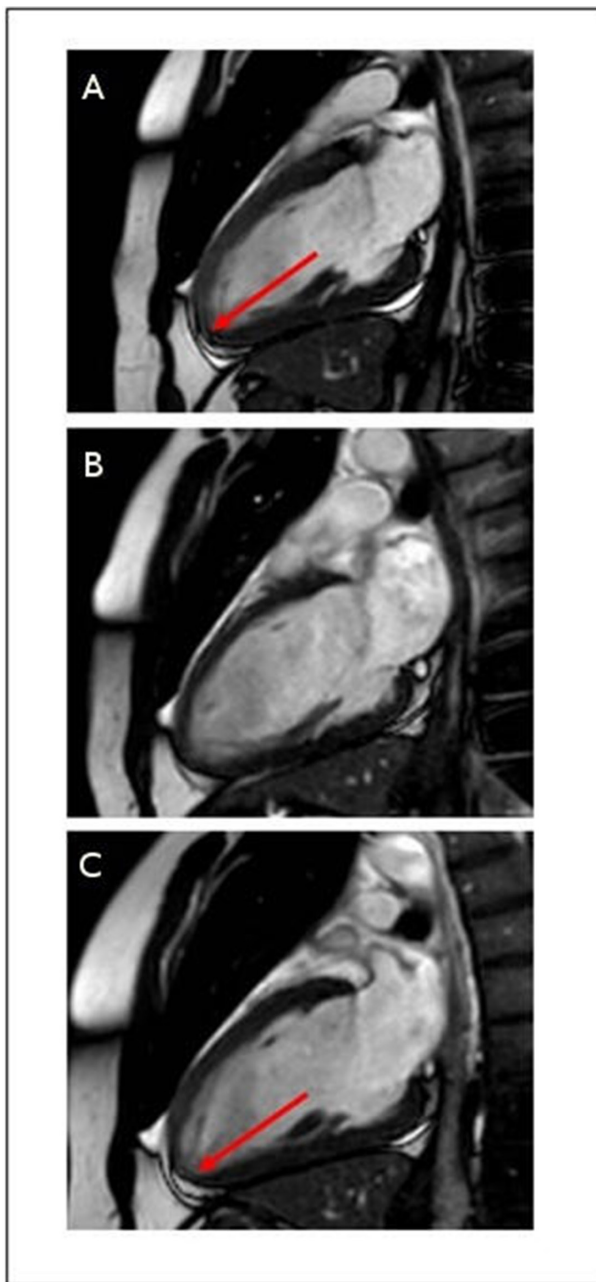


Figure 1 (A) Cardiac MRI showing myocardial oedema of the apical anterior and septal site compatible with myocarditis (red arrow); (B) the oedema previously reported in the left ventricle was no longer detectable. Some interstitium/myocellular abnormalities, compatible with myocarditis, are present in the apical lateral site; (C) picture illustrating a small and nuanced area of oedema in the apical lateral site with subepicardial localisation (red arrow), compatible with a recent inflammation.

myocarditis. Stool examination for Adenovirus and bacteria (*Shigella*, *Salmonella*, *Campylobacter*, *Escherichia coli* O157h7, and *Yersinia enterocolitica*) resulted negative. Specific viral serological antibodies resulted negative: IgG anti-Coxsackie B virus was 2.4 U/mL (n.v.: <11 U/mL; positive >15 U/mL), and IgM anti-Coxsackie B virus 6.3 U/mL (n.v.:<10 U/mL; positive >15 U/mL), IgM anti-Herpes simplex 1 and 2 was 0.53 (n.v.: <0.9; positive >1.1), and IgM anti-Herpes zoster

0.26 (n.v.: <0.9; positive >1.1). Thus, these data led us to think that myocarditis was attributed to MSZ and the treatment was shifted to azathioprine (AZA) 150 mg/day associated with methylprednisolone 1 mg/kg/day for 7 days, tapered down until discontinuation. This therapeutic approach promoted remission of UC and troponin I (TnI) normalisation within 7 days. The clinical picture and the lab tests improved (WCC: $16.98 \times 10^3/\mu\text{L}$; CRP: 0.21 mg/dL; TnI: 0.01 ng/L; faecal calprotectin: 3213 mg/kg) and the patient was discharged. One month later (September 2018), a colonoscopy revealed a sub-acute ulcerative pancolitis with Mayo score 1.^{5 22–24} In December 2018, a follow-up cardiac MRI documented the resolution of myocarditis (figure 1B), and the echocardiography revealed the normalisation of the ventricular ejection fraction (68%).

In July 2019, due to a new exacerbation (acute proctosigmoiditis; Mayo 3) AZA treatment was discontinued, and vedolizumab was started (300 mg intravenous every 8 weeks). A month later (August 2019), the patient was re-hospitalised because of the occurrence of symptom relapse characterised by bloody diarrhoea, tachycardia and chest pain with an increase of high-sensitive TnI (358 ng/L) without ECG abnormalities. The patient was investigated for the third time with a cardiac MRI showing a new inflammatory lesion suggestive of myocarditis (figure 1C). A second diagnosis of myocarditis was established, certainly unrelated to MSZ since this drug was discontinued 1 year before. During the hospitalisation the patient was treated with intravenous methylprednisolone 1 mg/kg/day for 7 days associated with vedolizumab. Intestinal symptoms improved along with a reduction of the inflammatory markers: WBC from 15.19 to $9.36 \times 10^3/\mu\text{L}$; CRP from 3.21 to 0.83 mg/dL; TnI from 358 to 27 ng/L. At discharge, the treatment regimen included intravenous vedolizumab 300 mg every 8 weeks, methylprednisolone 32 mg/day (tapered down until complete discontinuation), topical beclometasone 3 mg/day, bisoprolol 2.5 mg/day and ramipril 5 mg/day. A follow-up endoscopy (January 2020) showed ulcerative proctosigmoiditis with mild endoscopic activity, Mayo score 1. The patient is currently well and follows a therapy with intravenous vedolizumab 300 mg every 8 weeks, bisoprolol 2.5 mg and ramipril 5 mg, both on a daily basis.

DISCUSSION

UC is often accompanied by extra-intestinal manifestations as anaemia, arthropathy, metabolic bone abnormalities, cutaneous diseases (erythema nodosum and pyoderma gangrenosum), ocular (episcleritis and uveitis), hepatobiliary diseases (primary sclerosing cholangitis, pericholangitis, steatosis, chronic hepatitis, cirrhosis and gallstone formation), and less commonly, cardiovascular complications.²⁵ However, cardiac manifestations can occur with a higher frequency than what it is clinically documented, as they may remain undiagnosed.⁷ Up to one-third of patients with IBD, particularly those with UC,⁷ can develop myocarditis or pericarditis with a higher rate of complications, and fatal outcomes in comparison with patients affected by Crohn's

disease.²⁶ Therefore, despite myocarditis has been considered a rare extra-intestinal manifestation of UC, this condition has been documented in many literature reports.^{1 27–29} Cardiac manifestations in UC may be overlooked because of non-specific symptoms (eg, fatigue, dyspnoea and chest pain), which either resolve without any specific treatment or rapidly progress up to more severe heart complications, for example, cardiogenic shock.³⁰

MSZ is a 5-aminosalicylic acid agent usually prescribed as a first-line therapy in the treatment of UC.³¹ MSZ mechanism of action has not been completely understood. However, it is thought that it reduces inflammation by inhibiting the cyclooxygenase enzyme and the peroxisome proliferator-activated receptor gamma cascade, thus reducing the proinflammatory signalling pathway of the nuclear factor κ B.^{10 12} Along with the most common MSZ-evoked side effects (eg, dyspepsia, pancreatitis, blood dyscrasias, nausea and headache), this drug can trigger the onset of cardiac inflammation, such as pericarditis, myocarditis and coronary vasculitis.⁹ The mechanisms leading to cardiotoxicity have not been elucidated yet; however, different theories have been proposed: (1) MSZ may increase the eosinophil-stimulating cytokines, promoting a hypersensitivity reaction; (2) a hypersensitivity reaction triggered by antibodies directed against the drug and a cross-reacting with the cardiac tissue; (3) an immunoglobulin E-mediated allergic reaction promoted by its toxicity on the myopericardium.¹² MSZ induced myocarditis usually appears within 4 weeks from the beginning of the treatment, but concomitant corticosteroid use could delay the onset of the cardiotoxicity. MSZ-induced myocarditis has been reported in literature both in the treatment of UC,^{8–16} Crohn's disease^{17–19} and in newly diagnosed IBD.²¹ Up to now, more than 51 cases of MSZ induced myocarditis have been reported.³²

The Food and Drug Administration has approved tumour necrosis factor-alpha (TNF- α) blockers (such as infliximab, adalimumab and golimumab) for the treatment of UC, and the use of these drugs has been associated with worsening of congestive heart failure.²⁰ Namely, cardiomyopathy has been reported as a severe adverse reaction of adalimumab,^{33 34} myocarditis and perimyocarditis have been ascribed to infliximab,^{35–37} and heart failure onset or worsening has been specified on the safety information of golimumab as new onset or worsening of congestive heart failure have been reported with this compound.³⁸ Although a cardiac death has been reported in a 66-year-old male 14 days after the first induction dose of vedolizumab (an integrin receptor antagonist currently used to treat UC), it should be emphasised that this patient had a 2-year history of chronic ischaemic heart disease,³⁹ making unlikely that this drug exerted a toxic effect. In this line, the safety of vedolizumab has been well documented both in naive or in patients previously treated with anti-TNF- α agent,^{40–43} and in studies with a long-term follow-up (up to 5 years).^{40 44–47}

Based on the data emerged by our case report, the first episode of myocarditis could be attributable to MSZ therapy even though it is not possible to rule out a previously misdiagnosed extra-intestinal manifestation of UC perhaps triggered

by MSZ. On the other hand, the second episode was likely an extraintestinal manifestation of UC, since vedolizumab treatment was not discontinued at time of the diagnosis of myocarditis, which progressively resolved with corticosteroid use and never relapsed.

This case reports a patient with recurrent extensive UC flares. On two independent situations separated by a period of more than 1 year, he presented with severe chest pain, elevated TnI levels and MRI changes typical of myocarditis. Treatment with steroids led to rapid resolution. The first episode appeared during a severe pancolitis exacerbation that was initially treated with MSZ. Because myocarditis has been attributed to MSZ, its use was terminated. Moreover, even the second episode of myocarditis occurred during a disease flare when endoscopic changes were severe and extensive. Complete resolution of cardiac and colonic findings with steroids suggested that immune factors played a role in both recurrent disorders. On the other hand, myocarditis could also occur during acute intestinal diseases due to increased intestinal permeability.⁴⁸ This is the case of enteroviral infections, in which products of the enteroviral genome (eg, viral protease 2A) can spread systemically through the leaky gut and cleave host proteins, like dystrophin, causing cardiac dysfunction.^{48 49} Further studies to elucidate molecular mechanisms associated with these clinical phenomena are needed. We could speculate that even the very first episode of myocarditis was not drug related since the toxicity usually appears within 4 months from MSZ starting and the patient was at the twelfth month of therapy. From this point of view, the hypothesis of an extraintestinal manifestation related to disease flare and increased intestinal permeability is suggestive but cannot be proved.

Finally, it is worth noting that, regardless the aetiology of myocarditis in patients affected by UC, a timely diagnosis of cardiac complication is crucial to avoid life-threatening complications often aggravated by fatal outcome.²⁹

Acknowledgements We would like to acknowledge the Registered Nurse, Dr. Daniela Mazzoni, for her technical help.

Contributors GC, LL and FC: drafting the manuscript, literature review and critical revision of the final manuscript. GC, GZ and RDG: conceptualisation and critical revision of the final manuscript. EZ, MM, MCM and UV: involved in patient care and critical revision of the final manuscript. All authors approved the final version of the article and are accountable for its content. RDG and GZ share last authorship.

Funding GC, GZ and RDG are supported by research (F.A.R.) funds from University of Ferrara.

Competing interests None declared.

Patient consent for publication Not required.

Provenance and peer review Not commissioned; externally peer reviewed.

Data availability statement Data are available on reasonable request.

Open access This is an open access article distributed in accordance with the Creative Commons Attribution Non Commercial (CC BY-NC 4.0) license, which permits others to distribute, remix, adapt, build upon this work non-commercially, and license their derivative works on different terms, provided the original work is properly cited, appropriate credit is given, any changes made indicated, and the use is non-commercial. See: <http://creativecommons.org/licenses/by-nc/4.0/>.

ORCID iDs

Giacomo Caio <http://orcid.org/0000-0002-4244-4529>

Lisa Lungaro <http://orcid.org/0000-0001-9053-5671>

REFERENCES

- 1 Gruenhagen B, Alraies MC, Vakil KP, *et al.* Ulcerative colitis-induced myocarditis. *BMJ Case Rep* 2014;2014. doi:10.1136/bcr-2014-204818. [Epub ahead of print: 22 May 2014].
- 2 Ricci MA, Epstein I. 2053 Mesalamine-induced myocarditis in a patient with newly diagnosed IBD. *Am J Gastroenterol* 2019;114:S1149.
- 3 Dias T, Santos A, Santos RM, *et al.* Recurrent mesalazine-induced myopericarditis in a patient with ulcerative colitis. *BMJ Case Rep* 2019;12:e228037.
- 4 Khanna D, McMahon M, Furst DE. Anti-Tumor necrosis factor alpha therapy and heart failure: what have we learned and where do we go from here? *Arthritis Rheum* 2004;50:1040–50.
- 5 Schroeder KW, Tremaine WJ, Ilstrup DM. Coated oral 5-aminosalicylic acid therapy for mildly to moderately active ulcerative colitis. A randomized study. *N Engl J Med* 1987;317:1625–9.
- 6 Rutgeerts P, Sandborn WJ, Feagan BG, *et al.* Infliximab for induction and maintenance therapy for ulcerative colitis. *N Engl J Med Overseas Ed* 2005;353:2462–76.
- 7 Sørensen HT, Fonager KM. Myocarditis and inflammatory bowel disease. A 16-year Danish nationwide cohort study. *Dan Med Bull* 1997;44:442–4.
- 8 Asadi J, Bhandari SS, Ahmed N. Mesalazine-induced myopericarditis in a patient with ulcerative colitis. *Echo Res Pract* 2018;5:K1–5.
- 9 Fleming K, Ashcroft A, Alexakis C, *et al.* Proposed case of mesalazine-induced cardiomyopathy in severe ulcerative colitis. *World J Gastroenterol* 2015;21:3376–9.
- 10 Perez-Colon E, Dadlani GH, Wilmot I, *et al.* Mesalamine-induced myocarditis and coronary vasculitis in a pediatric ulcerative colitis patient: a case report. *Case Rep Pediatr* 2011;2011:1–5.
- 11 Taha ME, Abdalla A, Al-Khafaji J, *et al.* Mesalamine-induced myopericarditis: a case report and literature review. *Cardiol Res* 2019;10:59–62.
- 12 Okoro KU, Roby MD, Bankole AA. Myocarditis secondary to Mesalamine-Induced cardiotoxicity in a patient with ulcerative colitis. *Case Rep Med* 2018;9813893.
- 13 Haq MI, Ahmed S, Pasha W, *et al.* Mesalazine-Induced cardiotoxicity. *J Rare Disord Diagn Ther* 2019;4:24.
- 14 Stelts S, Taylor MH, Nappi J, *et al.* Mesalamine-associated hypersensitivity myocarditis in ulcerative colitis. *Ann Pharmacother* 2008;42:904–5.
- 15 Radhakrishnan ST, Mohanaruban A, Hoque S. Mesalazine-induced myocarditis: a case report. *J Med Case Rep* 2018;12:44.
- 16 Buckholz A, Shen NT, Gupta V, *et al.* Myocarditis in a patient with ulcerative colitis: an uncommon but important manifestation of disease or drug effect. *American Journal of Gastroenterology* 2017;112:S1104–5.
- 17 García-Ferrer L, Estornell J, Palanca V. Myocarditis by mesalazine with cardiac magnetic resonance imaging. *Eur Heart J* 2009;30:1015.
- 18 Merceron O, Bailly C, Khalil A, *et al.* Mesalamine-induced myocarditis. *Cardiol Res Pract* 2010;201010.4061/2010/930190. [Epub ahead of print: 13 Sep 2010].
- 19 Ibrahim A, Khalil C, Megaly M, *et al.* Mesalamine-induced myocarditis in a young athlete: can He run again? *Cureus* 2019;11:e3978.
- 20 Khanna D, McMahon M, Furst DE. Anti-tumor necrosis factor alpha therapy and heart failure: what have we learned and where do we go from here? *Arthritis Rheum* 2004;50:1040–50.
- 21 Ricci MA, Epstein I. 2053 Mesalamine-induced myocarditis in a patient with newly diagnosed IBD. *Am J Gastroenterol* 2019;114:S1149.
- 22 Rutgeerts P, Sandborn WJ, Feagan BG, *et al.* Infliximab for induction and maintenance therapy for ulcerative colitis. *N Engl J Med* 2005;353:2462–76.
- 23 Dhandra AD, Creed TJ, Greenwood R, *et al.* Can endoscopy be avoided in the assessment of ulcerative colitis in clinical trials? *Inflamm Bowel Dis* 2012;18:2056–62.
- 24 Ungaro R, Mehandru S, Allen PB, *et al.* Ulcerative colitis. *Lancet* 2017;389:1756–70.
- 25 Magro F, Gionchetti P, Eliakim R, *et al.* Third European evidence-based consensus on diagnosis and management of ulcerative colitis. Part 1: definitions, diagnosis, extra-intestinal manifestations, pregnancy, cancer surveillance, surgery, and ileo-anal pouch disorders. *J Crohns Colitis* 2017;11:649–70.
- 26 Patil S, Gonuguntla K, Kumar M, al KM, *et al.* Myocarditis complicating inflammatory bowel disease: a comparison between ulcerative colitis and crohn's disease from the national inpatient sample. *J Am Coll Cardiol* 2020;75:S1077.
- 27 Bunu D-M, Timofte C-E, Ciocoiu M, *et al.* Cardiovascular manifestations of inflammatory bowel disease: pathogenesis, diagnosis, and preventive strategies. *Gastroenterol Res Pract* 2019;2019:1–14.
- 28 Van Gils AJM, van Gijlswijk S, Taminiau JAJM, *et al.* Recurrent pericarditis as an extra-intestinal manifestation of ulcerative colitis in a 14-year-old girl. *Clin Case Rep* 2018;6:1538–42.
- 29 Carande EJ, Piechnik SK, Myerson SG, *et al.* Inflammatory bowel disease and myocarditis: T1-mapping the heart of the problem. *Eur Heart J Cardiovasc Imaging* 2017;18:940.
- 30 Cooper LT. Myocarditis. *N Engl J Med* 2009;360:1526–38.
- 31 Bergman R, Parkes M. Systematic review: the use of mesalazine in inflammatory bowel disease. *Aliment Pharmacol Ther* 2006;23:841–55.
- 32 Brown G. 5-Aminosalicylic acid-associated myocarditis and pericarditis: a narrative review. *Can J Hosp Pharm* 2016;69:466–72.
- 33 Emmert MY, Salzberg SP, Emmert LS, *et al.* Severe cardiomyopathy following treatment with the tumour necrosis factor-alpha inhibitor adalimumab for Crohn's disease. *Eur J Heart Fail* 2009;11:1106–9.
- 34 Rezik M, Mattina D. Severe cardiomyopathy secondary to anti-TNF therapy for Crohn's disease. *J Am Coll Cardiol* 2016.
- 35 Lezcano-Gort LE, Gómez-Barrado JJ, Mogollón-Jiménez MV, *et al.* Hypersensitivity perimyocarditis after the first dose of infliximab. *Rev Esp Enferm Dig* 2015;107:249.
- 36 Slattery E, Ismail N, Sheridan J, *et al.* Myocarditis associated with infliximab: a case report and review of the literature. *Inflamm Bowel Dis* 2011;17:1633–4.
- 37 Dipasquale V, Gramaglia SMC, Catena MA, *et al.* Pericarditis during infliximab therapy in paediatric ulcerative colitis. *J Clin Pharm Ther* 2018;43:107–9.
- 38 Shivaji UN, Sharratt CL, Thomas T, *et al.* Review article: managing the adverse events caused by anti-TNF therapy in inflammatory bowel disease. *Aliment Pharmacol Ther* 2019;49:664–80.
- 39 Jaynik V, Khan N, Dubinsky M, *et al.* Efficacy and safety of Vedolizumab in ulcerative colitis and Crohn's disease patients stratified by age. *Adv Ther* 2017;34:542–59.
- 40 Dragoni G, Bagnoli S, Le Grazie M, *et al.* Long-term efficacy and safety of vedolizumab in patients with inflammatory bowel diseases: a real-life experience from a tertiary referral center. *J Dig Dis* 2019;20:235–42.
- 41 Feagan BG, Rutgeerts P, Sands BE, *et al.* Vedolizumab as induction and maintenance therapy for ulcerative colitis. *N Engl J Med* 2013;369:699–710.
- 42 Sands BE, Sandborn WJ, Van Assche G, *et al.* Vedolizumab as induction and maintenance therapy for Crohn's disease in patients naïve to or who have failed tumor necrosis factor antagonist therapy. *Inflamm Bowel Dis* 2017;23:97–106.
- 43 Sandborn WJ, Feagan BG, Rutgeerts P, *et al.* Vedolizumab as induction and maintenance therapy for Crohn's disease. *N Engl J Med* 2013;369:711–21.
- 44 Meserve J, Dulai P. Predicting response to Vedolizumab in inflammatory bowel disease. *Front Med* 2020;7:76.
- 45 Vermeire S, Loftus EV, Colombel J-F, *et al.* Long-term efficacy of Vedolizumab for Crohn's disease. *J Crohns Colitis* 2017;11:412–24.
- 46 Loftus EV, Colombel J-F, Feagan BG, *et al.* Long-term efficacy of Vedolizumab for ulcerative colitis. *J Crohns Colitis* 2017;11:400–11.
- 47 Colombel J-F, Sands BE, Rutgeerts P, *et al.* The safety of vedolizumab for ulcerative colitis and Crohn's disease. *Gut* 2017;66:839–51.
- 48 Badorff C, Knowlton KU. Dystrophin disruption in enterovirus-induced myocarditis and dilated cardiomyopathy: from bench to bedside. *Med Microbiol Immunol* 2004;193:121–6.
- 49 Caio G. Myocarditis with immune checkpoint blockade. *N Engl J Med* 2017;376:291–2.