

## CLINICAL LETTER

Novel *SCN5A* Variant Shows Multiple Phenotypic Expression in the Same Family

Cristina Balla<sup>1</sup>, MD, PhD; Daniela Mele<sup>2</sup>, MD; Francesco Vitali<sup>3</sup>, MD; Chiara Andreoli<sup>4</sup>, MD; Elisabetta Tonet, MD; Mariabeatrice Sanchini, MD; Alessandra Ferlini<sup>5</sup>, MD; Claudio Rapezzi, MD; Francesca Gualandi<sup>6</sup>, MD; Matteo Bertini<sup>7</sup>, MD, PhD

A healthy 39-year-old man (index patient, IV1, Figure, 5) was documented with spontaneous type 1 Brugada pattern during routine ECG before elective surgery. The ECG was recorded at standard and high-lead position (Figure, 1A). He reported previous episodes of syncope with prodromal symptoms diagnosed as of vasovagal origin by Tilt-test. Transthoracic echocardiography confirmed a structurally normal heart. Cardiac magnetic resonance (CMR) imaging showed normal biventricular dimensions, wall thickness and function, of note there were no right ventricular (RV) outflow tract structural abnormalities. Late gadolinium enhancement sequences were negative (Figure, 2). No ventricular arrhythmias were inducible at electrophysiology study.

The index patient's father (III2) received an implantable cardioverter defibrillator at the age of 45 years in secondary prevention after resuscitated cardiac arrest. At that time, CMR was not performed, and magnetic incompatible technology of implantable cardioverter defibrillator prevented CMR after the implant. The ECG after the event is shown in Figure, 1B. The ECG did not reveal type 1 Brugada pattern even after provocative drug challenge with flecainide. Transthoracic echocardiography showed signs of biventricular cardiomyopathy with RV dilation and moderate dysfunction, normal left ventricular volume with inferior hypokinesia, and reduced ejection fraction (42%). Coronary angiography was normal. Other systemic disorders have been excluded.

The patient IV4 (index' brother) had diagnosis of arrhythmogenic cardiomyopathy (ACM) at the age of 22 years. The ECG is shown in Figure, 1C. CMR detected

RV dilation with moderate dysfunction and RV outflow tract bulging. Late gadolinium enhancement sequences demonstrated a subepicardial distribution confined to the inferolateral left ventricular wall (Figure, 3). He experienced episodes of ventricular tachycardia with left bundle branch block morphology and he was treated with an implantable cardioverter defibrillator.

The patient IV2 (index' brother) had diagnosis of ACM at 30 years old. The ECG (Figure, 1D) did not show Brugada pattern either at standard or at high-lead position. CMR demonstrated RV dilation with localized RV outflow tract akinesia, wall thinning, and myocardial fibro-fatty replacement. Late gadolinium enhancement had a subepicardial distribution confined to the anterolateral left ventricular wall (Figure, 4)

Extended family history (Figure, 5) was characterized by the presence of sudden cardiac death in one brother of the index patient' paternal grandfather (patient I1) and in one cousin (patient III1); the index patient' paternal grandfather (patient II3) and 2 paternal uncles (patients II1-2) have been implanted with a pacemaker at young age (<50 years old).

Genetic testing was performed in the family through a commercially available Next-generation sequencing gene panel (Cardiomyopathy gene panel- Healthincode- <https://www.healthincode.com/>). A missense mutation in the sodium voltage-gated channel  $\alpha$  subunit 5 (*SCN5A*) gene (NM\_198056.2 c. 4064T>C; p.Leu1355Pro) was identified in the index case. The *SCN5A* variation was subsequently identified in patients III2, IV2, and IV4. The identified variant is not reported in

**Key Words:** Brugada syndrome ■ echocardiography ■ family ■ phenotype ■ tachycardia

Correspondence to: Cristina Balla, MD, PhD, Cardiology Unit, Azienda Ospedaliero-Universitaria S. Anna, Via A. Moro 8, Ferrara-Cona (FE), Italy. Email [blcst@unife.it](mailto:blcst@unife.it)  
For Sources of Funding and Disclosures, see page 753.

© 2021 The Authors. *Circulation: Genomic and Precision Medicine* is published on behalf of the American Heart Association, Inc., by Wolters Kluwer Health, Inc. This is an open access article under the terms of the [Creative Commons Attribution Non-Commercial-NoDerivs](https://creativecommons.org/licenses/by-nc-nd/4.0/) License, which permits use, distribution, and reproduction in any medium, provided that the original work is properly cited, the use is noncommercial, and no modifications or adaptations are made.

*Circulation: Genomic and Precision Medicine* is available at [www.ahajournals.org/journal/circgen](http://www.ahajournals.org/journal/circgen)

public databases of general population nor in subjects affected by *SCN5A*-related disorders. Leu1355 belongs to the S5 transmembrane segment in the domain III of protein (amino acids 1337–1359) implicated in pore formation (Figure, 6). Based on ACMG criteria,<sup>1</sup> the identified variant is classified as likely pathogenic (PP2, PM2, PP3, PP1-M).

To our knowledge, the present case is the first description of an *SCN5A* variant showing multiple phenotypic expression ranging from Brugada syndrome to ACM in the same family.

Brugada syndrome is an inherited channelopathy first described as a pure electrical disorder predisposing to the risk of sudden cardiac death. Subsequence evidence have shown subtle RV structural abnormalities and RV outflow tract changes leading to different hypothesis on the pathophysiology of the syndrome.<sup>2,3</sup>

ACM is a genetic heart muscle disorder characterized by fibro-fatty replacement that predispose to ventricular arrhythmias leading to cardiac arrest in young people.

The hypothesis of the close connection between Brugada syndrome and ACM has been supported by the results of Te Riele et al,<sup>4</sup> which show that rare variants in *SCN5A* are present in ≈2% of patients affected by ACM. Functional analysis of one of the *SCN5A* mutation showed not only reduced INa amplitude but also a structural deficit in the organization of cell adhesion, supporting the hypothesis that voltage-gated sodium 1.5 may channel have different mechanisms causing cardiomyopathy.<sup>4</sup>

Multiple mutation-positive family members harboring the same variant show different phenotypes. Factors, such as age, comorbidities, and environmental factors, may modify the effects of the primary genetic defect. Interindividual variability in disease expression may also be due to the inheritance of genetic modifiers that have a role to determine the age of onset, its rate of progression, and incidence of major cardiac events or to protect from the development of the disease.<sup>5</sup>

The current family adds further evidence about the pleiotropic nature of *SCN5A* showing how a single *SCN5A* variant may have different clinical expression in the same family.

## ARTICLE INFORMATION

### Affiliations

Cardiological Center (C.B., D.M., F.V., E.T., C.R., M.B.) and Medical Genetic Logistic Unit (M.S., A.F., F.G.), S. Anna University Hospital, Ferrara. Cardiology Unit, San Giovanni Battista Hospital Foligno (C.A.). Maria Cecilia Hospital, GVM Care & Research, Cotignola, Italy (C.R.).

### Sources of Funding

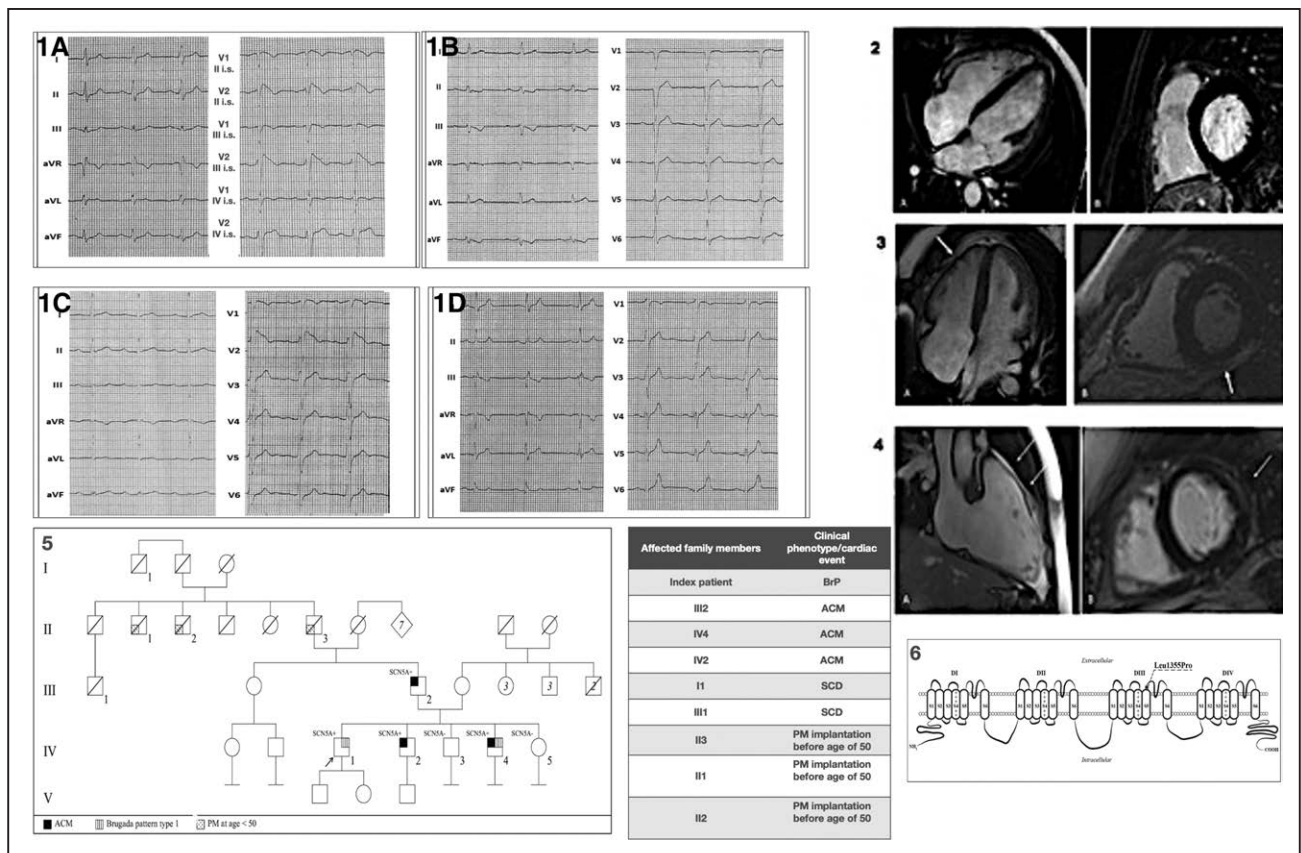
None.

### Disclosures

None.

## REFERENCES

- Richards S, Aziz N, Bale S, Bick D, Das S, Gastier-Foster J, Grody WW, Hegde M, Lyon E, Spector E, et al; ACMG Laboratory Quality Assurance Committee. Standards and guidelines for the interpretation of sequence variants: A joint consensus recommendation of the American College of Medical Genetics and Genomics and the Association for Molecular Pathology. *Genet Med*. 2015;17:405–424. doi: 10.1038/gim.2015.30
- Behr ER, Ben-Haim Y, Ackerman MJ, Krahn AD, Wilde AAM. Brugada syndrome and reduced right ventricular outflow tract conduction reserve: A final common pathway? *Eur Heart J*. 2021;42:1073–1081. doi: 10.1093/eurheartj/ehaa1051
- Gray B, Gnanappa GK, Bagnall RD, Femia G, Yeates L, Ingles J, Burns C, Puranik R, Grieve MS, Semsarian C, et al. Relations between right ventricular morphology and clinical, electrical and genetic parameters in Brugada Syndrome. *PLoS ONE*. 2018;13:e0195594. doi: 10.1371/journal.pone.0195594
- Te Riele AS, Agullo-Pascual E, James CA, Leo-Macias A, Cerrone M, Zhang M, Lin X, Lin B, Sobreira NL, Amat-Alarcon N, et al. Multilevel analyses of *SCN5A* mutations in arrhythmogenic right ventricular dysplasia/cardiomyopathy suggest non-canonical mechanisms for disease pathogenesis. *Cardiovasc Res*. 2017;113:102–111. doi: 10.1093/cvr/cvw234
- Cerrone M, Remme CA, Tadros R, Bezzina CR, Delmar M. Beyond the one gene-one disease paradigm: complex genetics and pleiotropy in inheritable cardiac disorders. *Circulation*. 2019;140:595–610. doi: 10.1161/CIRCULATIONAHA.118.035954



**Figure. ECGs of the proband and his affected relatives, MRI images of the proband and his affected relatives, family tree, and schematic representation of SCN5A mutation.**

**1A**, Index patient's (IV1) ECG shows type 1 Brugada pattern recorded at II, III, and IV intercostal space. **1B**, Subject III2 ECG shows first-degree atrioventricular block (AVB), nonspecific intraventricular conduction delay (IVCD) (QRS duration 144 ms), and inverted T waves in inferior leads. **1C**, Subject IV4 ECG shows first-degree AVB, fragmented QRS in lead DIII, aVF, and evidence of borderline type 1 Brugada pattern in V2. **1D**, Subject IV2 ECG shows nonspecific IVCD and QRS fragmentation in lead DIII. **2A**, Cardiac magnetic resonance (CMR) long axis 4-chamber view (index patient): no abnormalities of right ventricular wall. **2B**, Late gadolinium enhancement (LGE) short-axis view (index patient): no area of LGE. **3A**, CMR long axis 4-chamber view (subject IV4): right ventricular bulging (white arrow) **3B**, LGE short-axis view (subject IV4): Subepicardial LGE in the left ventricular inferolateral wall (white arrow) **4A**, CMR long axis 4-chamber view (subject IV2): thinned right ventricular wall (white arrow). **4B**, LGE short-axis view (subject IV2): midwall anterolateral late gadolinium enhancement (white arrow). **5**, Family tree. **6**, Topography of the SCN5A p. Leu1355Pro mutation identified in the family. Schematic representation of the voltage-gated sodium 1.5 channel with indicated the position of the Leu1355 residue within the S5 segment of domain III. ACM indicates arrhythmogenic cardiomyopathy; IS, intercostal space; PM, pacemaker; and SCD, sudden cardiac death.