

The First Case of a Drug-Resistant *Pasteurella multocida* Prosthetic Knee Infection Successfully Treated With Debridement, Antibiotics, and Implant Retention

Review began 04/14/2023

Review ended 04/25/2023

Published 05/01/2023

© Copyright 2023

Maritati et al. This is an open access article distributed under the terms of the Creative Commons Attribution License CC-BY 4.0., which permits unrestricted use, distribution, and reproduction in any medium, provided the original author and source are credited.

Martina Maritati ^{1,2}, Luca Liverani ¹, Antonio Gigante ³, Gustavo Alberto Zanoli ¹, Giuseppe De Rito ¹

1. Orthopaedics, Casa di Cura Santa Maria Maddalena, Occhiobello, ITA 2. Infectious Diseases, University Hospital of Ferrara, Ferrara, ITA 3. Orthopaedics and Trauma, Polytechnic University of Marche, Ancona, ITA

Corresponding author: Martina Maritati, mrtmtn@unife.it

Abstract

Pasteurella multocida, a zoonotic infectious organism, has most often been described in patients after an animal bite. It can cause a variety of infections ranging from superficial skin infections to more serious systemic infections, such as sepsis and meningitis. *P. multocida* is a rare but well-recognized cause of prosthetic joint infections.

Here, we report the first implant-associated infection caused by drug-resistant (penicillin, ampicillin, amoxicillin/clavulanic acid) *P. multocida*, which was cured with targeted antimicrobial treatment and debridement, exchange of mobile parts, and retention of the prosthesis.

Patients undergoing arthroplasty should be informed of the risks of close contact with pets, especially in light of the worrying phenomena of drug resistance spreading among animals due to the addition of antibiotics in animal feed.

Categories: Infectious Disease, Orthopedics

Keywords: drug susceptibility testing and antibiotic resistance, zoonosis, dair, peri-prosthetic joint infection, *pasteurella multocida*

Introduction

Pasteurella multocida is a gram-negative coccobacillus that is part of the indigenous flora of the oral cavity and digestive tract of many domestic and wild animals. Dogs and cats represent the main reservoir for *P. multocida* human infections [1,2] that are mainly contracted through bites or scratches from colonized animals. Other routes of infection, although less frequent, include animal licking [3] and kissing [4] or sharing food with pets [5]. Skin and soft tissue infections are by far the most frequent clinical manifestations caused by *P. multocida* although pneumonia, endocarditis, meningitis, and bloodstream infections have been described, especially in the elderly and immunocompromised [6]. In addition, licking the areas of damaged skin (especially feet and ankles) by pets leads to the spread of infection to proximal prosthetic joints, such as total knee [7] and hip [8] replacements.

Case Presentation

An 82-year-old female underwent left total knee arthroplasty (TKA) for osteoarthritis at our department in July 2021. She had a history of atrial fibrillation, which was being treated with dabigatran, stroke, chronic obstructive pulmonary disease (COPD), right mastectomy, left saphenectomy, and bilateral varicectomy. After three weeks, the postoperative course was uneventful, the patient had no pain, the wound was closed, and the absorbable suture was detached spontaneously (Figure 1).

How to cite this article

Maritati M, Liverani L, Gigante A, et al. (May 01, 2023) The First Case of a Drug-Resistant *Pasteurella multocida* Prosthetic Knee Infection Successfully Treated With Debridement, Antibiotics, and Implant Retention. *Cureus* 15(5): e38389. DOI 10.7759/cureus.38389

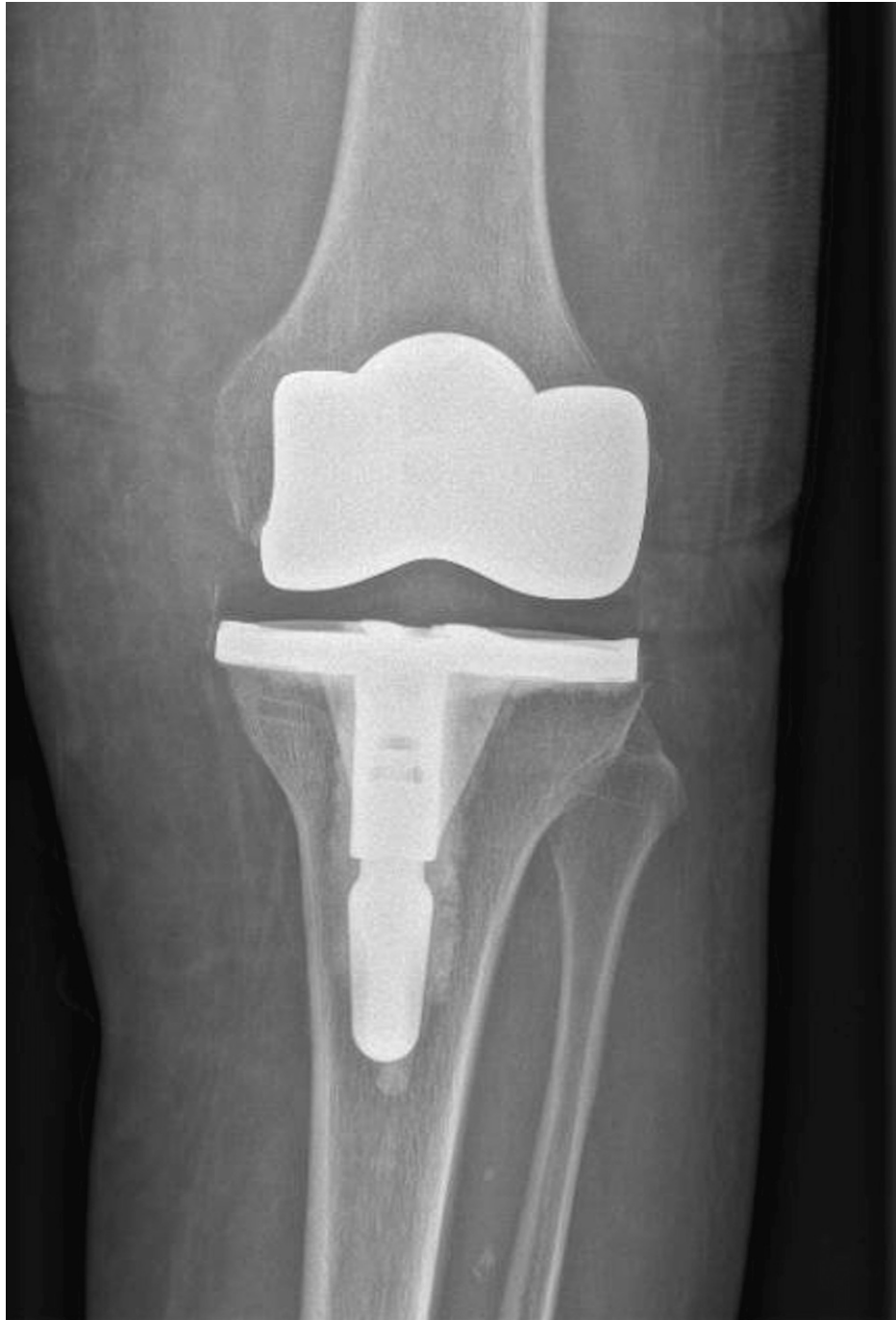

FIGURE 1: Postoperative X-ray (primary total knee arthroplasty) demonstrating the correct location of the implant.

Ten weeks after surgery, she was admitted to the emergency department because of a sudden onset of pain in the left knee with a restricted range of motion. She felt generally unwell without fever or chills, and her heart rate and blood pressure were in the normal range. The physical examination revealed edema, increased warmth, and red patches on the left leg to the ipsilateral knee. Due to suspected cellulitis, the patient was started on amoxicillin/clavulanic acid 875/125 mg thrice daily orally, without any clinical improvement. Therefore, she was referred to an infectious diseases specialist. On questioning, the patient claimed to own a very affectionate dog that was used to licking her ankles. Laboratory investigations revealed the absence of leukocytosis ($6.37 \times 10^3/\mu\text{L}$) with normal neutrophils (56.9%), elevated erythrocyte sedimentation rate of 73 mm/hour (normal range = 0-15 mm/hour), and C-reactive protein (CRP) of 4.5 mg/dL (normal range = 0-0.5 mg/dL). Ultrasonography showed the presence of a thin subcutaneous fluid layer in the knee and the proximal left leg area. Radiography of the left knee showed the correct placement of the implant without signs of radiolucency. The arthrocentesis (20 mL clear yellowish fluid) and subpatellar bursal aspiration (20 mL hematic fluid) were performed aseptically, and culture tests and chemical-physical analysis of the

aspirates were requested. Synovial fluid examination revealed elevated white blood cell count (36,320 cells/ μ L) with a high percentage of polymorphonuclear cells (94%) while cultures disclosed *P. multocida* growth. After the identification of bacterial species, susceptibility to antimicrobial agents was determined by the disk diffusion method on Mueller-Hinton agar. The following antibiotics were tested according to European Committee on Antimicrobial Susceptibility Testing (EUCAST) guidelines [9]: benzylpenicillin, ampicillin, amoxicillin-clavulanic acid, cefotaxime, tetracycline, levofloxacin, ciprofloxacin, and trimethoprim-sulfamethoxazole. The size of the inhibition zone of the disk diffusion assay for each antibiotic was determined using the EUCAST susceptibility breakpoints [9]. *Haemophilus influenzae* ATCC 49766 was used as an internal quality control strain. The detected isolate was found to be susceptible to cefotaxime, levofloxacin, ciprofloxacin, tetracycline, and trimethoprim-sulfamethoxazole, but resistant to benzylpenicillin, ampicillin, and amoxicillin-clavulanic acid. Amoxicillin/clavulanic acid was stopped and debridement, antibiotics, and implant retention (DAIR) treatment was proposed and accepted by the patient. The surgical procedure was performed six days after the onset of symptoms. Surgical access was gained using the previous incision with the same mid-vastus approach (Figure 2).

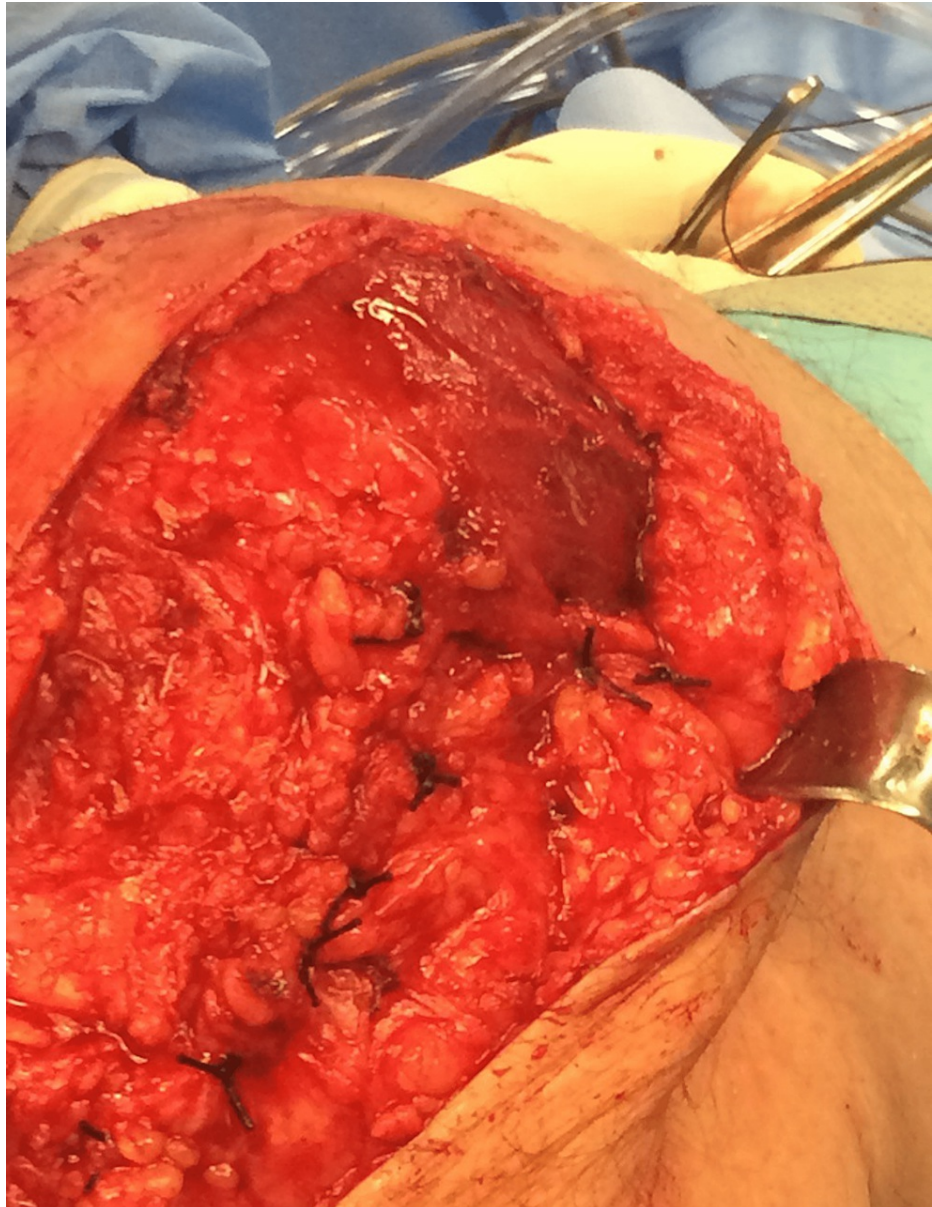


FIGURE 2: Debridement, antibiotics, and implant retention performed using the mid-vastus approach to spare the quadriceps tendon.

Routine intraoperative sampling included fluid aspiration and soft tissue debridement. Intraoperative cultures performed on multiple samples confirmed *P. multocida* infection. Radical synovectomy and thorough washout with 5 L of antiseptic solution tourniquet inflated composed of 500 cc NaCl 0.9%, 125 cc H₂O₂ 3%, 17.5 cc povidone-iodine 10%. The polyethylene spacer was exchanged with a new one of the same

size and shape. Postoperatively, ceftriaxone 2 g daily was started intravenously and continued at home after discharge. Thirteen days after DAIR surgery, intravenous therapy had to be discontinued due to the inability to maintain valid venous access, and oral levofloxacin 500 mg twice daily was started and continued until 12 weeks. Wound healing was uneventful, and both subjective symptoms and CRP values improved immediately and consistently in the postoperative period. CRP reached below the threshold values after eight weeks and remained stable at 12 weeks when treatment was stopped. One year postoperatively, the patient remains pain-free (19 months from primary TKA, 16 months after DAIR surgery), with no signs of prosthetic loosening on X-rays (Figure 3) and stably negative inflammatory biomarkers.

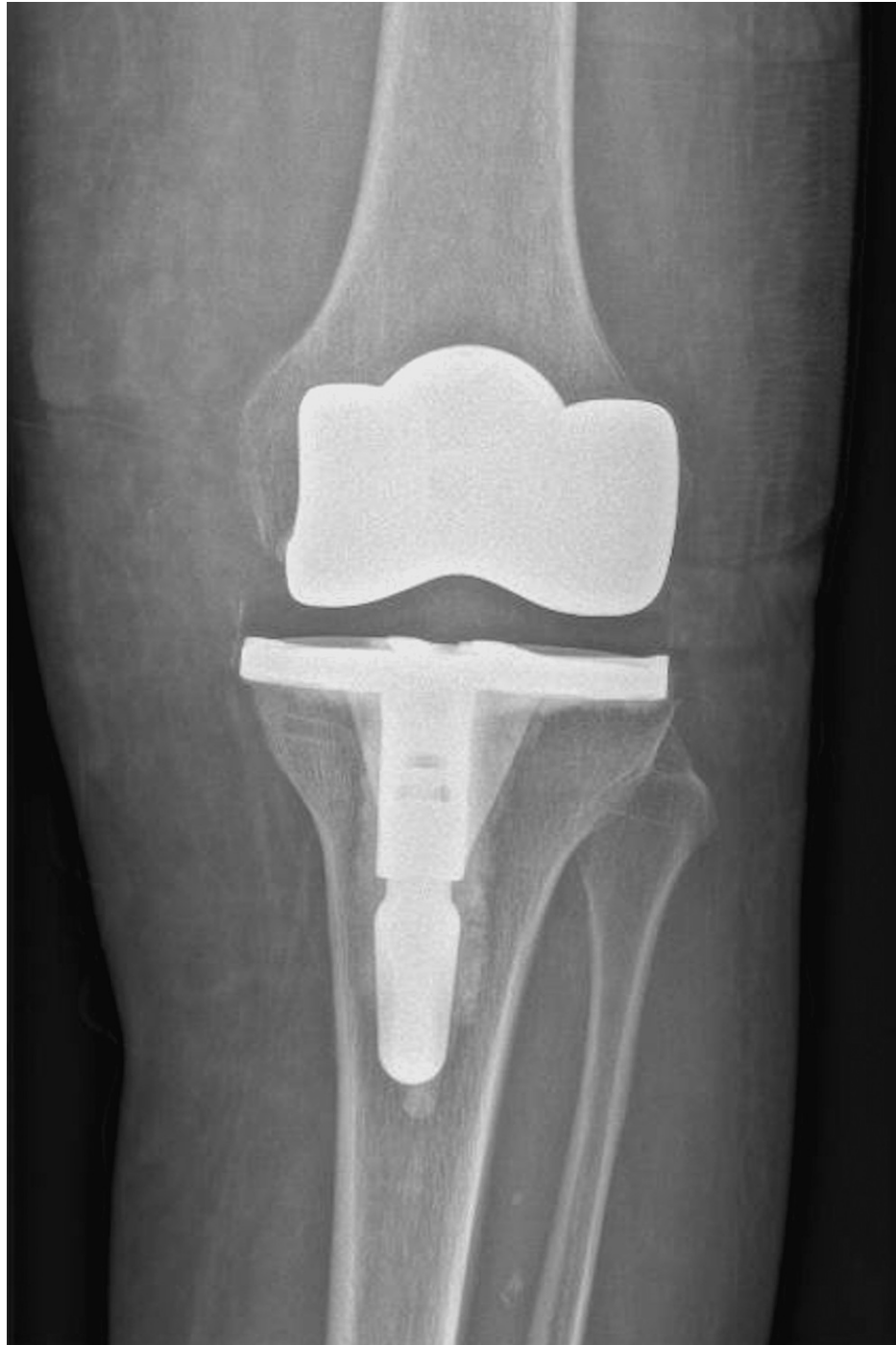

FIGURE 3: Radiographic control at the 16-month follow-up after debridement, antibiotics, and implant retention.

Discussion

P. multocida is the causative etiological agent of skin and soft tissue infections and, more rarely, septic

arthritis, osteomyelitis, prosthetic joint infections (PJIs), sepsis, and meningitis, particularly in immunocompromised hosts [10,11].

Since 1975, only 35 cases of PJIs caused by *P. multocida* have been described. Almost all diagnosed cases show some common characteristics, such as acute onset with a very intense inflammatory response, undocumented bacteremia in the majority of cases, early restoration from joint effusion, and close contact with family pets [12].

The majority of cases develop following a dog or cat bite in an anatomical area distal to the affected joint, without penetrative trauma to the joint itself. In this case, however, the patient did not report any bites or scratches from her dog, as described in other reports in the literature. PJI most commonly involves a single joint, usually the knee. More than 50% of patients who developed PJIs had altered host defenses such as diabetes mellitus, corticosteroids, alcoholism, organ transplants, COPD, and advanced age.

P. multocida is usually susceptible to several antibiotics, including penicillin, amoxicillin-clavulanate, piperacillin-tazobactam, doxycycline, fluoroquinolones (e.g., levofloxacin, ciprofloxacin), third- or later-generation cephalosporins (e.g., cefpodoxime, cefixime, ceftriaxone, ceftazidime), carbapenems (e.g., imipenem, meropenem), and cotrimoxazole. Clinical studies investigating the performance of several antibiotic classes against *Pasteurella spp.* infections are missing. Recommendations regarding the treatment of choice are evidence-based and founded on the expected antimicrobial susceptibility of the bacterium in in-vitro assays. Oral erythromycin, semi-synthetic penicillins (e.g., oxacillin, dicloxacillin), first-generation cephalosporins (e.g., cephalothin, cephalexin, cefadroxil), and clindamycin are poorly active against *P. multocida* in vitro and should never be prescribed as drugs of choice. Clinical failures, in fact, have occurred in patients treated with these agents.

In *Pasteurella* infections, the first treatment option is often penicillin, preferred for its narrow spectrum, broad safety, affordability, and wide experience of use. Other treatment options include ampicillin, amoxicillin, and cefuroxime. The phenomenon of penicillin resistance in *Pasteurella* isolates is not very common but has been described in a small percentage of cases. In a recent report of 44 patients affected by *P. multocida* infections, 16% of β -lactamase-positivity cases were reported among the 32 isolates with β -lactamase testing [1]. In these cases, however, no correlation emerged between the presence of beta-lactamase and the type of infection or its severity [1]. Although rare, emergent antibiotic resistance toward antibiotics other than penicillin (e.g., ampicillin, tetracycline) has been recently reported in particular settings [13,14]. In light of these findings, it might be advisable to test isolates from normally sterile environments (blood, deep tissue, implanted prosthetic devices) for beta-lactamase activity. The drug-resistant *Pasteurella* strain described in our case probably originated from the patient's dog, despite the fact that he had not been treated with antibiotics in the previous year. Domestic animals are increasingly being reported as carriers of drug-resistant pathogens due to antibiotics added to animal feed [15]. In Italy, the extensive use of antibiotics in veterinary and farm settings mainly concerns the administration of tetracycline and aminoglycosides, frequently involved in the development of resistance [16]. It is possible, however, that the meat used to produce dog food, in our case, came from foreign farms, where *P. multocida* resistant to ampicillin, amoxicillin/clavulanate, doxycycline, and tylosin was reported [17]. Furthermore, isolates of *P. multocida* resistant to various antibiotics, including amoxicillin-clavulanic acid, have recently been detected in animal feed [18].

Human infections caused by *P. multocida* resistant to amoxicillin/clavulanic acid are extremely rare. Only one case was described in 2021 and concerned a skin and soft tissue infection of the wrist following a cat bite. The patient was successfully treated with the incision and drainage of the abscess and a two-week course of levofloxacin. In this case, it was hypothesized that the origin of resistance to amoxicillin/clavulanic acid could be attributable to animal feed [14].

Regarding the type of surgical treatment, DAIR appears to be a viable option in treating acute PJIs caused by *P. multocida*, thus avoiding two-stage exchange. Despite sporadic previous descriptions of non-biofilm-producer strains [19], knowledge of the ability of *Pasteurella spp.* to form biofilms during PJIs in vivo and its possible prognostic implications remains poor. In this regard, the choice of conservative treatment with implant retention must always be considered in cases of acute infections (onset of symptoms less than three weeks), including radical surgical debridement with replacement of the mobile components and targeted antibiotic therapy for 12 weeks, according to current recommendations [20]. Our experience suggests that DAIR performed by a specialized orthopedic surgeon along with antibiotic monotherapy based on antimicrobial susceptibility testing is a valid option for treating acute PJIs caused by *P. multocida*, even in the case of penicillin and β -lactamase inhibitor resistance.

Conclusions

The high prevalence of pets in families increases the risk of exposure to *P. multocida* as well as possible infections. Patients undergoing arthroplasties should be made aware of the risk of close contact with pets. To our knowledge, the presented case is the first to report a drug-resistant *P. multocida* PJI infection in humans, which was successfully treated with a multidisciplinary approach including implant retention and targeted antimicrobial therapy. This case highlights the need to monitor the antibiotic susceptibility of

Appendices

ZA

I have now checked all the references you gave me, and specifically the three articles passerella multocida infections after TKA cases which have been treated with DAIR. Unfortunately none of these articles exist. It's a pity because they seemed very promising and they were exactly what I was looking for. How is this possible. Can you do better if I ask you again for some REAL references?



I apologize for the confusion and the inconvenience that my previous responses have caused you. As an AI language model, I rely on pre-existing knowledge and training to provide answers to your questions, and sometimes, I may provide incorrect information.



I understand your frustration and I will do my best to provide you with accurate and helpful information. Here are some references to articles that describe cases of *Pasteurella multocida* infections following total knee arthroplasty that were treated with debridement, antibiotics, and implant retention (DAIR):




1. Munoz-Mahamud E, Garcia S, Pellise F, et al. *Pasteurella multocida* prosthetic joint infection: a case report and review of the literature. *Scand J Infect Dis.* 2007;39(4):362-365. doi: 10.1080/00365540601041444
2. Gavazzi G, Di Bella S, Piepoli M, Goglio A. *Pasteurella multocida* infection of total knee arthroplasty treated by debridement and retention of the components: a case report. *Knee Surg Sports Traumatol Arthrosc.* 2003;11(3):187-189. doi: 10.1007/s00167-003-0396-9
3. Magnan B, Regis D, Biscaglia R, Bartolozzi P. *Pasteurella multocida* infection after total knee arthroplasty: a case report. *J Arthroplasty.* 2002;17(2):240-242. doi: 10.1054/arth.2002.29449

I hope these references will be helpful to you. Please let me know if you have any further questions or concerns.

FIGURE 4: Screenshot showing ChatGPT in a further attempt to provide real references, once again unsuccessfully.

Our experience with ChatGPT was very positive and its support was helpful in writing this case, especially for the general microbiological information of *Pasteurella multocida* and the aspects related to the debridement, antibiotics, and implant retention surgical procedure. However, we found a limitation of ChatGPT in providing reliable and actually existing literature references. This phenomenon, called "hallucination," has already been described. Deep learning-based generation is prone to "hallucinate" unintended text, which degrades the system performance and fails to meet user expectations in many real-world scenarios.

ZA hello. Do you know anything about *Pasteurella multocida* infections?

 Hello! Yes, I can provide some information about *Pasteurella multocida* infections.  

Pasteurella multocida is a type of bacteria that can be found in the mouths of many animals, including cats, dogs, and other domesticated and wild animals. These bacteria can cause infections in humans, usually as a result of a bite or scratch from an infected animal.

The most common type of infection caused by *Pasteurella multocida* is cellulitis, which is a skin infection characterized by redness, swelling, and pain in the affected area. Other possible symptoms of a *Pasteurella* infection may include fever, chills, and swollen lymph nodes.

In severe cases, *Pasteurella* infections can lead to more serious complications, such as sepsis or meningitis. However, most cases can be effectively treated with antibiotics.

If you have been bitten or scratched by an animal and suspect that you may have a *Pasteurella* infection, it is important to seek medical attention promptly. Your healthcare provider can diagnose the infection and recommend appropriate treatment, which may include antibiotics and/or wound care. Additionally, you may need to receive a tetanus shot, depending on the circumstances of the injury.

FIGURE 5: Screenshot showing ChatGPT producing an overview of *Pasteurella multocida* infections.

ZA Can you give me a description of a DAIR surgery I can use report

 DAIR surgery, also known as Debridement, Antibiotics, and Implant Retention, is a surgical  

procedure used to treat infections in patients who have undergone orthopedic surgery. The procedure is typically performed in cases where the infection has developed within 30 days of the initial surgery.

During the DAIR surgery, the surgeon will first remove any visible signs of infection, such as pus or dead tissue, from the surgical site. This is known as debridement. The surgeon will then insert a catheter or other instrument into the wound to irrigate it with saline solution, which helps to wash away any remaining bacteria.

Next, the surgeon will administer antibiotics directly into the wound to help kill any remaining bacteria. This is usually done by placing antibiotic beads or other delivery systems within the surgical site. In some cases, the patient may also be given systemic antibiotics, such as intravenous antibiotics, to help fight the infection.

Finally, the surgeon will attempt to retain any implanted hardware, such as screws or plates, that were used in the original surgery. If the hardware is found to be contaminated with bacteria, it may need to be removed and replaced.

After the DAIR surgery, the patient will typically be closely monitored for signs of infection. They may also need to continue taking antibiotics and undergo additional imaging or other tests to ensure that the infection has been fully treated. In some cases, additional surgeries may be needed to fully resolve the infection.

FIGURE 6: Screenshot showing ChatGPT providing information on how to perform a debridement, antibiotics, and implant retention procedure.

ZA You don't seem to be able to help with references. Authors you quote are real, so are the journals. Titles are very good but they do not exist. you should probably stop giving references and check your sources, don't you think?

I apologize for the continued confusion caused by the references I provided. As an AI language model, I rely on my programming and databases to provide accurate information. However, in this case, it appears that there may have been an error in the information provided to me.

I understand that this has been frustrating for you, and I apologize for any inconvenience or wasted time this may have caused. I will make sure to take extra care in providing accurate information in the future.

FIGURE 7: Screenshot showing ChatGPT trying to provide references on the topic, but not very efficiently.

Additional Information

Disclosures

Human subjects: Consent was obtained or waived by all participants in this study. **Conflicts of interest:** In compliance with the ICMJE uniform disclosure form, all authors declare the following: **Payment/services info:** All authors have declared that no financial support was received from any organization for the submitted work. **Financial relationships:** All authors have declared that they have no financial relationships at present or within the previous three years with any organizations that might have an interest in the submitted work. **Other relationships:** All authors have declared that there are no other relationships or activities that could appear to have influenced the submitted work.

Acknowledgements

The authors would like to thank ChatGPT.

References

- Giordano A, Dincman T, Clyburn BE, Steed LL, Rockey DC: Clinical features and outcomes of *Pasteurella multocida* infection. *Medicine (Baltimore)*. 2015, 94:e1285. [10.1097/MD.0000000000001285](https://doi.org/10.1097/MD.0000000000001285)
- Kannagara DW, Pandya D, Patel P: *Pasteurella multocida* infections with unusual modes of transmission from Animals to humans: a study of 79 cases with 34 nonbite transmissions. *Vector Borne Zoonotic Dis*. 2020, 20:637-51. [10.1089/vbz.2019.2558](https://doi.org/10.1089/vbz.2019.2558)
- Chang K, Siu LK, Chen YH, Lu PL, Chen TC, Hsieh HC, Lin CL: Fatal *Pasteurella multocida* septicemia and necrotizing fasciitis related with wound licked by a domestic dog. *Scand J Infect Dis*. 2007, 39:167-70. [10.1080/00365540600786572](https://doi.org/10.1080/00365540600786572)
- Kawashima S, Matsukawa N, Ueki Y, Hattori M, Ojika K: *Pasteurella multocida* meningitis caused by kissing animals: a case report and review of the literature. *J Neurol*. 2010, 257:653-4. [10.1007/s00415-009-5411-0](https://doi.org/10.1007/s00415-009-5411-0)
- Navarro-Navajas A, Ariza-Ordoñez N, Barrera C: [*Pasteurella multocida* bacteremia associated with contact with a domestic animal: case report]. *Rev Chilena Infectol*. 2019, 36:667-9. [10.4067/S0716-10182019000500667](https://doi.org/10.4067/S0716-10182019000500667)
- Hasan J, Hug M: *Pasteurella Multocida*. StatPearls Publishing, Treasure Island, FL; 2023.
- Heym B, Jouve F, Lemoal M, Veil-Picard A, Lortat-Jacob A, Nicolas-Chanoine MH: *Pasteurella multocida* infection of a total knee arthroplasty after a "dog lick". *Knee Surg Sports Traumatol Arthrosc*. 2006, 14:993-7. [10.1007/s00167-005-0022-5](https://doi.org/10.1007/s00167-005-0022-5)
- Lam PW, Page AV: *Pasteurella multocida* non-native joint infection after a dog lick: a case report describing a complicated two-stage revision and a comprehensive review of the literature. *Can J Infect Dis Med Microbiol*. 2015, 26:212-7. [10.1155/2015/963529](https://doi.org/10.1155/2015/963529)
- European Committee on Antimicrobial Susceptibility Testing . (2023). Accessed: February 28, 2023: https://www.eucast.org/fileadmin/src/media/PDFs/EUCAST_files/Breakpoint_tables/v_13.0_Breakpoint_Tables.pdf.
- Rhea S, Weber DJ, Poole C, Cairns C: Risk factors for hospitalization after dog bite injury: a case-cohort study of emergency department visits. *Acad Emerg Med*. 2014, 21:196-203. [10.1111/acem.12312](https://doi.org/10.1111/acem.12312)
- Christenson ES, Ahmed HM, Durand CM: *Pasteurella multocida* infection in solid organ transplantation. *Lancet Infect Dis*. 2015, 15:235-40. [10.1016/S1473-3099\(14\)70895-3](https://doi.org/10.1016/S1473-3099(14)70895-3)
- Honnorat E, Seng P, Savini H, Pinelli PO, Simon F, Stein A: Prosthetic joint infection caused by *Pasteurella multocida*: a case series and review of literature. *BMC Infect Dis*. 2016, 16:435. [10.1186/s12879-016-1763-0](https://doi.org/10.1186/s12879-016-1763-0)
- Seki M, Sakata T, Toyokawa M, Nishi I, Tomono K: A chronic respiratory *Pasteurella multocida* infection is well-controlled by long-term macrolide therapy. *Intern Med*. 2016, 55:307-10. [10.2169/internalmedicine.55.4929](https://doi.org/10.2169/internalmedicine.55.4929)
- Wei A, Dhaduk N, Taha B: Wrist abscess due to drug-resistant *Pasteurella multocida*. *IDCases*. 2021,

- 26:e01277. [10.1016/j.idcr.2021.e01277](https://doi.org/10.1016/j.idcr.2021.e01277)
15. Nüesch-Inderbilen M, Treier A, Zurfluh K, Stephan R: Raw meat-based diets for companion animals: a potential source of transmission of pathogenic and antimicrobial-resistant Enterobacteriaceae. *R Soc Open Sci.* 2019, 6:191170. [10.1098/rsos.191170](https://doi.org/10.1098/rsos.191170)
 16. Di Francesco CE, Smoglica C, Profeta F, Farooq M, Di Giannatale E, Toscani T, Marsilio F: Research note: detection of antibiotic-resistance genes in commercial poultry and turkey flocks from Italy. *Poult Sci.* 2021, 100:101084. [10.1016/j.psj.2021.101084](https://doi.org/10.1016/j.psj.2021.101084)
 17. Atere V, Bamikole AM, Oluyeye AO, Ajurojo OA, Alo OS: Prevalence and antibiotic resistance of *Pasteurella multocida* isolated from chicken in Ado-Ekiti metropolis. *Int J Sci World.* 2016, 4:2. [10.14419/ijsw.v4i2.6273](https://doi.org/10.14419/ijsw.v4i2.6273)
 18. Elsayed MS, Eldsouky SM, Roshdy T, et al.: Virulence determinants and antimicrobial profiles of *Pasteurella multocida* isolated from cattle and humans in Egypt. *Antibiotics (Basel).* 2021, 10:480. [10.3390/antibiotics10050480](https://doi.org/10.3390/antibiotics10050480)
 19. Romanò CL, De Vecchi E, Vassena C, Manzi G, Drago L: A case of a late and atypical knee prosthetic infection by no-biofilm producer *Pasteurella multocida* strain identified by pyrosequencing. *Pol J Microbiol.* 2013, 62:435-8.
 20. Zimmerli W, Trampuz A, Ochsner PE: Prosthetic-joint infections. *N Engl J Med.* 2004, 351:1645-54. [10.1056/NEJMra040181](https://doi.org/10.1056/NEJMra040181)