

Article

The Facial Approximation of the Skull Attributed to Jan Žižka (ca. AD 1360–1424)

Cicero Moraes ^{1,*}, Johari Yap Abdullah ^{2,3,*}, Jiri Šindelář ⁴, Matěj Šindelář ⁴, Zuzana Thomová ⁵,
Jakub Smrčka ⁶, Mauro Vaccarezza ^{7,8}, Thiago Beaini ⁹ and Francesco Maria Galassi ¹⁰

- ¹ Ortogonline Treinamento em Desenvolvimento Profissional e Consultoria Ltda, Sinop 78557-682, MT, Brazil
² Craniofacial Imaging Laboratory, School of Dental Sciences, Universiti Sains Malaysia Health Campus, Kota Bharu 16150, Kelantan, Malaysia
³ Dental Research Unit, Center for Transdisciplinary Research (CFTR), Saveetha Institute of Medical and Technical Sciences, Saveetha Dental College, Saveetha University, Chennai 602105, India
⁴ GEO-CZ, 391 43 Tábor, Czech Republic; geo@geo-cz.com (J.Š.); matej.sindelar6@seznam.cz (M.Š.)
⁵ South Bohemian Museum, 370 51 České Budějovice, Czech Republic; thomova@muzeumcb.cz
⁶ Hussite Museum, 390 01 Tábor, Czech Republic; smrcka@husitskemuzeum.cz
⁷ Department of Environmental Sciences and Prevention, University of Ferrara, 44121 Ferrara, Italy; mauro.vaccarezza@curtin.edu.au
⁸ Curtin Medical School, Faculty of Health Sciences, Curtin University, Bentley, WA 6102, Australia
⁹ Faculty of Dentistry, Federal University of Uberlândia, Uberlândia 38408-100, MG, Brazil; tbeaini@gmail.com
¹⁰ Department of Anthropology, Faculty of Biology and Environmental Protection, University of Lodz, 90-237 Łódź, Poland; francesco.galassi@biol.uni.lodz.pl
* Correspondence: cogitas3d@gmail.com (C.M.); johariyap@usm.my (J.Y.A.)

Abstract: The present study aims to approximate the face from the alleged skull of Jan Žižka (ca. AD 1360–1424), a military commander and national hero in the Czech Republic. Found in 1910, the skull has only a fraction of its original structure, which required an initial effort to reconstruct the missing regions from data collected in CT scans of living people's heads. The forensic facial approximation consisted of projecting the skin boundaries with soft tissue markers and cross-referencing data from statistical projections from CT scans of living people and the use of the anatomical deformation technique, where the digital head of a virtual donor was adjusted until it matched the alleged skull of the Czech general. The final face was the result of the cross-referencing of all data and the completion of the structure respected the iconography attributed to Jan Žižka.

Keywords: anatomy; anthropology; artificial intelligence; digital; facial approximation; Jan Žižka



Academic Editor: Arlen F. Chase

Received: 14 November 2024

Revised: 12 December 2024

Accepted: 23 December 2024

Published: 26 December 2024

Citation: Moraes, C.; Abdullah, J.Y.; Šindelář, J.; Šindelář, M.; Thomová, Z.; Smrčka, J.; Vaccarezza, M.; Beaini, T.; Galassi, F.M. The Facial Approximation of the Skull Attributed to Jan Žižka (ca. AD 1360–1424). *Heritage* **2025**, *8*, 7. <https://doi.org/10.3390/heritage8010007>

Copyright: © 2024 by the authors. Licensee MDPI, Basel, Switzerland. This article is an open access article distributed under the terms and conditions of the Creative Commons Attribution (CC BY) license (<https://creativecommons.org/licenses/by/4.0/>).

1. Introduction

1.1. The Historical Character of Jan Žižka

Jan Žižka (ca. AD 1360–1424) was a military commander born in Tročnov, Bohemia (present-day Czech Republic). Considered a national hero, he led a series of campaigns, including the victory of the Hussite armies against King Sigismund in 1420. Žižka lost one of his eyes (Figure 1) at a young age on an unknown occasion, but this did not prevent him from developing in the art of war, revolutionizing the field of warfare by introducing the use of cannons mounted on mobile and armored agricultural carts, considered by some to be the precursor of the war tank. He was also one of the first to group cavalry, infantry, and artillery as a tactical corps, resulting in a virtually unbeatable system [1]. Before he died in 1424, he lost sight in his other eye, but he continued to collaborate with his followers, making his reputation as invincible on the battlefield last until today, both in the historical

and popular context, as is the case with the film titled *Mediaeval*, based on his story and which became one of the most watched productions on the *Netflix* platform in 2022 [2].



Figure 1. Jan Žižka, head carved in pumice, 16th century. Wolfgang Sauber, Wikimedia Commons. Public Domain (https://commons.wikimedia.org/wiki/File:Hussitenf%C3%BChrer_Jan_Zizka.jpg). Accessed on 13 November 2024.

1.2. The Discovery of the Remains

Jan Žižka died on 11 October 1424 during the conquest of Přebyslav Castle, which is located in the present-day territory of the Vysočina region, i.e., on the Czech-Moravian border. Historical sources claim that Žižka died from the effects of a festering ulcer, while many historians have suggested that it was plague [3]. One of the first to object to this possibility was an anthropologist, Emanuel Vlček, who, from the 1960s onwards, worked on the history of the city. He lists a number of objections to this claim. First, at the time of Jan Žižka's death, no plague epidemics had been recorded in Bohemia. None of his relatives who were present at his death contracted the plague or any other contagious disease. Vlček is inclined to the doctors' opinion that Žižka died of blood poisoning following an untreated carbuncle (boil), which may have looked like a "purulent ulcer" [4].

Jan Žižka's funeral took place in autumn of the same year he died, and he was buried in the Church of the Holy Spirit in Hradec Králové. The burial place or grave is no longer known. The old Czech chronicles mention a grave in the right pillar in the main nave of

the church on the Gospel side [4–6]. After some time, the remains were to be transferred to the Church of St. Peter and Paul in Čáslav (Figures 2 and 3). The reason for the translation is unknown [7]. On 21 November 1910, during the reconstruction of the Church of St. Peter and Paul in Čáslav, a walled-up niche was discovered in the northern wall of the tower [8]. The niche was found 115 cm above the existing floor, 115 cm high, 78 cm wide, and 84 cm deep (Figure 2). The niche contained femurs, the upper part of a skull, other skull fragments, a larger pottery fragment, possibly a bowl, a disintegrated cloth, and perhaps two wooden boards with slats (Figure 4) [8,9].

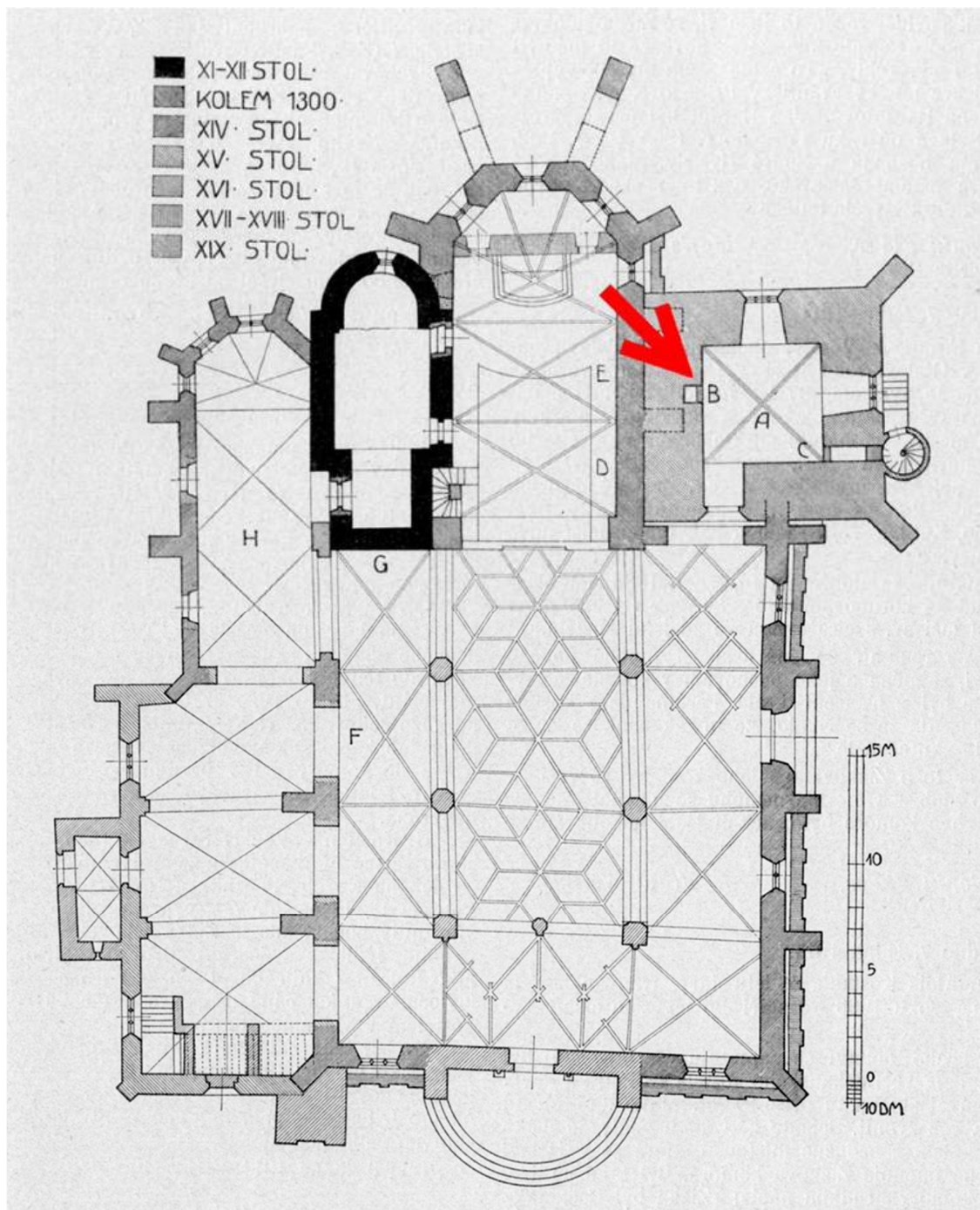


Figure 2. Location of the discovery of the skull attributed to Jan Žižka. Image in the public domain [8].



Figure 3. Current photo of the Church of St. Peter and Paul in Čáslav. Author: Petr1888, under Creative Commons license at Wikimedia Commons (<https://bit.ly/3ODLVqC>) accessed on 13 November 2024.

The first anthropological report focused on the study of skeletal remains and was made by the founder of Czech anthropology, Jindřich Matiegka (1862–1941) [8]. However, his report was not accepted by other scholars who assessed it, which was the result of a division into opposite views, composed on one side by experts who believed that these were the authentic bones of Jan Žižka, and on the other side by those who believed that they were a forgery, each side presenting their arguments in an environment of fierce debate [4]. Since then, the partial skull and other skeletal remains have been treated mostly by Emanuel Vlček (1925–2006), who prepared an anthropological and medical survey of Čáslav's discovery [10].




Figure 4. The skull attributed to Jan Žižka among other remains and objects, 1910 photo in the public domain (https://commons.wikimedia.org/wiki/File:%C4%8C%C3%A1slavsk%C3%BD_n%C3%A1lez.jpg), accessed on 13 November 2024.

The information on anthropological examinations contained in this article, which will be presented below, was extracted from physical studies carried out by Emanuel Vlček, whose descriptions contain more detailed data and photographs. In order to maintain the focus on the facial approximation, this manuscript reports only the most important data related to the cited study. Nevertheless, we recommend reading Vlček’s work for a full understanding of the decisions taken by this anthropologist [4,10].

The other recovered bones in the niche discovered in 1910 in Čáslav belonged to at least three people, and none of the total of seven bones—occipital bone, maxilla, nasal bones, right and left ribs, right and left femur—can be assigned to the upper part of the skull with nasal bones and right temporal bone, i.e., to Čáslav’s bald head [4,10]. This preserved skull consists of the frontal bone, both parietal bones and the upper half of the occipital bone. A part of the right temporal bone is also preserved. Unfortunately, these remains were secondarily damaged by blunt blows to the occipital bone and the upper edge of the left orbit [4]. Additional damage is related to the rapid drying of the skull bones and mechanical damage to the bones caused by handling the skull.

The classifying features for sex determination, found in Professor Vlček’s work, were primarily the strong development of the supraorbital arches, the frontal and parietal protuberances not being formed, and a process on the temporal bone being massively developed with a deep notch and with a strongly formed rim over the external auditory canal. According to the anthropologist, those traits would lead to the conclusion that the human remains are from a male individual. This analysis also found notable and modeled muscular insertions in the skull. In addition, though this was not commented on by him, the robustness of the glabella would also be an indication of the male sex [11]. Vlček determined the age solely based on the closure and growth of the cranial sutures.

According to him, this individual did not exceed a mature age. Hence, his age at death is estimated as 50 ± 10 years [4,10].

Regarding the individual's ancestry, the authors did not find any mention of such a characteristic in Vlcek's study, but given the approach that seems to agree with the fact that it belonged to Jan Žižka and since he is historically described as a European individual, there is no reason to doubt that the skull belonged to an individual of European ancestry. This approach can be reinforced, though indirectly and not free of errors, that the characteristics, such as the proportions of the neurocranium, the glabella, and the projecting nasal bone, are compatible with European individuals [12].

Healed lesions were assessed on the skull using computed tomography (CT). These are a total frontal bone flap over the left orbit and an arcuate depression. This alteration was caused by the formation of a massive lesion from the incisional wound that passed through the upper and lower margins of the left orbit. Considering the healing process of this wound, the anthropologist concluded that the injury occurred before the individual had completed growth, between the ages of 10 and 14 years. Other traces of the injury were found in the region of the right supraorbital arch, where an encapsulated healing hematoma was found. This injury, according to the anthropologist, was caused by the detachment of the periosteum from the surface of the bone by a blunt blow directed at the region of the right eye and healed shortly before the death of the individual under study. Some images of the skull in detail can be seen at the link: <https://www.staletapraha.cz/pdfs/pha/1984/01/05.pdf> accessed on 13 November 2024. Historically, this is the period of the siege of Rabí Castle in 1421 [4,10].

After anthropological and medical research on the skull and its identification with historical events, anthropologists came to the conclusion that it is an authentic relic of Jan Žižka. The most recent research, which has not yet been scientifically published, was carried out by the Institute of Nuclear Physics of the CAS, based on the radiocarbon method. It was found that the individual in question died around 1424, the same time as the famous warlord Jan Žižka of Trocnov [13].

1.3. The Facial Approximation

On the occasion of the 600th anniversary of Jan Žižka's death in 2024, there was a movement to reveal his face from the available remains. The skull was scanned using photogrammetry and the process began, with the aim of revealing the face in early October.

2. Materials and Methods

Forensic facial approximation (FFA) is an auxiliary recognition technique that uses a skull as a basis to approximate the face that the individual would have had in life. In the forensic context, it is applied when there is little or no information about the identity of this person, and can serve as an initial element of recognition, which can lead to subsequent identification with DNA techniques or comparative analysis of the dental arches [14–16].

In addition to the forensic field, facial reconstructions are also presented in an archaeological or historical context, usually with artistic and/or speculative elements, such as skin, hair, and eye color, without DNA data, or even specific clothing or hairstyles, which differs from forensic work, which is more objective and anchored in data available on mortal remains or at the crime scene, such as clothing and fabric remains. Examples of the use of the technique in the field of anthropology/history can be seen in the presentation of faces of ancestors of human evolution, such as a Neanderthal [17], passing through prehistoric humans [18], from the Middle Ages [19] or more modern ones like Gertrude, one of the 30 people who died during the sinking of the Swedish ship *Vasa* in 1681 [20].

In the present work, the technique is used in the museum context, aiming to approximate the face from the skull attributed to Jan Žižka, following the steps of previously published works, starting with the reconstruction of the skull, the statistical and anatomical projections of the soft tissue, complemented by the anatomical deformation technique and concluding the approach with the generation of the final media for public presentation [21–23]. The work was carried out mainly in the Blender 3D software with the help of the *OrtogOnBlender* add-on and its *ForensicOnBlender* submodule, which provides specific tools for executing FFA [24].

The basic element for facial approximation is the dry skull, but in the case of the present work, an additional challenge was presented, since a significant part of the splanchnocranium is missing, therefore requiring the reconstruction of the large missing region. A few years ago, the team found itself in a similar situation, when reconstructing the skull of Saint Ludmila of Bohemia, also with the splanchnocranium missing, and using as a basis a projection made, coincidentally, by Dr. Vlček, the same specialist who worked on the alleged skull of Jan Žižka. After the work, some members of the present team studied an approach for projecting missing regions of the skull and, when testing such projections on the skull of Ludmila of Bohemia, it was observed that Vlček's reconstruction was within the standards expected for a skull projected from the remnant. However, for the present work, the specialist did not provide a complete reconstruction, limiting himself to presenting a partial facial reconstruction.

Ludmila da Bohemia's facial approximation resulted in a peer-reviewed publication that addressed not only the forensic technique but also the projection of facial structures from anatomical landmarks, which was later incorporated into *OrtogOnBlender* and will be presented below. The issue is that, although a technique has shown consistency in the projection of the splanchnocranium, being published in a peer-reviewed journal and based on measurements in a significant sample of CT scans, doubts about the reliability of such an approach remained present, especially among critics of the methodology.

In order to assess this degree of precision, a preliminary study was carried out a few months before the project presented in this article was carried out, in which a clearer margin of error was measured regarding how close a statistical projection would be to the real piece. Ten complete skull tomographies of modern individuals belonging to different ancestries and anonymized were randomly selected and aligned to the Frankfurt plane. Initially, the skulls were completely reconstructed from the CT scans (Figure 5A,D) and from these, two groups were created, one composed of the skulls without the mandibles (Figure 5B,E) and another group containing pieces with a significant part of the splanchnocranium erased (Figure 5C,F), leaving almost only the neurocranium (occasionally, but not always, a small part of the nasal bone and orbits). Two reconstructions were made, based on the statistical projection methodology of the limits of the bone tissue, based on Moraes et al. (2022) and Moraes and Suharschi (2022) [25,26]. Their aim was to measure the average distance between the projections and the complete skull, as well as the standard deviations, and to compare with the results presented in Wilkinson (2004), where six skulls were reconstructed each in a different region and later compared with their complete version. In that study, all reconstructions had a good level of compatibility, with the exception of the mandible [27].

For the comparison of the mandible reconstruction, 6 landmarks were chosen (Me Z—Menton on the Z axis, Me Y—Menton on the Y axis, GoRL—Lateral limit line of the right gonion, GoLL—Lateral limit line of the right gonion, PBR Y R—Posterior border ramus on the right X axis, PBR Y L—Posterior border ramus on the left X axis).

For the comparison of the reconstruction without a significant part of the viscerocranium, 9 landmarks were chosen (NS—Nasolabial, Incis, Z—Base of the incisors on the Z axis, Incis, Y—Base of the incisors on the Y axis, Me Z—Menton on the Z axis, Me

Y—Menton on the Y axis, GoRL—Lateral limit line of the right gonion, GoLL—Lateral limit line of the right gonion, PBR Y R—Posterior border ramus on the right X axis, PBR Y L—Posterior border ramus on the left X axis). As some models had the end of nasals, this point was not evaluated.

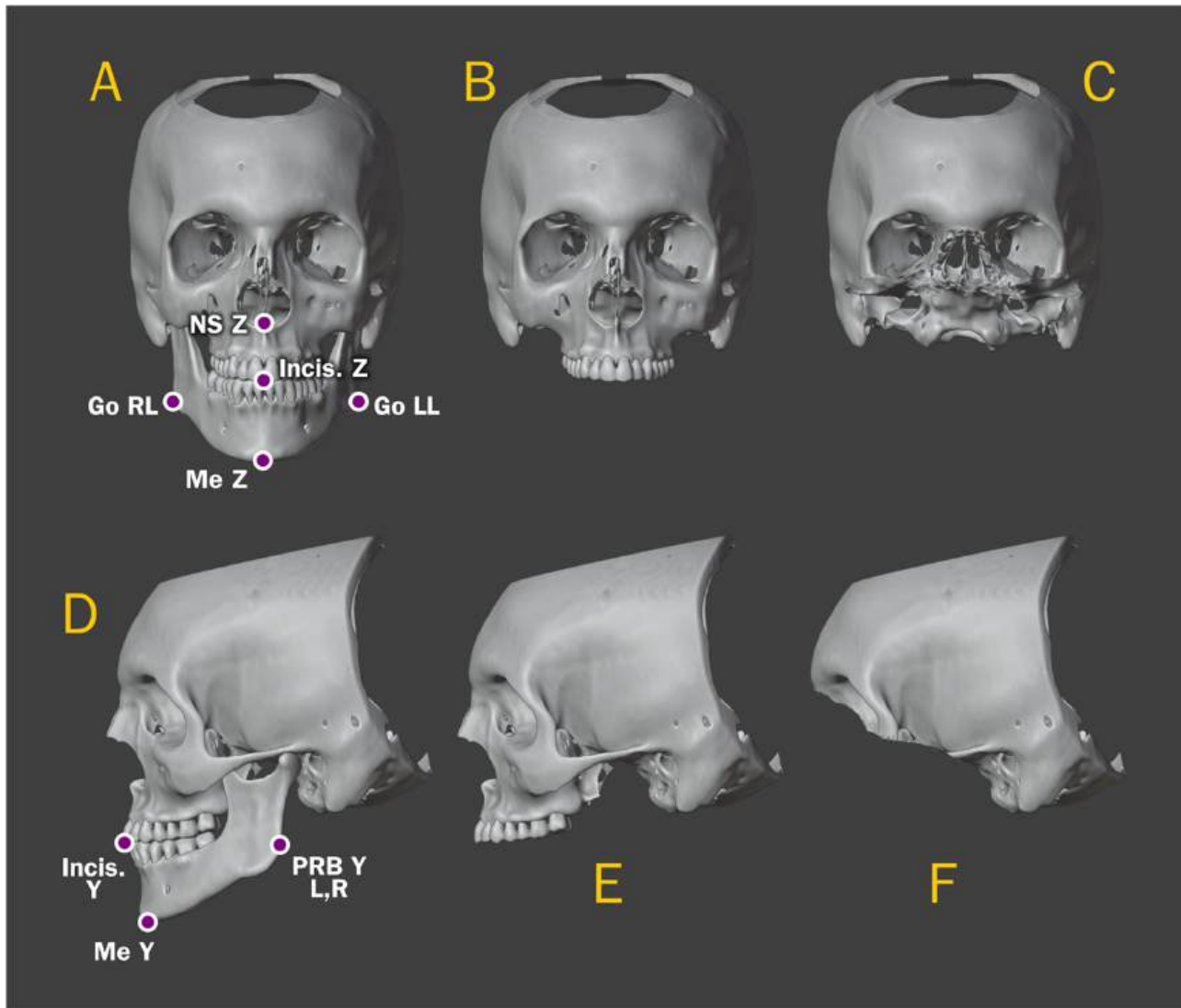


Figure 5. (A,D) Complete skull with the evaluated landmarks. (B,E) The same skull, but without the mandible. (C,F) The same skull, but without a significant part of the viscerocranium.

The previous study indicated that the projections made using the approach described in Moraes et al. (2022) and Moraes and Suharski (2022) [25,26] were consistent along the X and Z axes (horizontal and vertical), with the greatest discrepancy in the Y axis (depth), a direction that was not evaluated at the incisor and chin points. The reconstruction of the skull from a smaller available portion was better at two points, compared to one from the reconstruction of only the mandible, demonstrating that a greater absence of structure may not necessarily imply a greater projection error (see Tables 1 and 2). The survey also indicated that the standard deviation of the measurements made in the reconstructions, in relation to the original models, is smaller than that of the general studies mentioned above, which served as a basis for the application of “reverse engineering” for the projection of the missing regions.

Table 1. Comparison of complete model vs. mandibular reconstruction.

Landmark	Average (mm)	SD	SD (Moraes & Suharschi, 2022) [26]
Me Z	−1.9	2.9	7.6
Me Y	5.7	3.7	
Go RL	−0.2	3.3	
Go LL	−0.2	2.6	
Go Average	−0.2	2.5	6.0
PBR YR	1.8	2.4	
PRB YL	0.7	2.8	
PRB Average	1.3	2.2	

Table 2. Comparison of complete model vs. viscerocranium reconstruction.

Landmark	Average (mm)	SD	SD (Moraes & Suharschi, 2022) [26]
NS	−0.6	2.0	3.2
Incis. Z	−0.9	2.4	5.1
Incis. Y	−1.5	4.5	
Me Z	−0.5	4.9	7.6
Me Y	4.2	2.1	
Go RL	−0.6	3.1	
Go LL	0.1	2.7	
Go Average	−0.2	2.5	6.0
PBR YR	1.8	3.3	
PRB YL	2.3	2.6	
PRB Average	2.0	2.4	

The information gathered in the preliminary study showed that, although there is no absolute certainty about what a skull might look like, by following the statistical projections, while respecting the limits of the remaining structure, there is a good chance of getting closer to what it would look like in reality. Armed with this information and aware of its limitations, the team continued with the process of facial approximation.

The skull (Figure 6A) is composed of a frontal bone, parietal bones, the squama of the occipital bone, the right temporal bone, and part of the calf of the nasal bones [19]. Since it is an incomplete skull, it was necessary to reconstruct the missing region to enable the FFA process. A mirroring on the X axis of the structure allowed a discrete structural completion, which allowed the visualization of the frontomalar orbital points (fmo-fmo) (Figure 6B). Some anatomical landmarks were reported (fmo-fmo, g, n), and a projection system available in ForensicOnBlender traced the expected limits of some soft tissue structures (position of the eyeballs, horizontal dimension of the lips, and inferior limit of the nasal wings) and bones (horizontal limit of the gonions, inferior limit of the incisors, and inferior limit of the chin) (Figure 6C) [20,21]. The skull from the computed tomography scan of a virtual donor was reconstructed [22] and adjusted to the limits reported by the projection algorithm based on 44 measures took on 102 persons (<https://bit.ly/3NRw2KW> accessed on 13 November 2024) with the two biological sexes (Figure 6D). Important

anthropological data such as sex, age, potential injury structures, and others were extracted from [19].

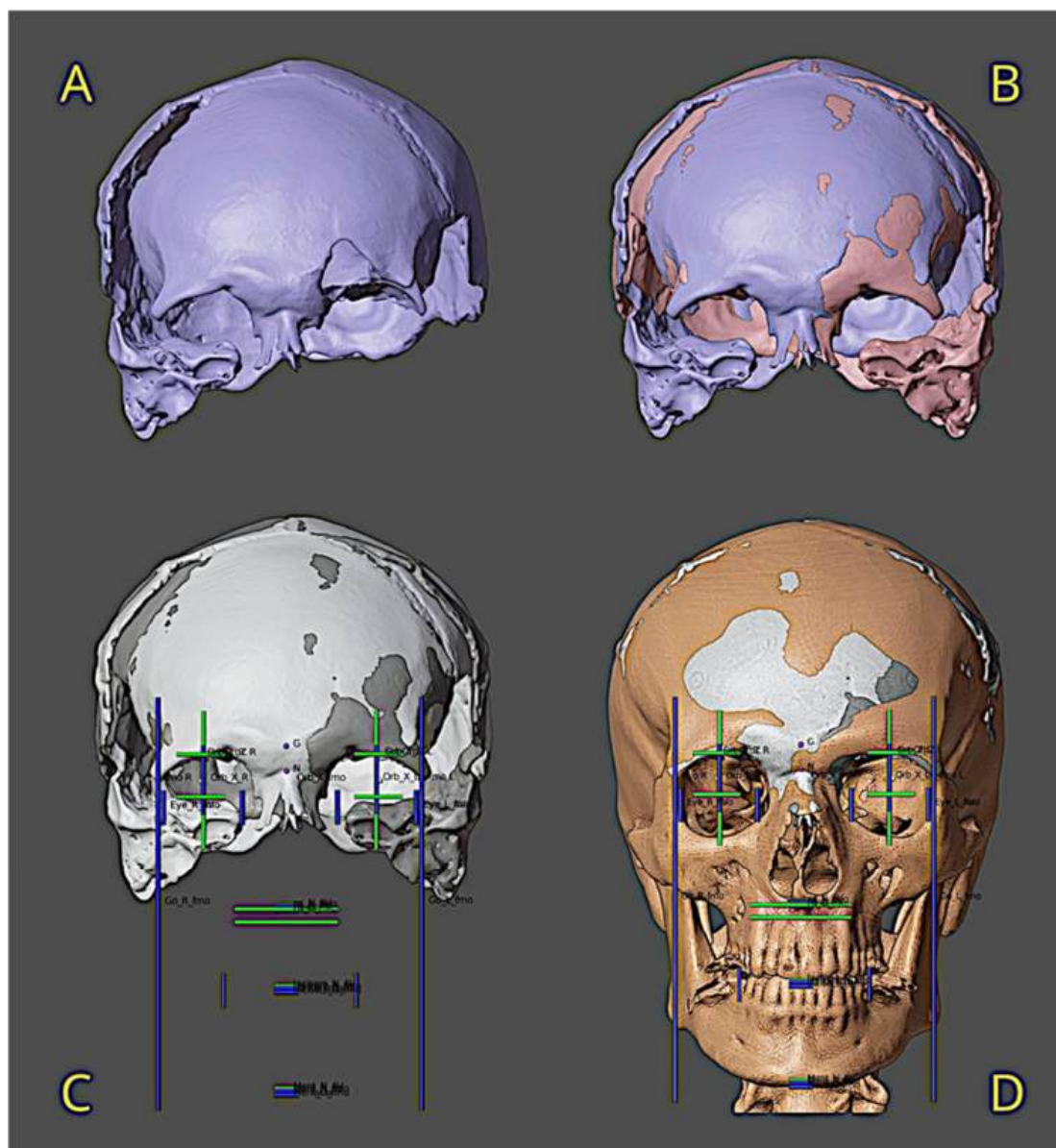


Figure 6. Reconstruction of the missing parts of the skull. (A) Original piece. (B) Mirrored structure. (C) Missing part projections. (D) Skull complete reconstruction.

Once the skull was complete, it was possible to position more anatomical landmarks and generate all the projections available in ForensicOnBlender (Figure 7A). For a practical understanding of how the solution works, two video lessons on structural projections are available online: lesson 1 (<https://youtu.be/U6oYkEmfyWo> accessed on 13 November 2024), lesson 2 (<https://youtu.be/Vcz2e5uSFX8> accessed on 13 November 2024). A series of soft tissue thickness markers, derived from a population sample of adult European men aged 50–59 years, was distributed along the surface of the skull (Figure 7B). This table was chosen because it is a survey carried out on living individuals, which allows for a more coherent projection than that of tables based on cadavers. Furthermore, it is a generic European population, with no description of nationality [28]. The projection of the nose was performed using a complementary methodology based on data collected from CT scans of living individuals [26,29], allowing, together with the data from the soft tissue markers, a

preliminary profile of the face to be drawn (Figure 7C). The level of nasal decay (Figure 7D), in relation to age, was measured and adjusted according to data from [30]. A video lecture on the nasal projection technique can be accessed online (<https://youtu.be/F205kLQ--Oo> accessed on 13 November 2024).

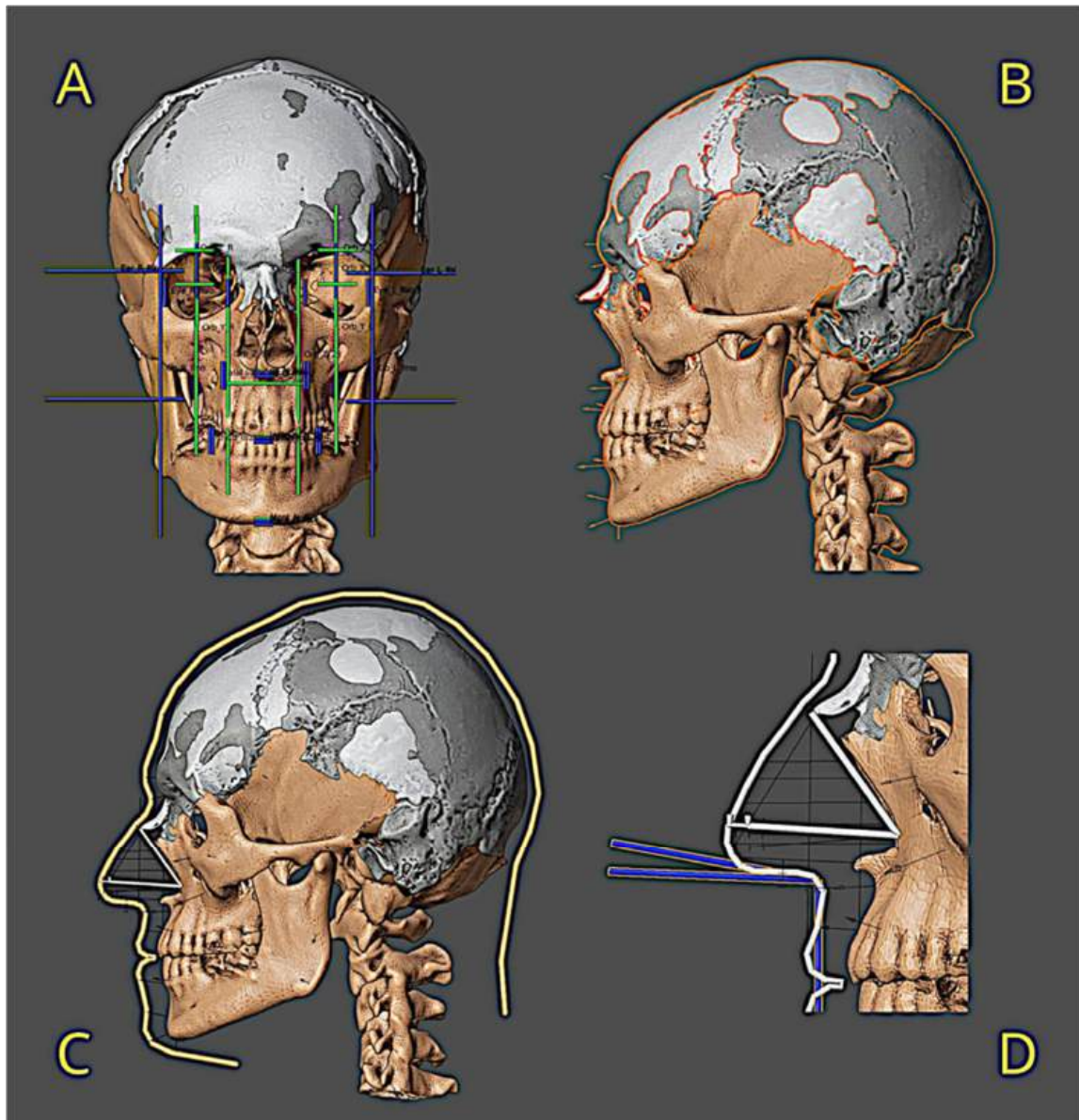


Figure 7. Initial steps of facial approximation. (A) All projections by anatomical points. (B) Soft tissue markers. (C) Profile face draw. (D) Nose point rotation corrected by age.

To complement the approximation data, the anatomical deformation technique [21,23] was used, which consists of importing a composite head (skull, soft tissue, and endocast) from a virtual donor (Figure 8A) and deforming/adjusting the donor's skull until it is compatible with the skull to be approximated, reflecting such changes to the soft tissue, allowing the interpolation of the data from the projection of the anterior profile with that provided by the anatomical deformation to result in a basic face (Figure 8B,C). A video lesson addressing anatomical "deformation" can be accessed online. The basic face undergoes a digital sculpting process, receiving expression marks compatible with age, as well as the scar from the injury to the left eye [31], in addition to the hair, eyebrows, mustache and beard (Figure 8D). Since this is a project for exhibition purposes in the

context of museums, the face and eyes are pigmented according to data on the average facial features of adult Czech men, generated by image composition from searches on image websites (see [19]), so the process involves more speculative elements and does not necessarily reflect what would have been seen in life. Clothing was modeled with data provided by the classical iconography attributed to the historical character (Figure 1) and the scene was lit to generate the final images (Figure 8E). Videos illustrating the digital pigmentation and hair configuration processes are available online.

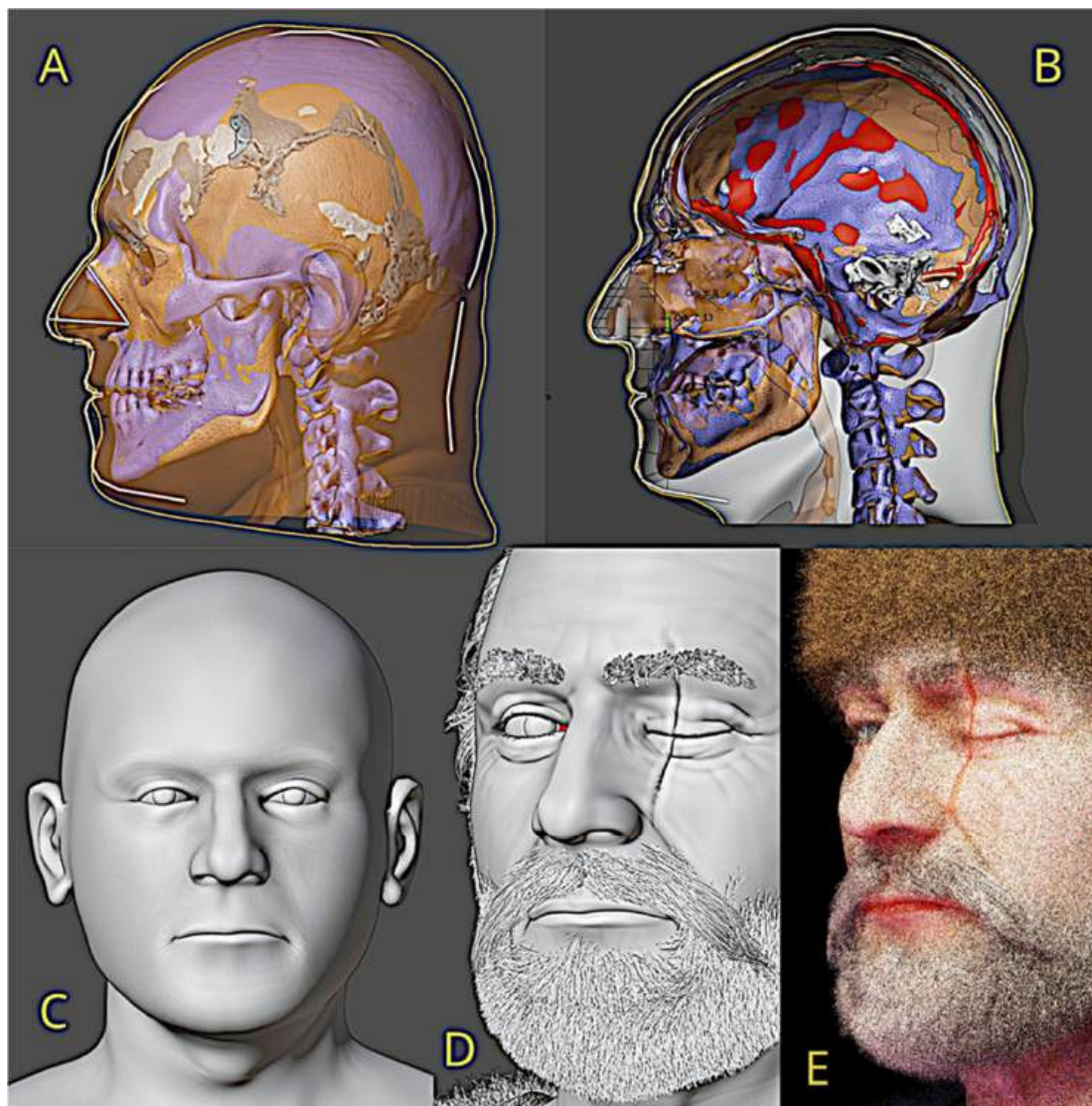


Figure 8. Final steps of facial approximation. (A) Virtual donor head imported. (B) Anatomical deformation done. (C) Final basic bust. (D) Hair, beard, mustache, and other facial hair setup. (E) Scene rendering.

3. Results

Three groups of images were created:

1. Objective FFA (Figure 9A–C);
2. Colored bust (Figure 10A–C);
3. Complete artistic FFA with AI detailing, this is a version with increased detail via the Leonardo AI application (<https://app.leonardo.ai/> accessed on 13 November 2024) and manual adjustments made in the Gimp image editor (<https://www.gimp.org/>

accessed on 13 November 2024). To better appreciate the details, it is necessary to observe such images closely (Figure 11A–C).

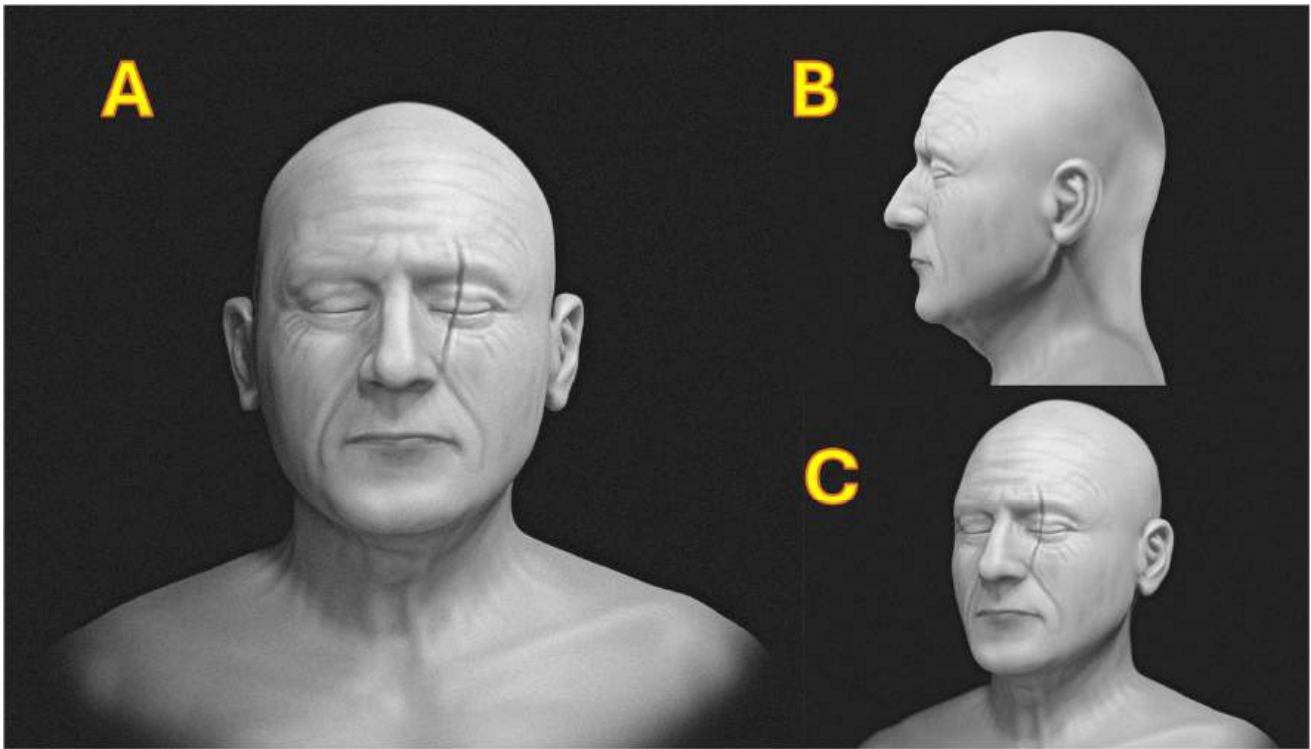


Figure 9. Objective FFA containing only the face mesh, with the eyes closed (since the shape of the eyes and their color/tone are not known for sure), without hair (since their distribution and shape are not known), and in grayscale (since there are no data on skin color). (A) Frontal view, (B) lateral view, and (C) three-quarter view.

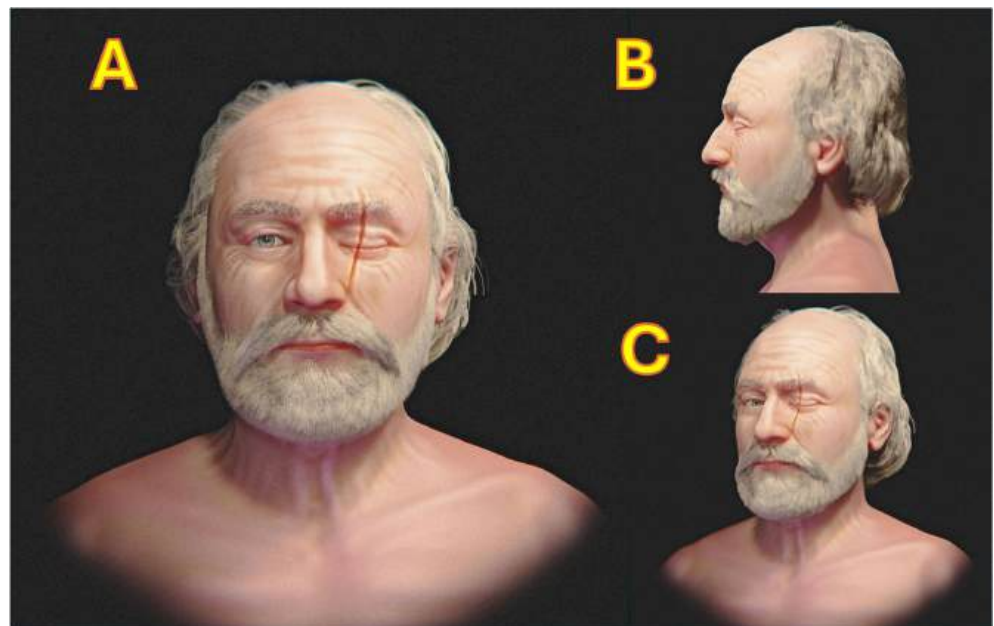


Figure 10. Colored bust, containing the bust with one eye open, hair, mustache, beard, and eyebrows with the appropriate pigmentations. (A) Frontal view, (B) lateral view, and (C) three-quarter view.

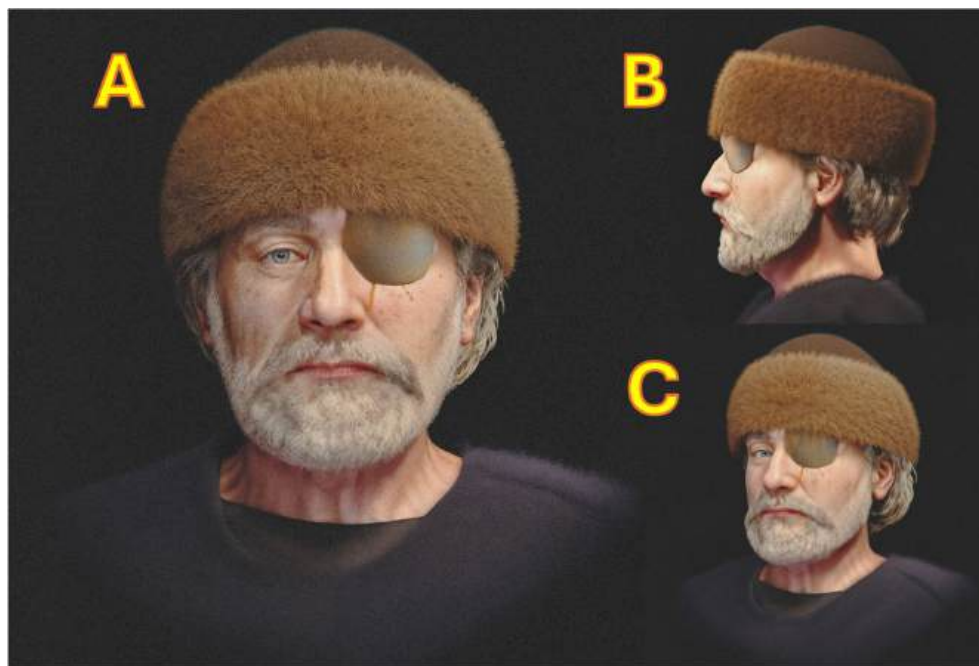


Figure 11. Complete artistic FFA with AI detailing. (A) Frontal view, (B) lateral view, and (C) three-quarter view.

4. Discussion

The most obvious fact about the current work is that there is only a part of the skull assigned to Jan Žižka and that the lack of a significant region certainly raises questions about the accuracy of the projection performed to recover what could be the complete structure. Something partially similar to what happened in the case of the facial approximation of Saint Ludmila, also studied by Dr. Emanuel Vlček and whose skull was approximated by the anthropologist in the 1990s. Interestingly, the specialist's cranial reconstruction was within the parameters of statistical projection and the facial approximation was compatible with current techniques, duly published in a peer-reviewed journal [22].

In her book, *Forensic Facial Reconstruction*, Caroline Wilkinson addresses, in chapter 6, the problems related to the reconstruction of missing parts of the skull, indicating that it would be possible to reconstruct several parts of that anatomical structure and present a model close to the original, with the exception of the mandible region, which generated a greater difference. For this study, only six skulls were used. Even so, this approach was cited in one of the most popular books on forensic facial reconstruction as a reference [27]. In this article, it was possible to present the results of a preliminary study using 10 skulls, which were reconstructed twice each, resulting in 20 approximations, 10 of which were only of the mandible and the other 10 of a significant part of the splanchnocranium. The results showed good compatibility between the reconstructions and the original skulls, in the measurements addressed in the study by Moraes et al. (2022) and Moraes and Suharschi (2022) [25,26], which were the basis for the projections made from the remnant of the alleged skull of Jan Žižka. The exception was precisely the projection that was not studied, that is, the distances on the Y axis that present more discrepancy. But frontally, that is, in relation to the X and Z axes, the projections proved to be quite reliable.

Although this does not guarantee that the approximated skull is completely similar to the original, the chance of it being compatible is quite reasonable, and is therefore not the result of random work, but centered on statistical, anatomically coherent data.

In the case of the present work, although it seems to be the same situation as the skull reconstruction of Ludmila of Bohemia, it has more data in the nose region, allowing a more

accurate lateral approximation, and the lack of data in the lower part was partially resolved by the configuration of the mustache and beard, which cover a significant part of the region, naturally hiding the maxilla and mandible.

The projection technique has been shown to be consistent with average skull structures and was even compatible with the structural reconstruction of the incomplete skull of Zlatý kůň, originally performed with other, widely published tools, demonstrating the coherence of the proposal available via *ForensicOnBlender* [32]. Even though the data from the structural projections, combined with the anatomical deformation technique, come from groups with individuals of different ancestries, the practical results have shown great anatomical coherence with the approximated skull, including in unprecedented cases, such as the approximation of a Polish man from the medieval period with achondroplasia. Even though the data used did not come from a group with achondroplasia, the approach generated a face with the expected characteristics, demonstrating structural coherence [19]. The technique, however, like any other based on statistical data, has its margins of error and standard deviations. It is essential that these characteristics be explained so that the limitations are known. Since these are reconstructions intended for presentation in religious and museum contexts, in both the case of Saint Ludmila and Jan Žižka, there is no excessive pressure on structural accuracy. However, even in critical cases such as approximation in the effective forensic context, that is, cases of murder or disappearance, there is the possibility of reconstructing highly fragmented skulls with a significant chance of recognition. One case that can be used as an example is a skull with a significant region of the splanchnocranium missing, found in 1999 in a remote Avocado Grove in San Diego, California. The structure lacked the nasal opening, the zygomatic bones, no maxilla, and a small part of the mandible. In 2002, a structural reconstruction of the skull, followed by facial approximation, generated images of the face and the entire body, with some pieces of clothing found at the scene. Although it did not produce a face perfectly compatible with the individual in life, the work was sufficient for there to be recognition and subsequent identification of the crime victim [33]. Therefore, the approach used to approximate the missing parts of the alleged skull of Jan Žižka, although it is not a forensic work (with crime victim), strictly followed the techniques that would be applied in a formal approach for the identification of a crime victim. Unfortunately, the complete skull is not available, which would be an ideal scenario, but on the other hand, even with the aforementioned limitations, it is possible to project the missing regions with a satisfactory degree of accuracy, especially in frontal and slightly lateral views. Until the other remains are found, if they are ever found, at least for now, this is the most coherent approach presented so far, with the detailed process and available sources, and there is nothing to prevent other work, with more robust and precise data, from being done in the future.

Another question that is raised with some constancy is that related to the authenticity of the skull in relation to the individual to whom it is attributed. Regarding the alleged skull of Jan Žižka, the arguments in favor may be those related to the study of the 1980s by Dr. Vlček, which indicated that it was a male individual between 40 and 60 years old who would have suffered two injuries to the eyes, one with bone healing that occurred at a young age and the other close to death, denoting, according to the researcher, a combination of factors rarely seen in other contexts [31]. In addition to such data, a radiocarbon dating carried out in the year 2024 seems to corroborate the year of death in 1424 [13], reinforcing the elements in favor (that is different to prove) of the thesis that it would have belonged to the notorious Bohemian general.

The solution to the doubt could be resolved with a DNA test, but there is no guarantee of success, just considering the case of the tests carried out on the hair and supposed skull of Nicolaus Copernicus [34], which raised great debate [35], and the case of the test carried

out on the skull that would be Mozart's, comparing the sample with two supposed relatives of his, and in the end, all the samples were unrelated to each other, further increasing the mystery that has dragged on for centuries [36,37].

Regarding the use of the artificial intelligence tool to detail the final images, when viewed from a distance, there is not much difference between the original version and the one refined by AI. However, when viewed closer, it is possible to see significant detail, especially in relation to expression marks, facial hair, and the brightness of the eyes, which, together, make the figure more human, with an aspect of liveliness. However, there are some problems with the tool, such as the need for manual edits for structural corrections in the eyes, facial hair, and others, since the algorithm, although it works very well, still generates some structural errors. Even so, the tool allowed for a level of detail that, if done completely manually, would significantly increase the execution time.

5. Conclusions

This study presented an approach based on statistical and anatomical data to initially seek the reconstruction of the alleged skull of Jan Žižka and subsequently its facial approximation, using as a basis the examinations carried out by Dr. Emanuel Vlček with the remains of the physical skull in the 1980s. Although on the one hand, a series of limitations guided the choices and results, on the other hand, it was possible to present some advances in facial approximation techniques, such as that related to the reconstruction of missing regions. The preliminary study demonstrated that there is a tendency for the projections to be compatible with the complete skull, which may be a motivating element for further studies with a larger sample. It is recommended to carry out further studies on depth projections, but it is important to note that frontal and slightly lateral views of the face are more reliable than profile views, unless the reconstructed face has a beard, as in the case of the alleged Jan Žižka, which would reduce this incompatibility in artistic versions of the works, as it would hide the region with lateral imprecision. Furthermore, the use of artificial intelligence to increase details was successful in its objective, demonstrating that, as long as it is supervised by a specialist and does not distort the original structure, it can be a powerful tool for increasing productivity and the quality of the work, giving more vivacity to the face that will be presented to the museum public.

Note: A preprint, open-access version of this study was posted online at the online repository (link to Ortogon in Portuguese, https://ortogonline.com/doc/pt_br/OrtogOnLineMag/10/Zizka.html accessed on 13 November 2024), and the facial reconstruction was presented to the media.

Author Contributions: Conceptualization, C.M., J.Y.A. and M.V.; methodology, C.M.; software, C.M.; validation, J.Š., M.Š., Z.T., T.B. and J.S.; writing—original draft preparation, C.M. and J.Y.A.; writing—review and editing, J.Y.A. and T.B.; visualization, F.M.G.; resources, F.M.G. and Z.T.; project administration, J.Š., M.Š. and J.S. All authors have read and agreed to the published version of the manuscript.

Funding: This research received no external funding.

Institutional Review Board Statement: Not applicable.

Informed Consent Statement: Not applicable.

Data Availability Statement: Data are available upon request.

Acknowledgments: To Richard Gravalos and Davi Sandes Sobral, for providing the CT scans used in this study (anatomical deformations and image illustration). A pre-print preliminary version of this study was posted on the website OrtogOnLine on 5 October 2024 (https://ortogonline.com/doc/pt_br/OrtogOnLineMag/10/Zizka.html).

Conflicts of Interest: Author Cicero Moraes was employed by the company Ortoonline Treinamento em Desenvolvimento Profissional e Consultoria Ltda. The remaining authors declare that the research was conducted in the absence of any commercial or financial relationships that could be construed as a potential conflict of interest.

References

1. Jan, C.Ž. The Editors of Encyclopaedia Britannica. Available online: <https://www.britannica.com/biography/Jan-Count-Zizka> (accessed on 12 December 2024).
2. Redacao Filme Sobre Combatente Tcheco Jan Žižka É Uma Das Produções Mais Vistas Na Netflix. Aventuras na História. Available online: <https://bit.ly/4716tHo> (accessed on 12 December 2024).
3. Pekař, J. *Žižka a Jeho Doba. Díl 2 (Jan Žižka)*; Vesmir: Prague, Czech Republic, 1928.
4. Vlček, E. *Jak Zemřeli: Významné Osobnosti Českých Dějin z Pohledu Antropologie a Lékařství*; Academia: Prague, Czech Republic, 1993.
5. Porák, J. *Ze Starých Letopisů Českých*; Svoboda: Prague, Czech Republic, 1980.
6. Černá, A.; Čornej, P.; Klosová, M. *Staré Letopisy České 2.: Východočeská Větev a Některé Související Texty*; Series Nova 2nd ed. Fontes Rerum Bohemicarum: Prague, Czech Republic, 2003.
7. Čornej, P. *Jan Žižka: Život a Doba Husitského Válečníka*; Paseka: Prague, Czech Republic, 2019.
8. Umění, Č.A.V.A.; Komise, A. *Nález Kostí Lidských v Kosteletě sv. Petra a Pavla v Čáslavi Jež Pokládány za Pozůstatky Jana Žižky z Trocnova*; Nákl. Archeologické Komise Při České Akademii Císaře Františka Josefa pro Vědy Slovesnost a Umění; OBP: Osaka, Japan, 1892.
9. Vlček, E. *Čáslavská Kalva-Pravděpodobný Pozůstatek Jana Žižky z Trocnova-v Konfrontaci s Historickými Prameny*; Jihočeský Sborník Historický: Čáslav, Czech Republic, 1974.
10. Vlček, E. *Čáslavská Kalva-Zpráva o Novém Prozkoumání tzv. Čáslavského Nálezu*; Památky Archeologické LIX; Archeologický ústav AV ČR: Prague, Czech Republic, 1968.
11. Rosa, E.O.; Crosato, E.M.; Castro, C.C.; Oliveira, R.E.; Biazzevic, M.G.H. Comparative study of sex estimates in adult skulls using direct measurement and tomographic image reconstruction. *Braz. Oral Res.* **2023**, *37*, e064. [[CrossRef](#)] [[PubMed](#)]
12. Musilová, B.; Dupej, J.; Brůžek, J.; Bejdová, Š.; Velemínská, J. Sex and ancestry related differences between two Central European populations determined using exocranial meshes. *Forensic Sci. Int.* **2019**, *297*, 364–369. [[CrossRef](#)] [[PubMed](#)]
13. UJF AMS Measurements of the Calva from Čáslav Presented at the Exhibition. Available online: <https://www.ujf.cas.cz/en/news/AMS-measurements-of-the-Calva-from-Caslav-presented-at-the-exhibition/> (accessed on 12 December 2024).
14. Stephan, C.N. Facial Approximation—From Facial Reconstruction Synonym to Face Prediction Paradigm. *J. Forensic Sci.* **2015**, *60*, 566–571. [[CrossRef](#)] [[PubMed](#)]
15. Pereira, J.G.D.; Magalhães, L.V.; Costa, P.B.; Silva, R.H.A. Reconstrução facial forense tridimensional: Técnica manual vs. técnica digital. *Rev. Bras. De Odontol. Leg. (RBOL)* **2017**, *4*, 46–54. [[CrossRef](#)]
16. Baldasso, R.P.; Moraes, C.; Gallardo, E.; Stumvoll, M.B.; Crespo, K.C.; Strapasson, R.A.P.; de Oliveira, R.N. 3D forensic facial approximation: Implementation protocol in a forensic activity. *J. Forensic Sci.* **2021**, *66*, 383–388. [[CrossRef](#)] [[PubMed](#)]
17. Nalewicki, J. Weathered Face of ‘Old Man’ Neanderthal Comes to Life in Amazing New Facial Reconstruction. Available online: <https://www.livescience.com/archaeology/weathered-face-of-old-man-neanderthal-comes-to-life-in-amazing-new-facial-reconstruction> (accessed on 12 December 2024).
18. Geggel, L. This Stone Age Man’s Jawless Skull Was Found on a Spike. Here’s What He Looked Like. Available online: <https://www.livescience.com/stone-age-man-facial-reconstruction.html> (accessed on 12 December 2024).
19. Moraes, C.; Krenz-Niedbała, M.; Łukasik, S.; Prada, C.S. Forensic facial approximation of an individual with achondroplasia from medieval cemetery in Central Europe. *Digit. Appl. Archaeol. Cult. Herit.* **2024**, *32*, e00301. [[CrossRef](#)]
20. Anderson, S. See the Face of a Woman Who Died in a Shipwreck in 1628. Available online: <https://www.smithsonianmag.com/smart-news/see-face-woman-who-died-1628-vasa-shipwreck-sweden-180982603> (accessed on 12 December 2024).
21. Abdullah, J.Y.; Moraes, C.; Saidin, M.; Rajion, Z.A.; Hadi, H.; Shahidan, S.; Abdullah, J.M. Forensic Facial Approximation of 5000-Year-Old Female Skull from Shell Midden in Guar Kepah, Malaysia. *Appl. Sci.* **2022**, *12*, 7871. [[CrossRef](#)]
22. Moraes, C.; Šindelář, J.; Galassi, F.M.; Beaini, T.L. Ludmila of Bohemia (ca. 860–921): Multidisciplinary considerations on her facial approximation. *Digit. Appl. Archaeol. Cult. Herit.* **2023**, *29*, e00263. [[CrossRef](#)]
23. Quatrehomme, G.; Cotin, S.; Subsol, G.; Delingette, H.; Garidel, Y.; Grévin, G.; Fidrich, M.; Baillet, P.; Ollier, A. A fully three-dimensional method for facial reconstruction based on deformable models. *J. Forensic Sci.* **1997**, *42*, 649–652. [[CrossRef](#)] [[PubMed](#)]
24. Pinto, R.R.; Almeida, S.M.D.; Chaves, R.B.D.N.; Carvalho, O.A.D.; Machado, M.P.S.; Moraes, C. Reconstrução Facial Forense de um Crânio Arqueológico com o ForensicOnBlender. 2020. Available online: https://ortogonline.com/doc/pt_br/OrtogOnLineMag/1/Forense.html (accessed on 13 November 2024).

25. Moraes, C.; Gravalos, R.; Machado, C.R.; Chilvarquer, I.; Curi, J.; Beaini, T.L. Investigação de Preditores Anatômicos para o Posicionamento dos Globos Oculares, Asas Nasais, Projeção dos Lábios e Outros a Partir da Estrutura do Crânio. 2022. Available online: https://ortogonline.com/doc/pt_br/OrtogOnLineMag/4/Projecoes.html (accessed on 12 December 2024).
26. Moraes, C.; Suharschi, I. Mensuração de Dados Faciais Ortográficos em Moldavos e Comparação com Outras Populações. 2022. Available online: https://ortogonline.com/doc/pt_br/OrtogOnLineMag/4/Moldavos.html (accessed on 12 December 2024).
27. Wilkinson, C. Forensic Facial Reconstruction. In *6-The Manchester Method of Facial Reconstruction*; Cambridge University Press: Cambridge, UK, 2004.
28. De Greef, S.; Claes, P.; Vandermeulen, D.; Mollemans, W.; Suetens, P.; Willems, G. Large-scale in-vivo Caucasian facial soft tissue thickness database for craniofacial reconstruction. *Forensic Sci. Int.* **2006**, *159*, S126–S146. [[CrossRef](#)] [[PubMed](#)]
29. Moraes, C.; Sobral, D.S.; Mamede, A.; Beaini, T.L. Sistema Complementar de Projeção Nasal em Reconstruções/Aproximações Faciais Forenses. 2021. Available online: https://ortogonline.com/doc/pt_br/OrtogOnLineMag/3/NarizProjecao.html (accessed on 12 December 2024).
30. Shastri, D.; Tandon, P.; Singh, A. Nasal changes in different age groups. *Natl. J. Maxillofac. Surg.* **2021**, *12*, 367–371. [[CrossRef](#)] [[PubMed](#)]
31. Vlček, E. *Kosterní Pozůstatky Jana Žižky z Trocnova*; Staletá: Prague, Czech Republic, 1984; Volume XIV.
32. Bogdanowicz, W.; Allen, M.; Branicki, W.; Lembring, M.; Gajewska, M.; Kupiec, T. Genetic identification of putative remains of the famous astronomer Nicolaus Copernicus. *Proc. Natl. Acad. Sci. USA* **2009**, *106*, 12279–12282. [[CrossRef](#)] [[PubMed](#)]
33. Sołtysiak, A.; Kozłowski, T. Komentarz do Identyfikacji Cranium 13/05 z Fromborka Jako Kości Mikołaja Kopernika. *Archeol. Pol.* **2009**, *2*, 281–290.
34. Obscura, A. Mozart's Skull. Available online: <https://www.atlasobscura.com/places/university-mozarteum> (accessed on 12 December 2024).
35. Harding, L. DNA Detectives Discover More Skeletons in Mozart Family Closet. Available online: <https://www.theguardian.com/world/2006/jan/09/arts.music> (accessed on 12 December 2024).
36. Moraes, C.; Galassi, F.M.; Sineo, L.; Šindelář, J.; Varotto, E.; Mietlińska-Sauter, J.; Antunes-Ferreira, N.; Habicht, M.E.; Beaini, T. The anatomical bases of the 3D digital facial approximation of the Zlatý kůň 1 woman (ca. 43,000 BP). *Anthropol. Rev.* **2024**, *87*, 85–97. [[CrossRef](#)]
37. Taylor, K.T. Forensic Reconstruction-Valley Center Jane Doe. Available online: <https://www.behance.net/gallery/620676/Forensic-Reconstruction-Valley-Center-Jane-Doe> (accessed on 12 December 2024).

Disclaimer/Publisher's Note: The statements, opinions and data contained in all publications are solely those of the individual author(s) and contributor(s) and not of MDPI and/or the editor(s). MDPI and/or the editor(s) disclaim responsibility for any injury to people or property resulting from any ideas, methods, instructions or products referred to in the content.