



# Percutaneous pedicle screw fixation without arthrodesis of 368 thoracolumbar fractures: long-term clinical and radiological outcomes in a single institution

Sokol Trungu<sup>1,2</sup> · Luca Ricciardi<sup>2</sup> · Stefano Forcato<sup>1</sup> · Amadeo Piazza<sup>2</sup> · Giancarlo D'Andrea<sup>3</sup> · Filippo Maria Polli<sup>4</sup> · Marco Cimatti<sup>2</sup> · Alessandro Frati<sup>5</sup> · Massimo Miscusi<sup>2</sup> · Antonino Raco<sup>2</sup>

Received: 4 April 2022 / Revised: 15 July 2022 / Accepted: 20 July 2022

© The Author(s), under exclusive licence to Springer-Verlag GmbH Germany, part of Springer Nature 2022

## Abstract

**Purpose** Traumatic thoracolumbar (TL) fractures are the most common vertebral fractures. Although a consensus on the preferred treatment is missing, percutaneous pedicle screw fixation (PPSF) has been progressively accepted as treatment option, since it is related to lower soft tissues surgical-injury and perioperative complications rate. This study aims to evaluate the long-term clinical–radiological outcomes after PPSF for TL fractures at a single tertiary academic hospital.

**Methods** This is a retrospective cohort study. Back pain was obtained at preoperative, postoperative and final follow-up using Visual Analog Scale. Patient-reported outcomes, the Oswestry Disability Index and the 36-Item Short Form, were obtained to assess disability during follow-up. Radiological measures included Cobb angle, mid-sagittal index, sagittal index (SI) and vertebral body height loss. A multivariate regression analysis on preoperative radiological features was performed to investigate independent risk factors for implant failure.

**Results** A total of 296 patients with 368 TL fractures met inclusion criteria. Mean follow-up was 124.3 months. The clinical and radiological parameters significantly improved from preoperative to last follow-up measurements. The multivariate analysis showed that Cobb angle (OR = 1.3,  $p < 0.001$ ), SI (OR = 1.5,  $p < 0.001$ ) and number of fractures (OR = 1.1,  $p = 0.05$ ), were independent risk factors for implant failure. The overall complication rate was 5.1%, while the reoperation rate for implant failure was 3.4%.

**Conclusions** In our case series, PPSF for TL injuries demonstrated good long-term clinical-radiological outcomes, along with low complication and reoperation rates. Accordingly, PPSF could be considered as a valuable treatment option for neurologically intact patients with TL fractures. Additionally, in this cohort, number of fractures  $\geq 2$ , Cobb angle  $\geq 15^\circ$  and sagittal index  $\geq 21^\circ$  were independent risk factors for implant failure.

**Keywords** Thoracolumbar fracture · Percutaneous pedicle screw fixation · Burst fracture · Minimally invasive surgery · Posterior short-segment fixation

✉ Sokol Trungu  
s\_trungu@hotmail.com

<sup>1</sup> Neurosurgery Unit, Cardinale G. Panico Hospital, Via Fratelli Peluso 8, 73039 Tricase, Italy

<sup>2</sup> N.E.S.M.O.S. Department, Sant'Andrea Hospital, Sapienza University of Rome, Rome, Italy

<sup>3</sup> Neurosurgery Unit, F. Spaziani Hospital, Frosinone, Italy

<sup>4</sup> Department of Neurosurgery, Fondazione Policlinico Universitario Agostino Gemelli - IRCCS, Rome, Italy

<sup>5</sup> Neurosurgery, Neuromed IRCCS, Pozzilli, Italy

## Abbreviations

TL	Thoracolumbar
PPSF	Percutaneous pedicle screw fixation
CT	Computed tomography
MIS	Minimally invasive surgery
MSI	Mid-sagittal index
MRI	Magnetic resonance imaging
ODI	Oswestry Disability Index
PLC	Posterior ligamentous complex
SI	Sagittal index
VAS	Visual analog scale
VBHL	Vertebral body height loss

## Introduction

Traumatic thoracolumbar (TL) fractures represent the most common fractures of the spine. Up to 50–60% of these fractures involve the TL junction (T10–L2), 25–45% the thoracic spine, and 10–14% the lumbosacral spine [1, 2]. The compression-burst fractures (type A, AOSpine Thoracolumbar Spine Injury Classification System [3, 4]) are the most common (60–70%) subtype, followed by distraction injuries (type B—14–21%), and rotational injuries (type C—4–16%) [5].

Minimally invasive surgery (MIS) has been progressively accepted as a treatment option for spine fractures. Several studies have compared posterior percutaneous screw fixation (PPSF) techniques with traditional open surgery, concluding that PPSF is associated with shorter surgical duration and hospital stay, lower intraoperative blood loss and infection rates, and lower surgical-related injury to spinal muscles [6, 11]. On the other hand, no significant differences were reported concerning radiological and clinical outcomes of these techniques [12, 13].

Recently, the Congress of Neurological Surgeons (CNS) guidelines have recommended to carefully consider the role of arthrodesis in these procedures, since osteosynthesis alone seems to provide similar clinical and radiological outcomes [14]. Posterior short-segment fixation has demonstrated as effective in restoring spinal stability, correcting kyphotic deformity, and indirectly decompressing the spinal canal in TL fractures [15–20]. However, there are no conclusive long-term clinical-radiological data in TL fractures management.

The aim of this study was to evaluate the long-term clinical and radiological outcomes of 296 neurologically intact patients with 368 TL fractures who underwent PPSF without arthrodesis at a single institution. To the best of our knowledge, our data are based on the largest cohort of patients, from a single-institution, and the longest clinical and radiological follow-up.

## Methods

### Study design

This is a retrospective cohort study from a single institution. According to the study design and national and institutional guidelines, the ethical committee approval was not required. At the time of hospitalization, all the patients provided their written informed consent for surgery and data management for scientific purposes. This study agrees with the WMA Helsinki declaration of Human Rights.

## Patient population

Patients admitted at our tertiary academic referral center for traumatic TL fractures who underwent PPSF, between March 2007 and March 2015 (8 years), were considered for eligibility.

Inclusion criteria were: traumatic TL fractures classified according to the AOSpine Thoracolumbar Spine Injury Classification System; neurologically intact (ASIA E); follow-up > 6 years.

Exclusion criteria were: incomplete clinical and radiological data; history of severe osteoporosis (DEXA—T-score of –2.5 or lower and presence of one or more fragility fractures, as defined by the World Health Organization); previous TL surgery; non-traumatic fractures; < 6 years follow-up.

## Surgical technique

A standard technique for percutaneous screw placement was performed in all patients. A convergent and straightforward pedicle screw trajectory is preferred. After insertion of all screws, contouring of the rods is performed and these are inserted and locked in place.

Patients, with monosegmental burst fractures, were treated with short segment fixation (6 screws) using an instrumentation system involving one vertebra above, one below and at the fractured vertebra (in which either monolateral or bilateral pedicle screws were inserted according to local anatomy and pedicles status). Segmental lordosis restoration was always pursued in the case of segmental kyphosis with percutaneous distraction.

In cases of multiple fractures or type B fractures, the number of levels involved with pedicle screws depended on the type, level, number of fractures and deformity grade. Cannulated polyaxial screws were used in all patients. Screws' sizes ranged in length and diameter, from 30 to 55 mm and from 4.5 to 7.5 mm, respectively. Titanium rods sizes ranged in diameter from 5 to 6.5 mm. Different percutaneous instrumentation systems were used over years. Bracing was never prescribed after surgery in any case. Implant removal was not performed in any patients of this study.

## Clinical outcomes

General and neurological conditions, as well as the quality of life, were evaluated at admittance (preoperative parameters), 6 weeks, one year, 6 years after surgery, and at final follow-up visit, using a ten-points itemized visual analog scale (VAS) for low-back pain. Patient reported outcomes were evaluated at 6 weeks, one year, 6 years after surgery and final follow-up visit to assess disability using the Oswestry Disability Index (ODI) score and the short-form SF-36 score.

Trauma types and mechanisms (motor vehicle collision, sports trauma, work/domestic fall, diving) were recorded. Thoracolumbar AOSpine Injury (TL AOSIS) [21] classification was recorded for each fracture. Intra-, post-operative and during follow-up complications were collected and classified as major and minor as described by Glassman et al. [22].

## Radiological outcomes

Preoperative X-rays and computed tomography (CT) scan were retrieved from institutional picture archiving and communication system (PACS). Preoperative magnetic resonance imaging (MRI) was performed only in cases suspicious for posterior ligamentous complex injury.

The following radiological parameters were calculated and collected: the mid-sagittal index (MSI)—the percentage of loss of the anteroposterior diameter of the spinal canal at the fractured vertebra level related to the same mean value at the overlying and underlying levels [23]; the Cobb angle—the angle between a line drawn parallel to the superior end plate of one vertebra above the fracture and a line drawn parallel to the inferior end plate of the vertebra one level below the fracture [24]; the sagittal index (SI)—the measurement of segmental kyphosis at the level of a mobile segment (1 vertebra and 1 disc) adjusted for the baseline sagittal contour at that level [25] and vertebral body height loss (VBHL)—measured by anterior/posterior body height compression ratio [24].

Screw misplacement was evaluated on postoperative CT scan and classified as by Gertzbein et al. [26]. The presence of screw breakage, screw pullout, peri-implant loosening, and rod breakage were considered as criteria for implant failure.

## Statistical analysis

Values were reported as mean  $\pm$  standard deviation. The *t*-Student test was used to compare the quantitative continuous variables. Fisher's exact test (2-sided) was used instead to compare the categorical variables. Statistical significance was pre-determined at an alpha of 0.05. Univariate and Multivariate binary logistic regression analysis with odds ratio (OR) was performed to evaluate independent radiological risk factors for implant failure. Furthermore, for the independent factors, a decision tree was performed to calculate cut-off values and 2  $\times$  2 contingency table for OR. SPSS Statistics 14.0 (SPSS Inc, Richmond, CA, USA) was used for data analysis.

## Results

### Patient and operative characteristics

A total of 296 patients who underwent PPSF for 368 traumatic TL fractures during the study period met the inclusion criteria and were included for data analysis.

There were 126 (42.6%) women and 170 (57.4%) men. The mean age at the time of surgery was  $46.2 \pm 19.3$  years (range 15–86). The mean follow-up was  $124.3 \pm 26.1$  months (range 78–174). The most common co-morbidity was cardiovascular diseases (49.3%), followed by diabetes mellitus (33.4%), obesity (29.4%) and respiratory diseases (13.8%). Ninety-six patients (32.4%) were smokers. Ninety-two patients were classified as ASA Class I (31.1%), 149 (50.3%) as Class II, 45 (15.2%) as Class III and 10 (3.4%) as Class IV.

The main traumatic mechanism was car/motorbike accident (66.2%), followed by professional-related injuries (13.5%), sport activities (8.4%), domestic accidents (7.8%) and diving (4.1%).

According to the recent AOSpine Classification, the cohort included 76 A3-type fractures (20.7%), 234 A4-type fractures (63.6%), 36 B1 type (9.8%), 16 B2 type (4.3%) and 6 B3 type fractures (1.6%). The most frequent fractured level was the thoracolumbar junction T10–L2 in 179 patients (53.3%), followed by thoracic spine T4–T9 in 108 (32.1%), and lumbar spine L3–L5 in 49 (14.6%). Two hundred and thirty-three patients (78.7%) had one fracture, whereas 54 (18.2%) and 9 patients (3.1%) had two and three fractures, respectively. The mean TL AOSIS was 5 (range 3–8).

The mean length of surgery was  $54.1 \pm 23.8$  min (range 30–150), with an average of  $46.6 \pm 15.2$  ml (range 30–110 ml) of estimated blood loss (EBL). The mean length of stay (LOS) was 3 days ( $2.6 \pm 3.6$ ; range 2–40) and the mean time of postoperative mobilization was 2 days ( $1.5 \pm 3.1$ ; range 2–30). No intraoperative complications were recorded. Two hundred and fifty-five patients (86.1%) were discharged to home, while 13.9% of patients to a rehabilitation unit.

Patients demographic and operative characteristics are summarized in Tables 1 and 2.

### Clinical and radiological outcomes

Comparing mean preoperative and last follow-up values a significant improvement was found in VAS score ( $7.6 \pm 1.3$ – $1.6 \pm 0.9$ ,  $p < 0.001$ ), ODI score at 6 weeks ( $22.4 \pm 6.4$ ) improved to  $17.4 \pm 6.2$  ( $p < 0.05$ ) at last follow-up and the SF-36 score ( $62.7 \pm 7.1$ – $73.6 \pm 6.1$ ,

**Table 1** Patient characteristics

Total no. of patients	296
Mean age $\pm$ SD, yrs (range)	46.2 $\pm$ 19.1 (15–86)
Mean follow-up $\pm$ SD, mos (range)	124.3 $\pm$ 26.1 (78–174)
<i>Sex</i>	
Female	126 (42.6%)
Male	170 (57.4%)
<i>ASA classification</i>	
I	92 (31.1%)
II	149 (50.3%)
III	45 (15.2%)
IV	10 (3.4%)
V	0
<i>Comorbidity</i>	
Cardiovascular diseases	146 (49.3%)
Diabetes mellitus	99 (33.4%)
Obesity	87 (29.4%)
Respiratory diseases	41 (13.8%)
Smokers	96 (32.4%)
<i>Traumatic mechanism</i>	
Car/motorbike accident	196 (66.2%)
Work activity	40 (13.5%)
Sport activity	25 (8.4%)
Domestic activity	23 (7.8%)
Diving	12 (4.1%)

ASA, American Society of Anesthesiologists

$p < 0.05$ ), showed good clinical outcomes with no disability during long-term follow-up. Clinical outcomes are resumed in Table 3.

Thirty-nine out of the 2048 (1.9%) implanted screws had a pedicle breach  $> 2$  mm (grade C or more); however, only two screws were replaced for occurrence of postoperative radiculopathy.

The Cobb angle (preop  $10.2^\circ \pm 5.6$  vs  $4.7^\circ \pm 3.6$  at follow-up,  $p < 0.001$ ) and SI (preop  $16.4^\circ \pm 7.2$  vs  $8.7^\circ \pm 5.0$  at follow-up,  $p < 0.001$ ) improved significantly after surgery and were maintained at follow-up. Similarly, the MSI (preop  $52.2\% \pm 19.1$  vs  $3.4\% \pm 2.8$  at follow-up,  $p < 0.001$ ) and the VBHL ratio (preop  $0.55 \pm 0.16$  vs  $0.60 \pm 0.19$  at follow-up,  $p < 0.001$ ) improved significantly after surgery. Radiological outcomes are resumed in Table 4. An illustrative case is presented in Fig. 1.

### Complications and reoperation rate

No major or minor intra-operative complications were registered. Fifteen complications were recorded (overall complication rate of 5.1%). Ten patients had a major complication that needed a revision surgery: 2 patients (0.7%) experienced a nerve root radiculopathy with complete resolution after

replacement of the screw and 8 patients (2.7%) with implant failure. Five minor complications (1.7%) were observed: 5 patients had a superficial wound infection with complete resolution within 2 weeks after surgery.

Ten patients required reoperation (overall reoperation rate of 3.4%): two patients needed a revision surgery for screw misplacement, and 8 patients needed a revision surgery for implant failure (6 patients for screw pull-out, 1 rod dislocation and 1 screw breakage) during follow-up.

### Subgroup analysis of preoperative radiological parameters for implant failure

In univariate analysis, preoperative MSI (OR = 1.1; 95% CI [1.03–1.16];  $p = 0.002$ ); and VBHL (OR = 0.95; 95% CI [0.64–1.13];  $p = 0.334$ ) were not related to implant failure. Additionally, number of fractures (OR = 1.18; 95% CI [1.03–1.16];  $p = 0.0038$ ); Cobb angle (OR = 1.4; 95% CI [1.2–1.6];  $p < 0.001$ ); and SI (OR = 1.5; 95% CI [1.2–1.7];  $p < 0.001$ ).

The multivariate regression analysis showed that number of fractures (OR = 1.1; 95% CI [1.01–1.2];  $p = 0.05$ ), preoperative Cobb angle (OR = 1.3; 95% CI [1.12–1.62];  $p < 0.001$ ) and SI (OR = 1.5; 95% CI [1.23–1.72];  $p < 0.001$ ) were independent factors for implant failure. Moreover, a decision tree with cut off values showed that Cobb angle  $\geq 15^\circ$  (OR = 9.5; 95% CI [2–45.5];  $p = 0.005$ ) and SI  $\geq 21^\circ$  (OR = 39.6; 95% CI [4.9–319.1];  $p = 0.0006$ ) predicts implant failure. The univariate and multivariate analysis for implant failure are resumed in Table 5.

### Discussion

Although TL fracture were historically managed using the standard open surgery for obtaining segmental fusion, associated to a decompression of the spinal canal when needed, the evolution of surgical techniques and instrumentation implants have provided alternatives such as percutaneous PPSF. This has demonstrated as effective as standard open surgery in terms of clinical-radiological outcomes, while providing valuable surgical advantages [7, 8]. Accordingly, spine surgeries for TL fractures has been progressively changed with the adoption of minimally invasive surgery (MIS) for the management of these patients [27–31].

In cases of burst fractures, indirect decompression can be obtained with the ligamentotaxis, consisting in the tension of the posterior longitudinal ligament during distraction, and segmental lordorization, promoting the self-repositioning of the dislocated bone fragments which are pushed forward [32–34]. The additional screws into the fractured vertebra provide a supplementary hyperlordorizing force, eventually ameliorating segmental kyphosis correction grade.

**Table 2** Operative characteristics

	Nr. (%)
Total no of fractures	368
Total no of screws	2048
<i>Type of fracture (AOSpine classification)</i>	
A3	76 (20.7%)
A4	234 (63.6%)
B1	36 (9.8%)
B2	16 (4.3%)
B3	6 (1.6%)
<i>Level of fracture</i>	
Thoracic (T4–T9)	108 (32.1%)
Thoracolumbar junction (T10–L2)	179 (53.3%)
Lumbar (L3–L5)	49 (14.6%)
<i>Nr of fractures in a single patient</i>	
One	233 (78.7%)
Two	54 (18.2%)
Three	9 (3.1%)
<i>Complications</i>	
Minor	5 (1.7%)
Major	10 (3.4%)
Overall complication rate	5.1%
<i>Implant failure</i>	
Rod dislocation	1 (0.34%)
Screw breakage	1 (0.34%)
Screw pull-out	6 (2%)
Screw misplacement	39 (1.9%)*
<i>Reoperation rate</i>	
Implant failure	8 (2.7%)
Screw misplacement	2 (0.7%)
Overall reoperation rate	3.4%
	Nr. (range)
Mean Thoracolumbar AOSpine Injury Score (TL AOSIS)	5 (3–8)
Mean length of surgery $\pm$ SD, min (range)	54.1 $\pm$ 23.8 (30–150)
Mean length of stay $\pm$ SD, days (range)	2.6 $\pm$ 3.6 (2–40)
Mean time of postoperative mobilization, $\pm$ SD, days (range)	1.5 $\pm$ 3.1 (2–30)
Estimated blood loss (EBL) $\pm$ SD, mL (range)	46.6 $\pm$ 15.2 (30–110)

\*Calculated from 2048 total screws

Furthermore, it seems to increase the bone healing rate in mid-term, then reducing chances for segmental kyphosis [19].

Our results confirm data from the pertinent literature, in terms of good surgical, clinical and radiological outcomes after PPSF for TL fractures [9, 10, 13]. In the present series, PPSF provided a significant pain relief after surgery, along with lower disability grade. Furthermore, these clinical and functional improvements were still significant in a long-term follow-up, as long as 10 years (range 78–174 months). Accordingly, we firstly reported how PPSF in TL fractures

management is able to provide long-term good results, in terms of clinical outcomes.

The evaluation of radiological parameters has demonstrated that segmental deformity correction, MSI, SI and VBHL result as maintained over the follow-up, as matter of proof of segmental stability. Furthermore, short-segment instrumentation, including the fractured vertebra and the two contiguous ones, revealed to be effective in maintaining correction even in TL junction (T10–L2), as measured in 179 patients (53.3%). No cases of implants failure or adjacent segment degeneration were reported in these patients

**Table 3** Clinical outcomes

	Mean $\pm$ SD
<i>Visual Analogue Scale (VAS)</i>	
Preoperative	7.6 $\pm$ 1.3
Postoperative (6 weeks)	2.5 $\pm$ 1.9
Follow-up at 1 years	2.2 $\pm$ 0.8
Follow-up at 6 years	1.9 $\pm$ 1.0
Last follow-up	1.6 $\pm$ 0.9
<i>p</i> value (pre vs follow-up)	<0.001
<i>Oswestry Disability Index (ODI)</i>	
Preoperative	N/A
Postoperative (6 weeks)	22.4 $\pm$ 6.4
Follow-up at 1 years	16.2 $\pm$ 5.6
Follow-up at 6 years	17.7 $\pm$ 5.8
Last follow-up	17.4 $\pm$ 6.2
<i>p</i> value (post vs follow-up)	<0.001
<i>SF-36 (physical and mental)</i>	
Preoperative	N/A
Postoperative (6 weeks)	62.7 $\pm$ 7.1
Follow-up at 1 years	78.4 $\pm$ 6.6
Follow-up at 6 years	75.3 $\pm$ 5.9
Last follow-up	73.6 $\pm$ 6.1
<i>p</i> value (post vs follow-up)	<0.001

and an anterior approach does not seem justified. A recent meta-analysis confirms these results showing no difference radiological and functional outcomes between the anterior and posterior approaches with longer duration and estimated blood loss in the anterior one [35].

A planned implant removal is not systematically adopted in our institution. The removal is agreed with sportive agonistic patients only, while second surgeries for removing the implants are reserved to those patients complaining for the instrumentation and were not included in this study. Nowadays, there exists ongoing debate if patients with posterior fixation with or without arthrodesis of thoracolumbar fractures should have their implants routinely removed on follow-up [36–38]. However, in this cohort, the implant retention did not lead to disability and lower functional outcomes during the 10 years of follow-up, probably due to the short-segment instrumentation used in most patients. Moreover, the multivariate logistic regression on preoperative radiological parameters showed how number of fractures (OR = 1.1), preoperative Cobb angle (OR = 1.3) and SI (OR = 1.5) were independent risk factors for implant failure. Additionally, a decision tree model showed that nr. of fractures  $\geq 2$ , preoperative Cobb angle  $\geq 15^\circ$  and sagittal index  $\geq 21^\circ$  could predict the subset of patients that could have an implant failure during follow-up and benefit from a different approach.

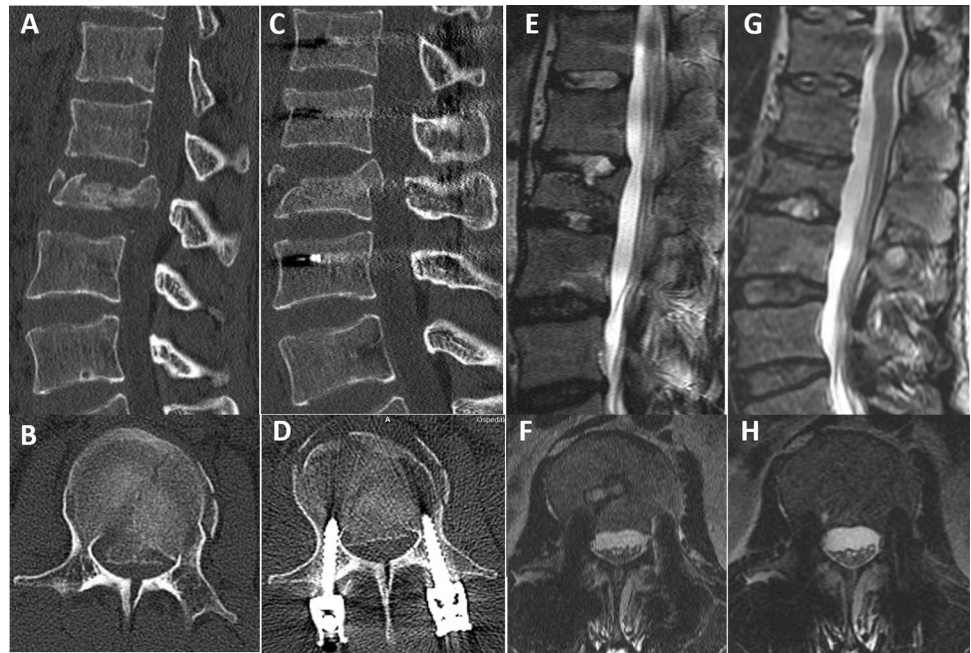
**Table 4** Radiological outcomes

	Mean $\pm$ SD
<i>Mid-Sagittal Index (MSI)%</i>	
Preoperative	52.2 $\pm$ 19.1
Postoperative (6 weeks)	36.5 $\pm$ 14.3
Follow-up at 1 years	6.1 $\pm$ 4.7
Follow-up at 6 years	3.5 $\pm$ 2.9
Last follow-up	3.4 $\pm$ 2.8
<i>p</i> value (pre vs fu)	<0.001
<i>Cobb's Angle</i> $^\circ$	
Preoperative	10.2 $\pm$ 5.6
Postoperative (6 weeks)	5.4 $\pm$ 4.1
Follow-up at 1 years	4.6 $\pm$ 3.5
FOLLOW-up at 6 years	4.2 $\pm$ 3.8
Last follow-up	4.7 $\pm$ 3.6
<i>p</i> value (pre vs fu)	<0.001
<i>Sagittal Index (SI)</i> $^\circ$	
Preoperative	16.4 $\pm$ 9.2
Postoperative (6 weeks)	10.4 $\pm$ 6.1
Follow-up at 1 years	9.7 $\pm$ 5.5
Follow-up at 6 years	8.0 $\pm$ 5.2
Last follow-up	8.7 $\pm$ 5.0
<i>p</i> value (pre vs fu)	<0.001
<i>Vertebral body height loss (VBHL) ratio</i>	
Preoperative	0.55 $\pm$ 0.16
Postoperative (6 weeks)	0.58 $\pm$ 0.18
Follow-up at 1 years	0.59 $\pm$ 0.20
Follow-up at 6 years	0.64 $\pm$ 0.21
Last follow-up	0.60 $\pm$ 0.19
<i>p</i> value (pre vs fu)	<0.001

In the over twenty years experience on this, we have developed an internat protocol on the management of neurologically intact patients with TL fractures and invasion of the spinal canal in which we do never perform decompression, while obtaining the indirect decompression using ligamentotaxis as described above. A recent systematic review strengthened that surgical maneuvers to promote segmental fusion do not improve clinical or radiological outcomes, but they are associated with increased surgical time and higher intraoperative bleeding [39].

In terms of complications, our data showed that PPSF for traumatic TL fractures report a relatively low complication and reoperation rates. The overall complication rate was 5.1% (15 patients): 10 patients with major complications that needed a revision surgery and 5 patients with minor complications (superficial wound infection). The reoperation rate was 3.4% (10 patients): in 2 cases one screw was repositioned and in 8 patients we documented implant breakage or pull-out.

**Fig. 1** A 34-year-old patient with a diagnosis of an A4 L2 fracture who had no neurological deficits. The preoperative sagittal (a) and axial (b) CT scan shows 88% spinal canal invasion. (b) The postoperative sagittal (c) and axial (d) CT scan at the 1-year follow-up shows percutaneous fixation with intermediate pedicle screws. The sagittal (e) and axial (f) MRI scan at the 5-year follow-up shows vertebral body restoration and correction of the kyphosis angle without spinal canal invasion. The sagittal (g) and axial (h) MRI scan at 10-years of follow-up



**Table 5** Radiological predictors of implant failure

Risk factors	Univariate analysis			Multivariate analysis*		
	OR	CI 95%	<i>p</i> value	OR	CI 95%	<i>p</i> value
Nr of fractures	1.182	(1.106–1.437)	0.0038	1.102	(1.011–1.412)	0.0495
Type of fracture	1.063	(0.951–1.151)	0.293			
Cobb angle	1.405	(1.198–1.647)	<0.001	1.307	(1.124–1.615)	<0.001
SI	1.452	(1.227–1.719)	<0.001	1.452	(1.227–1.719)	<0.001
MSI	1.006	(0.971–1.041)	0.755			
VBHL	0.946	(0.641–1.131)	0.334			

\*Backward stepwise (conditional) method in binary logistic regression analysis, not significant factors are eliminated during analysis

To the best of our knowledge, this study retrieved data from the largest cohort of patients operated for TL fractures using PPSF, with the longest follow-up (mean follow-up of 10 years) in the international literature. Our results confirm that PPSF can be considered as an effective and reproducible technique for safely managing TL fractures, providing valuable clinical and radiological outcomes, and long-term segmental stability. Short segment fixations, involving as few levels as possible, could be an alternative to longer implants preserving spinal mobility, thus reducing surgical-mediated restrictions of spinal range of motion. Furthermore, we firstly documented how clinical and radiological outcomes are maintained over 10 years, with a relatively low complication and reoperation rates. Lastly, the multivariate logistic regression on preoperative radiological parameters showed that nr. of fractures  $\geq 2$ , preoperative Cobb angle  $\geq 15^\circ$  and sagittal index  $\geq 21^\circ$  are independent risk factors for implant failure.

### Limitations of this study

There are few limitations to be disclosed. The present investigation consists of a single center, retrospective study, which has to be considered for a proper data interpretation. Additionally, our study included different types of fractures (type A and B) and the number of levels instrumented was highly heterogeneous, and this may influence the relevance of our results. At last, the subgroup analysis for independent risk factors for implant failure was evaluated only for the preoperative radiological parameters. Further studies including patients' characteristics, radiological parameters and subgroup analysis for different type of fractures are necessary to better evaluate risk factors.

## Conclusions

Percutaneous pedicle screw fixation without arthrodesis showed excellent long-term clinical and radiological outcomes, along with a relatively low complication and reoperation rates, in TL fractures management. Accordingly, PPSF without arthrodesis could be considered as a valuable treatment for neurologically intact patients with TL fractures. Additionally, number of fractures  $\geq 2$ , Cobb angle  $\geq 15^\circ$  and sagittal index  $\geq 21^\circ$  were independent risk factors for implant failure. Further randomized comparative studies are necessary to confirm these results.

**Funding** There was no financial support for this study.

## Declarations

**Conflict of interest** All authors have nothing to declare.

## References

- Hu R, Mustard CA, Burns C (1996) Epidemiology of incident spinal fracture in a complete population. *Spine (Phila Pa 1976)* 21:492–499
- Holmes JF, Miller PQ, Panacek EA et al (2001) Epidemiology of thoracolumbar spine injury in blunt trauma. *Acad Emerg Med* 8:866–872
- Vaccaro AR, Oner C, Kepler CK et al (2013) AOSpine thoracolumbar spine injury classification system: fracture description, neurological status, and key modifiers. *Spine* 38:2028–2037
- Urrutia J, Zamora T, Yurac R et al (2015) An independent inter-observer reliability and intraobserver reproducibility evaluation of the new AOSpine thoracolumbar spine injury classification system. *Spine* 40:E54–E58
- Wood KB, Li W, Lebl DS et al (2014) Management of thoracolumbar spine fractures. *Spine J* 14:145–164
- Dai LY, Jiang SD, Wang XY et al (2007) A review of the management of thoracolumbar burst fractures. *Surg Neurol* 67:221–231
- Phan K, Rao PJ, Mobbs RJ (2015) Percutaneous versus open pedicle screw fixation for treatment of thoracolumbar fractures: systematic review and meta-analysis of comparative studies. *Clin Neurol Neurosurg* 135:85–92
- McAnany SJ, Overley SC, Kim JS et al (2016) Open versus minimally invasive fixation techniques for thoracolumbar trauma: a meta-analysis. *Global Spine J* 29:186–194
- Charles YP, Zairi F, Vincent C et al (2012) Minimally invasive posterior surgery for thoracolumbar fractures. New trends to decrease muscle damage. *Eur J Orthop Surg Traumatol* 22:1–7
- Wild MH, Gless M, Plieschnegger C et al (2007) Five-year follow-up examination after purely minimally invasive posterior stabilization of thoracolumbar fractures: a comparison of minimally invasive percutaneously and conventionally open treated patients. *Arch Orthop Trauma Surg* 127:335–343
- Sun XY, Zhang XN, Hai Y (2017) Percutaneous versus traditional and paraspinous posterior open approaches for treatment of thoracolumbar fractures without neurologic deficit: a meta-analysis. *Eur Spine J* 26:1418–1431
- Lee JK, Jang JW, Kim TW et al (2013) Percutaneous short-segment pedicle screw placement without fusion in the treatment of thoracolumbar burst fractures: is it effective?—comparative study with open short-segment pedicle screw fixation with posterolateral fusion. *Acta Neurochir (Wien)* 155:2305–2312
- Vanek P, Bradac O, Konopkova R et al (2014) Treatment of thoracolumbar trauma by short-segment percutaneous transpedicular screw instrumentation: prospective comparative study with a minimum 2-year follow-up. *J Neurosurg Spine* 20:150–156
- Chi JH, Eichholz KM, Anderson PA et al (2019) Congress of neurological surgeons systematic review and evidence-based guidelines on the evaluation and treatment of patients with thoracolumbar spine trauma: novel surgical strategies. *Neurosurgery* 84:E59–E62
- Li K, Li Z, Ren X et al (2016) Effect of the percutaneous pedicle screw fixation at the fractured vertebra on the treatment of thoracolumbar fractures. *Int Orthop* 40:1103–1110
- Kapoen C, Liu Y, Bloemers F et al (2020) Pedicle screw fixation of thoracolumbar fractures: conventional short segment versus short segment with intermediate screws at the fracture level—a systematic review and meta-analysis. *Eur Spine J* 29:2491–2504
- Norton RP, Milne EL, Kaimrajh DN et al (2014) Biomechanical analysis of four- versus six-screw constructs for short segment pedicle screw and rod instrumentation of unstable thoracolumbar fractures. *Spine J* 14:1734–1739
- Baaj AA, Reyes PM, Yaqoobi AS et al (2011) Biomechanical advantage of the index-level pedicle screw in unstable thoracolumbar junction fractures. *J Neurosurg Spine* 14:192–197
- Cimatti M, Forcato S, Polli FM et al (2013) Pure percutaneous pedicle screw fixation without arthrodesis of 32 thoracolumbar fractures: clinical and radiological outcome with 36-month follow-up. *Eur Spine J* 22:925–932
- Trungu S, Forcato S, Bruzzaniti P et al (2019) Minimally invasive surgery for the treatment of traumatic monosegmental thoracolumbar burst fractures: clinical and radiologic outcomes of 144 patients with a 6-year follow-up comparing two groups with or without intermediate screw. *Clin Spine Surg* 32:E171–E176
- Kepler CK, Vaccaro AR, Schroeder GD et al (2016) The thoracolumbar AOSpine injury score. *Global Spine J* 6:329–334
- Glassman SD, Hamill CL, Bridwell KH et al (2007) The impact of perioperative complications on clinical outcome in adult deformity surgery. *Spine* 32:2764–2770
- Keynan O, Fisher CG, Vaccaro A et al (2006) Radiographic measurement parameters in thoracolumbar fractures: a systematic review and consensus statement of the spine trauma study group. *Spine* 31:E156–E165
- Sadiqi S, Verlaan JJ, Lehr AM et al (2017) Measurement of kyphosis and vertebral body height loss in traumatic spine fractures: an international study. *Eur Spine J* 26:1483–1491
- Farcy JPC, Glassman SD (1990) Sagittal index in management of thoracolumbar burst fractures. *Spine* 15(9):958–965
- Gertzbein SD, Robbins SE (1990) Accuracy of pedicular screw placement in vivo. *Spine* 15:11–14
- Jaikumar S, Kim DH, Kam AC (2002) History of minimally invasive spine surgery. *Neurosurgery* 51(suppl\_2):S2–S1
- Pietrantonio A, Trungu S, Famà I et al (2019) Long-term clinical outcomes after bilateral laminotomy or total laminectomy for lumbar spinal stenosis: a single-institution experience. *Neurosurg Focus* 46:E2
- Miscusi M, Trungu S, Forcato S et al (2018) Long-term clinical outcomes and quality of life in elderly patients treated with interspinous devices for lumbar spinal stenosis. *J Neurol Surg A Cent Eur Neurosurg* 79:139–144
- Assaker R (2004) Minimal access spinal technologies: state-of-the-art, indications, and techniques. *Joint Bone Spine* 71(6):459–469



31. Trungu S, Ricciardi L, Forcato S et al (2021) Percutaneous instrumentation with cement augmentation for traumatic hyperextension thoracic and lumbar fractures in ankylosing spondylitis: a single-institution experience. *Neurosurg Focus* 51(4):E8
32. Leferink VJM, Nijboer JMM, Zimmerman KW et al (2003) Burst fractures of the thoracolumbar spine: changes of the spinal canal during operative treatment and follow-up. *Eur Spine J* 12:255–260
33. Yang H, Shi JH, Ebraheim M et al (2011) Outcome of thoracolumbar burst fractures treated with indirect reduction and fixation without fusion. *Eur Spine J* 20:380–386
34. Mueller LA, Mueller LP, Schmidt R et al (2006) The phenomenon and efficiency of ligamentotaxis after dorsal stabilization of thoracolumbar burst fractures. *Arch Orthop Trauma Surg* 126:364–368
35. Tan T, Rutges J, Marion T et al (2019) Anterior versus posterior approach in traumatic thoracolumbar burst fractures deemed for surgical management: systematic review and meta-analysis. *J Clin Neurosci* 70:189–197
36. Oh HS, Seo HY (2019) Percutaneous pedicle screw fixation in thoracolumbar fractures: comparison of results according to implant removal time. *Clin Orthop Surg* 11(3):291–296
37. Deckey JE, Bradford DS (2000) Loss of sagittal plane correction after removal of spinal implants. *Spine* 25(19):2453–2460
38. Kweh BTS, Tan T, Lee HQ et al (2022) Implant removal versus implant retention following posterior surgical stabilization of thoracolumbar burst fractures: a systematic review and meta-analysis. *Global Spine J* 12(4):700–718
39. Diniz JM, Botelho RV (2017) Is fusion necessary for thoracolumbar burst fracture treated with spinal fixation? A systematic review and meta-analysis. *J Neurosurg Spine* 27:584–592

**Publisher's Note** Springer Nature remains neutral with regard to jurisdictional claims in published maps and institutional affiliations.

Springer Nature or its licensor holds exclusive rights to this article under a publishing agreement with the author(s) or other rightsholder(s); author self-archiving of the accepted manuscript version of this article is solely governed by the terms of such publishing agreement and applicable law.