



Sub-Periosteal Peri-implant Augmented Layer technique to treat peri-implantitis lesions

Leonardo Trombelli ^{*,**}
Mattia Severi ^{*}
Roberto Farina ^{*,**}
Anna Simonelli ^{*}

^{*} Research Centre for the Study of Periodontal and Peri-Implant Diseases, University of Ferrara, Ferrara, Italy

^{**} Operative Unit of Dentistry, Azienda Unità Sanitaria Locale, Ferrara Italy

Corresponding Author: Prof. Leonardo Trombelli, Research Centre for the Study of Periodontal and Peri-implant Diseases, University of Ferrara, Corso Giovecca 203, 44121 Ferrara, Italy. Tel. +39 0532 688507, Fax +39 0532 202329, e-mail: leonardo.trombelli@unife.it.

Disclaimer: This study was supported by the Research Centre for the Study of Periodontal and Peri-Implant Diseases, University of Ferrara, Italy.

Word Count: 1296

N° of figures: 3

N° of tables: 2

Running title: SPAL technique to treat peri-implantitis lesions

One-sentence summary: SPAL technique may represent a suitable regenerative option to treat class Ib/c peri-implantitis defects.

For *Clinical Advances in Periodontics*, Ferrara March 29, 2020

This article has been accepted for publication and undergone full peer review but has not been through the copyediting, typesetting, pagination and proofreading process, which may lead to differences between this version and the [Version of Record](#). Please cite this article as [doi: 10.1902/cap.10107](https://doi.org/10.1902/cap.10107).

This article is protected by copyright. All rights reserved.

ABSTRACT

Introduction: The efficacy of surgical regenerative procedures to treat peri-implantitis lesions has been extensively reviewed. Regenerative treatment showed a variable rate of success, in terms of pocket reduction, gain in bone support and elimination of signs of infection/inflammation. The aim of the present case report is to illustrate the use of Sub-Periosteal Peri-Implant Augmented Layer (SPAL) technique to correct peri-implantitis defects

Case series: Surgical treatment of 3 class Ib and 1 class Ic peri-implantitis lesions in 3 patients was performed by mean of the SPAL technique. A partial-thickness flap was elevated, leaving the periosteal layer on the buccal cortical bone plate. The periosteal layer was in turn elevated to create a pouch, which was used to stabilize a bovine-derived xenograft (DBBM) at the peri-implant buccal bone defect. No barrier membrane was used. In case of insufficient dimensions of peri-implant mucosa, a connective tissue graft (CTG) was buccally positioned at the most coronal portion of the implant. Treatment resulted in substantial reconstruction of peri-implant support associated with reduced probing depth and absence of inflammation.

Conclusions: SPAL technique with or without additional CTG may be a suitable option to obtain clinical remission of peri-implantitis defects associated with buccal bone dehiscence.

Key Words: Peri-Implantitis, Dental implants, Bone regeneration, Surgical flaps

BACKGROUND

The efficacy of surgical regenerative procedures to treat peri-implantitis lesions has been extensively reviewed^{1,2}. Regenerative treatment showed a variable rate of success, in terms of pocket reduction, gain in bone support and elimination of signs of infection/inflammation, which seems partly dependent on the defect configuration³ and surgical procedure⁴. Among the proposed surgical options, the use of a deproteinized bovine bone mineral (DBBM) with 10% collagen with or without the additional use of a connective tissue graft (CTG) led to significant clinical improvements at crater-like peri-implant defects⁵, even when implant sites were re-evaluated long-term⁶.

Recently, a simplified technique for horizontal bone augmentation at implant placement, namely the Sub-periosteal Peri-implant Augmented Layer (SPAL), was proposed^{7,8}. SPAL technique is based on the use of periosteum to create a periosteal pouch which is used to stabilize DBBM at the deficient peri-implant buccal bone plate and was successfully used to increase the horizontal dimension of the peri-implant tissues in presence of a bone dehiscence or a thin buccal cortical plate at implant placement^{7,8}.

This case report illustrates the use of SPAL technique for the treatment of peri-implantitis lesions.

Clinical Presentation, Case Management, and Clinical Outcomes

Each patient provided a written informed consent prior to surgical treatment. All the clinical procedures have been performed in accordance with the Declaration of Helsinki and the Good Clinical Practice Guidelines (GCPs).

Patients were systemically healthy and enrolled in a professional recall program. The persistence of a 5 mm pocket associated with bleeding and/or suppuration and radiographic bone loss > 3 mm were regarded as indication for surgical correction. The morphology of the peri-implantitis defect was diagnosed by bone sounding and periapical radiographs.

This article is protected by copyright. All rights reserved.

Case #1

A 65 y-o, non-smoker male patient presenting a Class Ic peri-implantitis lesion⁹ at one rough-surface, tissue-level, cylindrical implant (Fig. 1a-c) was treated on June 2018. The patient was treated for a stage IV periodontitis and presents with no residual bleeding sites with probing depth (PDD) \geq 5 mm.

A partial thickness incision was performed intra-sulcularly at the buccal aspect of the implant and extended mesio-distally on the edentulous ridge. Two partial thickness oblique releasing incisions were then made mesially and distally. The mucosal layer was raised by sharp dissection, leaving the periosteal layer on both implant surface and peri-implant bone crest (Fig. 1d). The periosteal layer was carefully elevated by mean of tunneling knives[†] as well as by a periosteal elevator[‡], thus exposing the peri-implant bone defect and creating a periosteal pouch that could accommodate and stabilize a xenograft (Fig 1e.). A full-thickness flap was elevated on the palatal aspect. After degranulation, the defect was diagnosed as combined class Ic + II⁹ (Fig. 1f). The exposed implant surface was carefully debrided by an ultrasonic tip device[§] plus a specifically designed rotating titanium brush^{||} and finally cleaned with cotton pellets soaked in a 0.2% chlorhexidine solution. DBBM graft[¶] was used to fill the intrabony component, (Fig. 1g). The periosteal layer was then secured to the palatal flap by an internal mattress 6/0 resorbable suture[#] to contain and stabilize the graft up to the most coronal part of the peri-implant defect (Fig. 1h). The mucosal layer was then coronally advanced and sutured to provide wound stability (Fig. 1i).

[†] KPAX, TKN1X and TKN2X, Hu Friedy, Chicago, Illinois

[‡] PTROM, Hu-Friedy, Chicago, Illinois

[§] EMS Airflow Prophylaxis Master, EMS-Electro Medical System SA, Nyon, Switzerland

^{||} i-Brush, Neo Biotech, Rotterdam, The Netherlands

[¶] Bio-Oss® spongiosa granules, particle size 0.25-1.0 mm; Geistlich Pharma, AG, Wolhusen, Switzerland

Vicryl 6/0, Ethicon, Somerville NJ, USA

Case #2 and #3

On May 2019, a 50 y-o female patient (case 2) presenting a Class Ib peri-implantitis lesion⁹ at a rough-surface, tissue-level, tapered implant (Fig. 2a-c) was treated according to SPAL technique. Patient was affected by stage 2 periodontitis, treated before peri-implantitis surgical therapy.

Due to the lack of graft stability in the most coronal portion of the implant and the limited thickness of keratinized mucosa, a CTG was harvested from the palate¹⁰ and sutured over the coronal part of the xenograft and exposed implant surface (Fig. 2 d-g). The mucosal layer was coronally advanced and sutured to completely submerge the CTG (Fig. 2h).

On May 2018, a 44 y-o male patient, with no history of periodontitis (case 3), presenting two Class Ib peri-implantitis lesions⁹ at two rough-surface, tissue-level, cylindrical implants, was treated according to SPAL technique. Due to partial exposure of the DBBM graft coronal to the periosteal pouch following SPAL technique and lack of keratinized peri-implant mucosa, a CTG was harvested and sutured as in Case #2 and left partially exposed supragingivally in order to create a band of keratinized peri-implant mucosa and increase vestibule depth (Fig. 3 a-f).

Postoperative regimen

Patients were instructed not to brush the treated area for 2 weeks. A pain killer^{††} was prescribed as needed. A 0.12% chlorhexidine solution, 10 ml for 60 seconds b.i.d. was prescribed for 3 weeks. Sutures were removed at 2-weeks post-surgery. Successful therapy, defined as probing depth (PD) \leq 4 mm, absence of

bleeding/suppurative on probing and substantial radiographic bone gain, was observed at 6-months re-evaluation (Figs. 1 j-l, 2 i-k, 3 g-j and Table 1 and 2).

Brufen 600 mg, Abbott Laboratories, Abbott, Texas

DISCUSSION

The selection of SPAL technique to treat Class Ib/Ic peri-implantitis lesions was based on the reported effectiveness in augmenting horizontal bone dimensions at implant placement in presence of an overt implant dehiscence⁸. The stabilization of graft particles by the periosteal layer may have enhanced the conditions for clot stabilization and subsequently bone regeneration either in the intrabony component or at the buccal dehiscence. Moreover, the periosteum layer may have acted as a source of blood and osteogenic cells, contributing bone formation¹¹. The rationale for the use of a DBBM graft only was based on previous studies reporting relevant outcomes when the intrabony component of a peri-implant defect was exposed by a full-thickness flap and grafted by DBBM with^{3,12,13} or without^{5,6,14} an additional membrane. Although a radiographic bone fill of the peri-implantitis lesions was evident at 6 months, this evidence does not qualify the nature of the augmented tissues. Previous human histology derived from a similar procedure where a sub-periosteal pouch was surgically created revealed xenograft particles surrounded by newly formed bone.¹⁵

The decision to avoid the use of a membrane was also based on previous data¹⁶ where the application of a membrane to treat a peri-implantitis defect resulted costly, time consuming, technique sensitive and provided no clear added value.

The additional use of a CTG was based on previous studies on surgical regeneration of peri-implantitis defects^{3,14} where a full-thickness flap was raised to access the lesion and contaminated implant surface, bone defects were filled with a DBBM graft, and, in case of limited amount of keratinized mucosa, a CTG was used to

cover the defect. Although controversial data exists about the importance of keratinized peri-implant soft tissue to ensure peri-implant health, recent systematic reviews support the use of soft tissue augmentation at deficient sites to maintain long term peri-implant hard and soft tissue stability¹⁷. Overall, our findings seem to suggest that the use of a CTG to SPAL may be of additional benefit since i) it increased mucosa dimensions and (if left exposed) vestibule depth; ii) it contributed the stabilization of the portion of the graft coronal to the periosteal pouch; and iii) it supported the coronal displacement of the mucosal layer, thus enhancing wound stability conditions during tissue maturation phase. Further studies are needed to elucidate this hypothesis.

CONCLUSION

The present proof-of-principle case report indicates that SPAL technique with or without additional CTG may result in the clinical remission of Class Ib/Ic peri-implantitis defects. Whether and to what extent these beneficial effects may be maintained long-term and extended to other defect configurations needs be carefully assessed.

SUMMARY TABLE

<p>Why is this case new information?</p>	<ul style="list-style-type: none"> - A novel surgical procedure, namely the Sub-Periosteal Peri-Implant Augmented Layer (SPAL) technique, is described for the regenerative treatment of peri-implantitis lesions.
<p>What are the keys to successful management of this case?</p>	<ul style="list-style-type: none"> - Careful dissection of both the mucosal and the periosteal layer to maintain their integrity - Extensive decontamination of implant surface

	<ul style="list-style-type: none"> - Management of both periosteal and mucosal layers to stabilize the graft, create conditions for space provisioning and wound stability - Additional use of a connective tissue graft (CTG) to increase dimensions of peri-implant mucosa, when deficient or missing.
<p>What are the primary limitations to success in this case?</p>	<ul style="list-style-type: none"> - Thin buccal peri-implant mucosa, not allowing the separation of mucosal and periosteal layers - Morphology of the peri-implantitis lesion

ACKNOWLEDGEMENTS

The study was entirely supported by the Research Centre for the Study of Periodontal and Peri-implant Diseases, University of Ferrara, Italy. M. S., R.F. and A. S. declare no conflict of interest. L.T. received grants and fee for lectures and courses by Geistlich Biomaterials and Thommen Medical.

REFERENCES

1. Khoshkam V, Suárez-López Del Amo F, Monje A, Lin H, Chan HL, Wang HL. Long-term radiographic and clinical outcomes of regenerative approach for treating peri-implantitis: a systematic review and meta-analysis *Int J Oral Maxillofac*

Implants 2016;31:1303–1310.

2. Tomasi C, Regidor E, Ortiz-Vigón A, Derks J. Efficacy of reconstructive surgical therapy at peri-implantitis-related bone defects. A systematic review and meta-analysis. *J Clin Periodontol* 2019;46 Suppl 21:340-356.
3. Schwarz F, Sahm N, Schwarz K, Becker J. Impact of defect configuration on the clinical outcome following surgical regenerative therapy of peri-implantitis. *J Clin Periodontol* 2010;37:449–455.
4. Aghazadeh A, Persson GR, Renvert S. A single-centre randomized controlled clinical trial on the adjunct treatment of intra-bony defects with autogenous bone or a xenograft: results after 12 months. *J Clin Periodontol* 2012;39:666-73.
5. Rocuzzo M, Bonino F, Bonino L, Dalmaso P. Surgical therapy of peri-implantitis lesions by means of a bovine-derived xenograft: comparative results of a prospective study on two different implant surfaces. *J Clin Periodontol* 2011;38:738–745.
6. Rocuzzo M, Pittoni D, Rocuzzo A, Charrier L, Dalmaso P. Surgical treatment of peri-implantitis intrabony lesions by means of deproteinized bovine bone mineral with 10% collagen: 7-year-results. *Clin Oral Implants Res*; 2017;28:1577–1583.
7. Trombelli L, Severi M, Pramstraller M, Farina R. Sub-periosteal peri-implant augmented layer technique for horizontal bone augmentation at implant placement. *Minerva Stomatol.* 2018;67:217-224.
8. Trombelli L, Severi M, Pramstraller M, Farina R. A simplified soft tissue management for peri-implant bone augmentation. *Int J Oral Maxillofac Implants* 2019;34:197–204.
9. Schwarz F, Herten M, Sager M, Bieling K, Sculean A, Becker J. Comparison of naturally occurring and ligature- induced peri-implantitis bone defects in humans and dogs. *Clin Oral Implants Res.* 2007; 18:161–170.
10. Hurzeler MB, Weng D. A single-incision technique to harvest sub-epithelial connective tissue graft from the palate.. *Int J Periodontics Restorative Dent* 1999;19:279-287.
11. Nobuto T, Suwa F, Kono T, Hatakeyama Y, Honjou N, Shirai T et al.. Microvascular response in the periosteum following mucoperiosteal flap surgery in dogs: 3-dimensional observation of an angiogenic process. *J Periodontol* 2005;76:1339-1345.
12. Roos-Jansaker AM, Renvert H, Lindahl C, Renvert S. Surgical treatment of peri-implantitis using a bone substitute with or without a resorbable membrane: a prospective cohort study. *J Clin Periodontol* 2007;34:625–632.
13. Roos-Jansaker AM, Persson GR, Lindahl C, Renvert S. Surgical treatment of peri-implantitis using a bone substitute with or without a resorbable membrane: a 5-year follow-up. *J Clin Periodontol* 2014; 41: 1108–1114.

This article is protected by copyright. All rights reserved.

14. Rocuzzo M, Gaudio L, Lungo M, Dalmaso P. Surgical therapy of single peri-implantitis intrabony defects, by means of deproteinized bovine bone mineral with 10% collagen. *J Clin Periodontol* 2016;43:311–318.

15. Lee EA. Subperiosteal minimally invasive aesthetic ridge augmentation technique (SMART): a new standard for bone reconstruction of the jaws. *Int J Periodontics Restorative Dent* 2017;37:165-173

16. Chan HL, Lin GH, Suarez F, MacEachern M, Wang HL. Surgical management of peri-implantitis: a systematic review and meta-analysis of treatment outcomes. *J Periodontol* 2014;85:1027-1041.

17. Thoma DS, Naenni N, Figuero E, et al. Effects of soft tissue augmentation procedures on peri-implant health or disease: A systematic review and meta-analysis. *Clin Oral Implants Res* 2018;29(Suppl. 15):32–49.

TABLES

Table 1. Peri-implant pocket depth (PD), bleeding/suppuration upon probing (BoP/SoP) and buccal recession (REC) at each observational interval. MB (mesio-buccal), B (buccal), DB (disto-buccal), MP (mesio-palatal), P (palatal), DP (disto-palatal), ML (mesio-lingual), L (lingual), DL (disto-lingual).

Table 2. Radiographic bone level (RBL) at each observational interval. RBL: Radiographic bone level recorded, in mm, at the mesial (mRBL) and distal (dRBL) implant aspect.

FIGURE LEGEND

Figure 1. Case #1 a-c. Clinical and radiographic view of an implant in position #4 affected by peri-implantitis. **1d.** Mucosal layer is raised by sharp dissection, leaving the periosteum attached to the bone crest. **1e.** Periosteal layer is elevated from the buccal bone plate creating a pouch where a bone substitute can be grafted. **1f.** Peri-implant defect characterized by a mesio-palatal-distal infrabony component associated with a buccal dehiscence (class Ic).

1g. Infrabony component, including the palatal extension of the defect, is completely filled with a bovine derived xenograft **1h.** Periosteal layer is sutured to the oral flap to contain and stabilize the graft in the infrabony component. **1i.** The mucosal layer is coronally advanced and sutured around the abutment to provide condition for wound stability. **1j-l.** Clinical and radiographic view at 6-months examination.

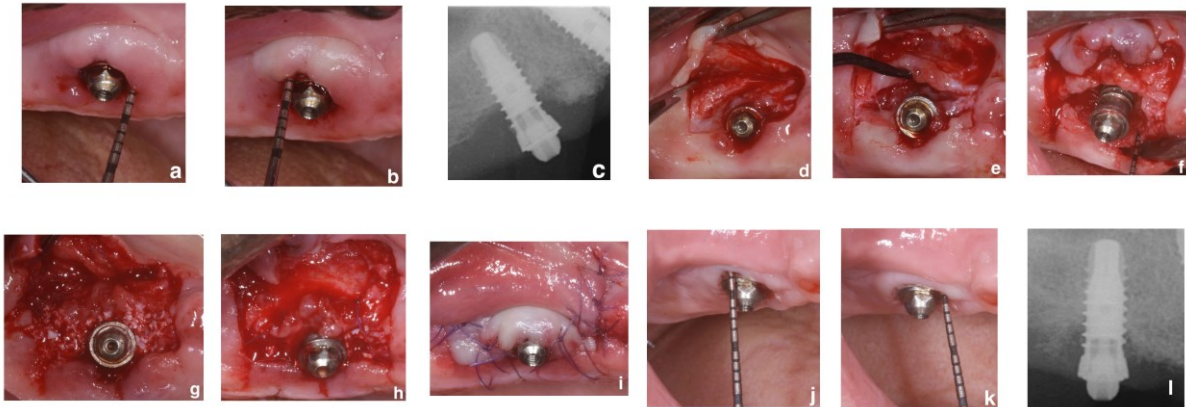


Figure 2. Case #2 a-c. Peri-implant defects associated with bleeding and suppuration upon probing are present on implant in position #29. **2d.** A trapezoidal split-thickness flap is elevated. **2e.** Periosteal layer is elevated from underlying bone and exposed implant surface. A class Ib defect is present, characterized by a mesio-distal infrabony component associated with a buccal dehiscence. **2f.** The periosteal pouch is grafted with xenograft particles to correct the infrabony component of the defect and on the peri-implant bone dehiscence. **2g.** A connective tissue graft (CTG) is sutured over the coronal part of the xenograft and exposed implant surface to enhance wound/graft stability and increase the thickness of the peri-implant mucosa. **2h.** The mucosal layer is coronally advanced to submerge the CTG. **2i-k.** Probing and radiographic assessment at 6-months.

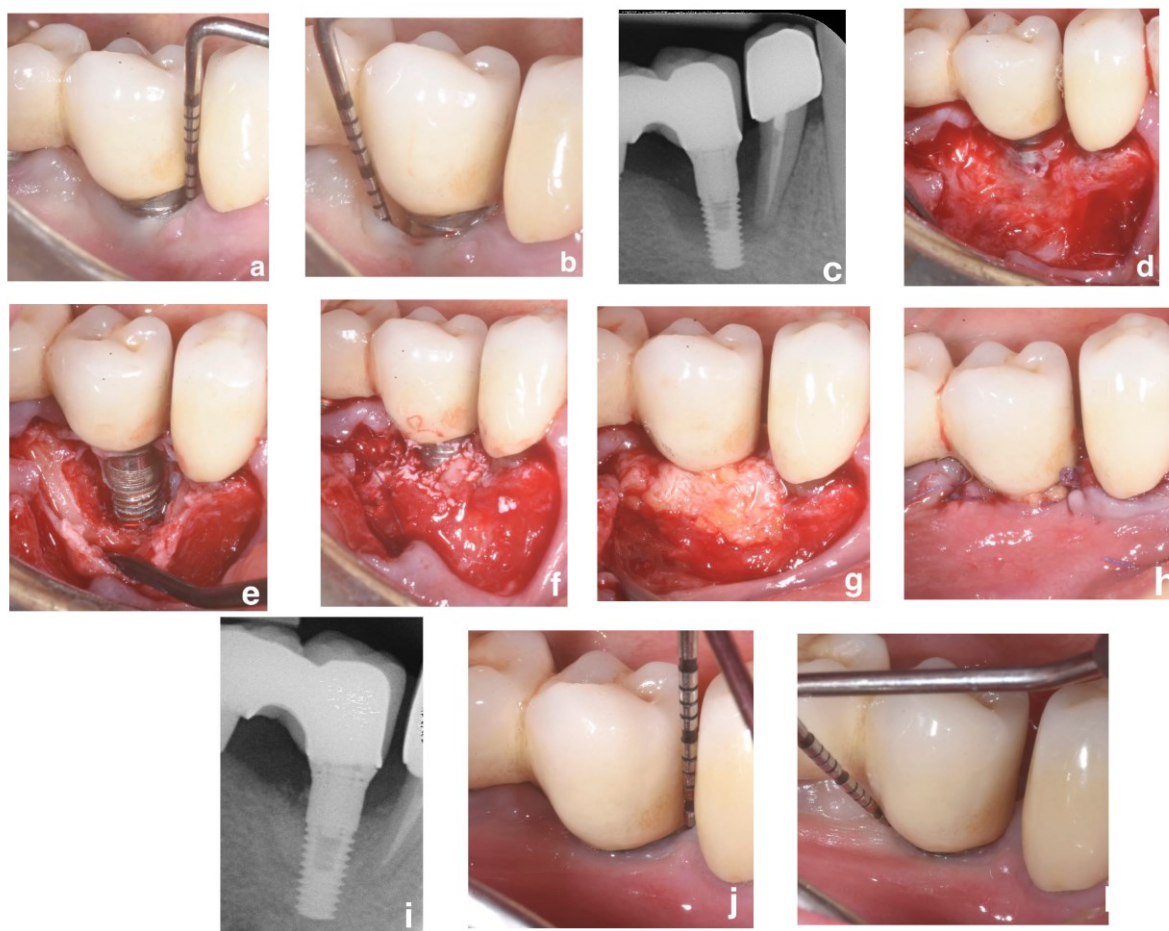
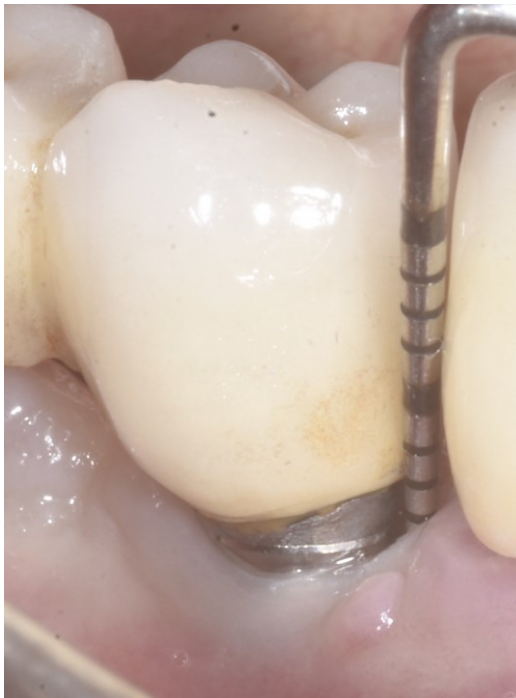

Figure 3. Case #3 a-b. Preoperative examination view of two implants in position #28-#29 affected by peri-implantitis. A non-keratinized, thin peri-implant mucosa associated with implant exposure is present at both implant sites. Peri-implant infrabony defect are visible on the peri-apical radiograph **c**. After reflection of both mucosal and periosteal layers, both implants show class Ib peri-implantitis defects. **3d-e**. Infrabony component of the peri-implantitis defects grafted. Partial exposure of the xenograft coronal to the periosteal pouch is evident. A connective tissue graft (CTG) is sutured over the coronal part of the xenograft and exposed implant surface. **3f**. The mucosal layer is coronally advanced, leaving the CTG partially exposed to create a band of keratinized tissue. **3g-j**. Probing and radiographic assessment at 6-months.

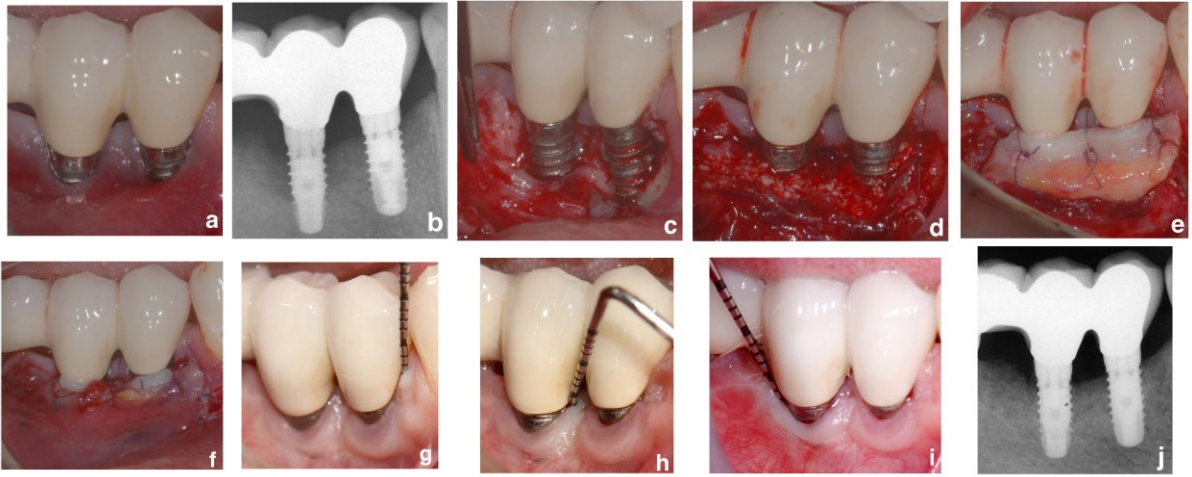

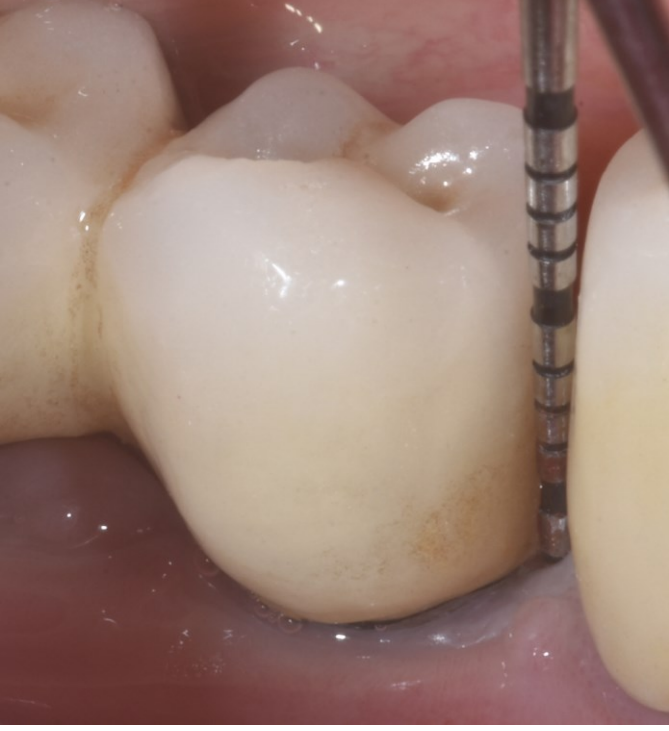


Table 1. Peri-implant pocket depth (PD), bleeding/suppuration upon probing (BoP/SoP) and buccal recession (REC) at each observational interval. MB (mesio-buccal), B (buccal), DB (disto-buccal), MP (mesio-palatal), P (palatal), DP (disto-palatal), ML (mesio-lingual), L (lingual), DL (disto-lingual).

Implant position		PD(mm) and Bop/SoP (+/-)			REC (mm)	
		PreOp	6 months	PreOp	6 months	
#CASE 1	#4	MB	7+	4-	0	0
		B	5+	3-		
		DB	7+	4-		
		MP	7+	4-		
		P	5+	3-		
		DP	7+	4-		
#CASE 2	#29	MB	6+	3+	2	0
		B	3-	2-		
		DB	6+	3-		
		ML	6+	3-		
		L	3-	3-		
		DL	6+	3-		
#CASE 3	#28	MB	4+	2-	4	2
		B	5+	2-		
		DB	5+	2-		
		ML	3-	2-		
		L	3-	2-		
		DL	3-	2-		
	#29	MB	5+	3+	2	1
		B	3-	2-		
		DB	3-	2-		
		ML	3-	3+		
		L	3-	2-		
		DL	3-	2-		

Table 2. Radiographic bone level recorded in mm at mesial and distal implant aspects (mRBL and dRBL, respectively).

	Implant position	mRBL		dRBL	
		pre-op	6 months	pre-op	6 months
#CASE 1	#4	2.7	1.3	3.9	1.1
#CASE 2	#29	5.7	1.3	6.0	1.3
#CASE 3	#28	3.3	0	4.2	1.0
	#29	5.2	1.0	5.6	0