VIDEO NEUROIMAGE OPEN ACCESS

Central Retinal Artery Occlusion

Early Diagnosis With Advanced Ultrasound Transorbital Doppler Imaging

Nicola Merli,[1] Vincenzo Inchingolo,[2] Giovanni Malferrari,[3] Maura Pugliatti,[1] and Maurizio Paciaroni[1]

Neurology® 2026;106:e214725. doi:10.1212/WNL.0000000000214725

Correspondence
Dr. Merli
nicola.merli@unife.it

Figure 1 Left Carotid Ultrasound, Optical Coherence Tomography (OCT), and TDS Comparative Spectral Analysis

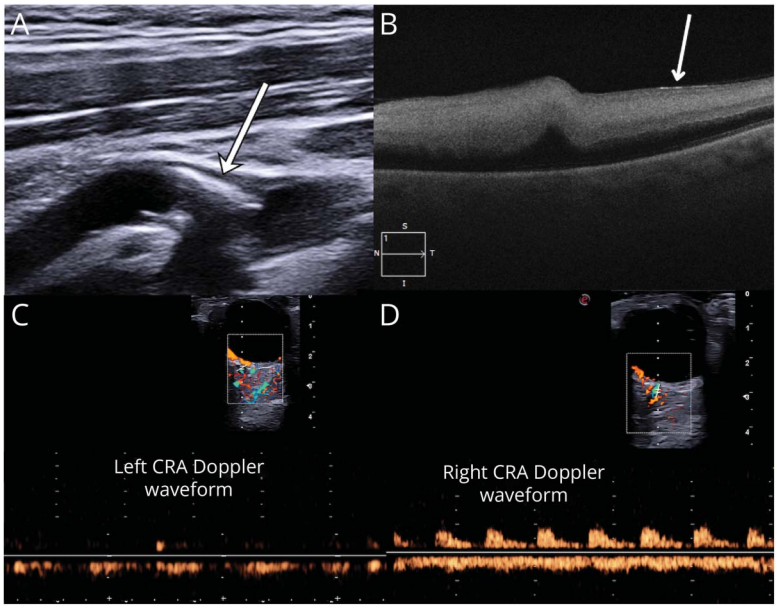

(A) Left carotid ultrasound calcific plaque (arrow), matching the retinal embolization side and echotexture. (B) Left-eye OCT showing hyperreflectivity (arrow), thickening/edema, and loss of individual inner retinal layer stratification. (C) Left-CRA TDS waveform demonstrating absence of arterial signal; only retrograde venous flow is recognizable. (D) Normal venous and arterial pattern in right-TDS waveform. TDS = transorbital Doppler sonography.

A 62-year-old man presented with sudden, painless, complete vision loss in left eye upon nocturnal awakening. Ophthalmoscopy revealed pale retina and cherry-red spot, suggestive of central retinal artery occlusion (CRA-O). Brain CT-angiography was normal, and left internal carotid artery ultrasound examination showed <50% calcific stenosis (Figure 1A). Macular optic coherence tomography was consistent with suspicion (Figure 1B). Transorbital Doppler sonography (TDS) performed at presentation revealed a hyperechoic spot sign posterior to the optic nerve head, representing a CRA distal fibrocalcific thrombus (Figure 2, Video 1).[1] No Power-Doppler spectral signal from CRA was detectable (Figures 1, C–D and 2B–D; Video 1).

Fluorescein-angiography at day 8 was consistent with CRA-O (eFigure 1).

MORE ONLINE

Video Supplementary Material

[1]Department of Neuroscience and Rehabilitation, University of Ferrara, Italy; [2]Neurology Unit, Fondazione IRCCS Casa Sollievo della Sofferenza, San Giovanni Rotondo, Italy; and [3]Neurology and Stroke Unit, IRCCS Istituto delle Scienze Neurologiche di Bologna, Italy.

The Article Processing Charge was funded by Funded by European Union - Next GenerationEU, Italian Ministry of University and Research (Programmi di Rilevante Interesse Nazionale, PRIN) (Prot. N. 2022XT88XL; P.I. M. Pugliatti), University of Ferrara, Italy.

This is an open access article distributed under the terms of the Creative Commons Attribution-Non Commercial-No Derivatives License 4.0 (CCBY-NC-ND), where it is permissible to download and share the work provided it is properly cited. The work cannot be changed in any way or used commercially without permission from the journal.

Copyright © 2026 The Author(s). Published by Wolters Kluwer Health, Inc. on behalf of the American Academy of Neurology.

Figure 2 Transorbital Sonography and Power-Doppler Findings in CRA-O Eye and Contralateral Eye

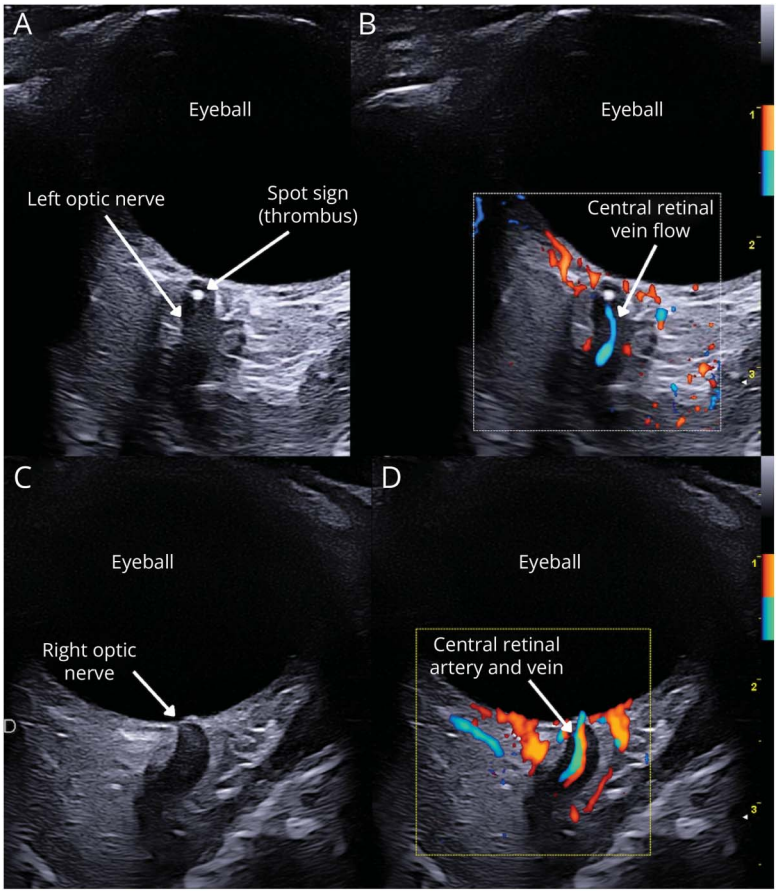

(A) Left-eye TDS, transverse scan. Circular-shaped hyperechoic spot sign (CRA fibrocalcific thrombus) is distinctly visible posterior to the optic nerve head. (B) Absence of left CRA Power-Doppler antegrade flow with preserved venous signal (arrow). (C and D) Contralateral normal optic nerve sonography; absence of spot signs, with regular arterial and venous retinal blood-flow signals. TDS = transorbital Doppler sonography.

By month 12, no visual improvement was recorded and the CRA clot could still be detected with TDS (eFigure 2).

TDS can enable fast, efficient, bedside, high-resolution assessment of retrobulbar circulation, featuring higher sensibility to detect embolic/athero-thrombi in sudden monocular visual loss compared with CT-angiography.

Author Contributions

N. Merli: drafting/revision of the manuscript for content, including medical writing for content; major role in the acquisition of data; study concept or design; analysis or interpretation of data. V. Inchingolo: study concept or design; analysis or interpretation of data. G. Malferrari: study concept or design; analysis or interpretation of data. M. Pugliatti: drafting/revision of the manuscript for content, including medical writing for content; study concept or design; analysis or interpretation of data. M. Paciaroni: drafting/revision of the manuscript for content, including medical writing for content; study concept or design; analysis or interpretation of data.

Study Funding

Funded by European Union - Next GenerationEU, Italian Ministry of University and Research (Programmi di Rilevante Interesse Nazionale, PRIN) (Prot. N. 2022XT88XL; P.I. M. Pugliatti), University of Ferrara, Italy.

Disclosure

The authors report no relevant disclosures. Go to Neurology.org/N for full disclosures.

Publication History

Received by *Neurology*® November 13, 2025. Accepted in final form December 23, 2025. Submitted and externally peer reviewed. The handling editor was Editor-in-Chief José Merino, MD, MPhil, FAAN.

Reference

1. Nedelmann M, Tanislav C, Kaps M. A traveling "spot sign" in recurrent amaurosis fugax and central retinal artery occlusion. *J Stroke Cerebrovasc Dis.* 2014;23(9):e421–e422. doi:10.1016/j.jstrokecerebrovasdis.2014.05.001