




# Lingual Lichenoid Lesion Due to Dental Amalgam Fillings: Case Report and Clinical Considerations

Massimo Petruzzi <sup>1,2,\*</sup> , Fedora della Vella <sup>1</sup> , Guglielmo Campus <sup>2</sup> , Dario Di Stasio <sup>3</sup>  and Dorina Lauritano <sup>4</sup> 

<sup>1</sup> Interdisciplinary Department of Medicine, University of Bari "Aldo Moro", 70124 Bari, Italy

<sup>2</sup> Department of Restorative, Preventive and Pediatric Dentistry, University of Bern, 3012 Bern, Switzerland

<sup>3</sup> Multidisciplinary Department of Medical, Surgical and Dental Specialties, University of Campania "Luigi Vanvitelli"; 80138 Naples, Italy

<sup>4</sup> Department of Translational Medicine, University of Ferrara, 44121 Ferrara, Italy

\* Correspondence: massimo.petruzzi@uniba.it

**Abstract:** Oral white lesions are quite common clinical conditions in clinical dental practice. They can be an expression of different diseases, so it is crucial to achieve a correct diagnosis to start an adequate treatment. However, differential diagnosis is not always easy because the clinical appearance of oral white lesions is often similar and non-pathognomonic. We report on a 42-year-old Caucasian woman who complained of a chronic white patch on the left border of her tongue. A provisional diagnosis of oral hairy leukoplakia was made, but the patient was HIV-negative and not immunocompromised. A patch test was performed to exclude an allergic reaction, which resulted negative. Two large amalgam fillings were removed, and the lesion regressed after two weeks, suggesting a diagnosis of oral lichenoid lesions. Amalgam-associated oral lichenoid lesions could be mistaken for hairy leukoplakia when located on the lateral border of the tongue. Patch tests for dental metal series are only sometimes helpful for a diagnosis of oral lichenoid lesions. Patients should follow a careful follow-up to monitor any neoplastic derailment of the lichenoid lesions.

**Keywords:** oral lichenoid lesion; oral hairy leukoplakia; amalgam



**Citation:** Petruzzi, M.; della Vella, F.; Campus, G.; Di Stasio, D.; Lauritano, D. Lingual Lichenoid Lesion Due to Dental Amalgam Fillings: Case Report and Clinical Considerations. *Appl. Sci.* **2022**, *12*, 12895. <https://doi.org/10.3390/app122412895>

Academic Editors: Tommaso Lombardi and Andrea Scribante

Received: 14 November 2022

Accepted: 12 December 2022

Published: 15 December 2022

**Publisher's Note:** MDPI stays neutral with regard to jurisdictional claims in published maps and institutional affiliations.



**Copyright:** © 2022 by the authors. Licensee MDPI, Basel, Switzerland. This article is an open access article distributed under the terms and conditions of the Creative Commons Attribution (CC BY) license (<https://creativecommons.org/licenses/by/4.0/>).

## 1. Introduction

Dental amalgam was introduced to dentistry more than 100 years ago and has been the most commonly used material for restoring decayed teeth. Amalgam is an alloy of liquid mercury and pulverised particles of silver, tin, copper, zinc, and other metals.

The term oral lichenoid lesions (OLLs) is used to describe a spectrum of lichen planus-like ("lichenoid") lesions affecting the oral mucosa, aetiologically identifiable but clinically and histologically indistinguishable from oral lichen planus [1]. Van der Wall classified four types of OLLs: amalgam-restoration-related lesions (topographically associated lesions), drug-related lichenoid lesions, lichenoid lesions in chronic graft-versus-host disease, and lesions looking like lichen planus but lacking one or more distinct clinical aspects [2]. Oral lichenoid contact lesions were classified as a sub-category at the 2006 World Workshop of Oral Medicine IV [3]. The elimination of precipitating or provoking factors is fundamental for mucosal healing. Amalgam-associated OLLs present a broad spectrum of histopathologic patterns, and mercury accumulations may play a role in maintaining the chronicity of such lesions [4]. According to a consensus report from an international seminar on nomenclature and classification from the WHO Collaborating Centre for Oral Cancer, OLLs are classified as oral potentially malignant disorders, with a rate of malignant transformation of 3.8% (rate per year of 0.57%) [5].

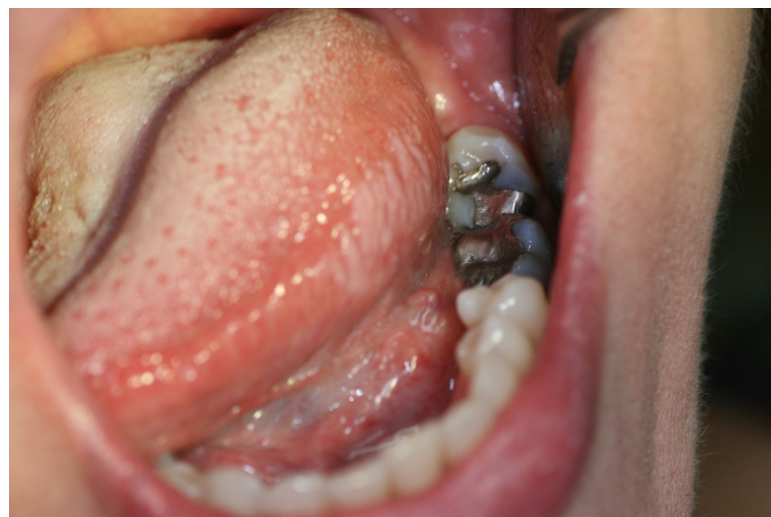Oral hairy leukoplakia (OHL) was first described in 1984 by Greenspan et al. in a cohort of American homosexual HIV patients [6]. Since its initial description, OHL has been reported in other severely immunocompromised groups, including transplant recipients and patients with leukaemia or other malignancies. OHL is an oral mucosal disease

associated with Epstein–Barr virus infection and almost exclusively occurs in people with immunosuppression (50% of patients with untreated HIV, particularly those whose CD4 count is less than  $0.3 \times 10^9/L$ ) [7]. Lesions appear as unilateral or bilateral white, non-removable, hyperkeratotic plaques or *striae* on the lateral side of the tongue with thickened white projections (similar to hair) [8]. OHL can also affect other oral mucosal sites, such as the dorsal or ventral tongue, the palatal mucosa, the oropharynx, the floor of the mouth, or the buccal mucosa [9].

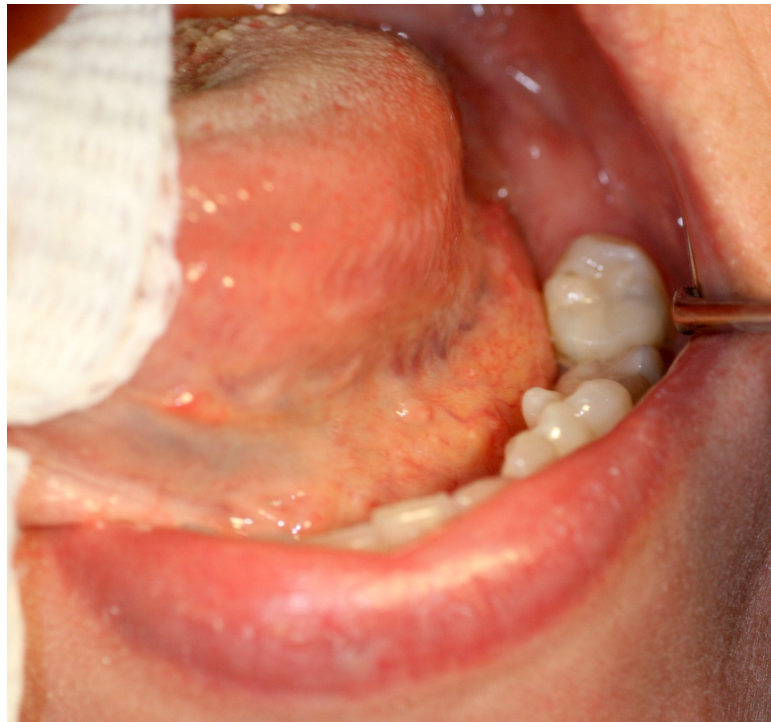We report a case of a patient with a white patch arising on the left lateral border of her tongue that was observed in the Oral Pathology and Medicine Unit of the University of Bari in Italy.

## 2. Case Report

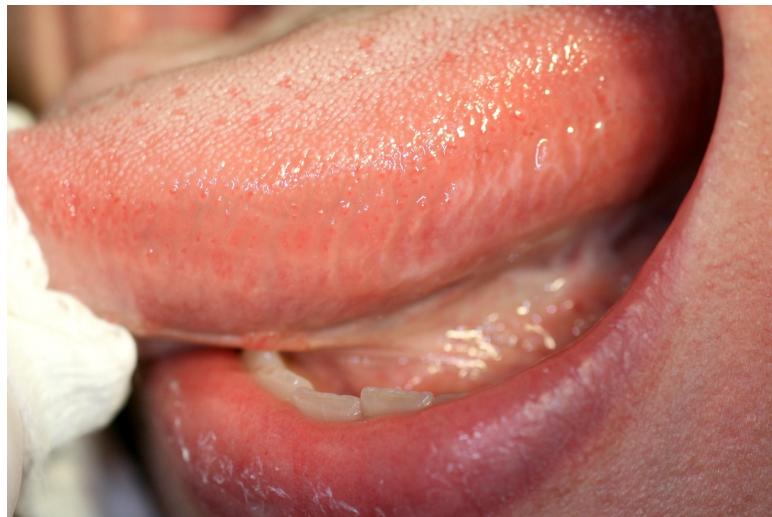A 42-year-old female complained of an “undiagnosed stomatitis”. The patient did not remember the onset of the referred to lesion that was occasionally noted during her regular oral hygiene procedures. She reported having an itchy, burning, and stuck mouth. The patient’s past medical history was not significant and she did not take any medication. Initially, her symptoms began on her tongue and spread progressively to the entire lingual mucosa. This discomfort continued for 4 months despite using chlorhexidine mouthwash and proper oral hygiene. At the clinical examination, a white, adherent, irregular patch along the left lateral border of the tongue that measured approximately  $20 \times 15$  mm was noted (Figure 1). In the first instance, any traumatic cause was excluded. Two large amalgam restorations were present on her left inferior molars, close to the observed lesion (Figure 1). The patient insisted on performing a prompt biopsy because of her considerable cancerphobia. Based on the lesion’s contiguity with the two amalgam restorations, a principal provisional diagnosis of an OLL due to the amalgam was made, but given the clinical appearance a hypothetical diagnosis of OHL was also made. An HIV test and a complete blood count were immediately performed. The HIV test was negative, and the complete blood analysis showed no significant alterations. Patch testing with the European baseline, dental, and metal series (Finn Chambers®; Chemotechnique Diagnostics, Vellinge, Sweden) yielded no positive results. Despite these results, the amalgam fillings were removed and replaced with a composite resin restoration (Figure 2). After two weeks, the lesion markedly improved, and there was no recurrence of signs and symptoms at the subsequent follow-up (Figure 3). After six years, no further complication or malignant derailment has been recorded.



**Figure 1.** White corrugated lesion measuring  $20 \times 15$  mm on the left dorsal border of the tongue. Presence of two amalgam fillings on 3.6 and 3.7 teeth.



**Figure 2.** Composite resin restorations on 3.6 and 3.7 teeth after the removal of the amalgams.



**Figure 3.** Left border of the tongue two weeks after the amalgam removal. Mucosal signs were strongly improved. The patient reported no symptoms.

### 3. Discussion

The presence of white lesions of the oral mucosa is a relatively frequent occurrence in clinical practice; in fact, many oral diseases appear in the oral cavity as “white patches”. This is a diagnostic and therapeutic challenge for clinicians because the same clinical appearance can be shared among different lesions with different aetiopathogenetic and prognostic significance. Oral lichen planus, OLLs, proliferative verrucous leukoplakia, homogeneous leukoplakia, frictional keratosis, benign alveolar ridge keratosis, white sponge naevus, candidiasis, and leukoedema may be clinically confounded with each other, and only an accurate and careful examination allows for the correct diagnosis [10].

This case report highlights how completely different nosological entities affecting the margins of the tongue, such as OLLs, OHL or frictional keratosis, can appear the same to clinicians. Clinical investigation, even before histopathological sampling, could lead to a

diagnosis and resolution of the lesions with a less invasive and uncomfortable approach for patients.

OLLs, described for the first time 40 years ago by Finne et al., have a low prevalence and have been diagnosed in about 0.15% of patients with at least an amalgam filling [11,12].

OLLs induced by amalgam restorations can appear as white patches, atrophic erosive areas, or with mixed aspects. Different localisations of OLLs were described by Dunsche et al. [13], who reported on 467 patients with amalgam-triggered OLLs. Three different types of oral lesions were described: (a) oral lesions topographically in contact with the amalgam; (b) oral lesions extending beyond the contact zone between the oral mucosa and the amalgam; and (c) oral lesions without any contact with the amalgam filling. The different clinical responses of the oral mucosa can be explained by the different pathogenetic mechanisms through which amalgam fillings cause damage.

The mechanisms by which amalgam fillings can determine the onset of OLLs remain debated, and several hypotheses have been postulated. The first hypothesis considers OLLs as a delayed type IV, cell-mediated immune response to mercury, copper, tin, zinc, or one of the other constituents of a dental amalgam [14]. Skin patch testing is a valuable tool to confirm clinically suspected oral lichenoid reactions, although other authors do not consider patch tests reliable in diagnosing OLLs [15,16]. A second pathogenetic hypothesis concerns the presence of non-specific toxic reactions to amalgam components (especially those with a high zinc content) developed over the years. These reactions could also explain why OLLs are very often seen in correspondence with old fillings [17]. A third hypothesis concerns the presence of electrogalvanic phenomena that could arise between the metal components present in a filling and salivary ions, with saliva as the conducting medium [18]. In the present case, the presence of an OLL mimicking OHL led us to suppose that the patient was immunosuppressed. OHL is an oral mucosal disease associated with Epstein–Barr virus infection, which predominantly occurs in immunocompromised patients (e.g., from untreated HIV, haematological malignancy, and organ and bone marrow transplantation) [19,20]. However, OHL lesions have also been sporadically described in healthy subjects [21] and are quite common, unlike OHL.

Frictional keratosis must also be considered as it can affect the margins of the tongue. The careful evaluation of sharp dental margins or cuspid fractures and incongruous fillings can cause hyperkeratotic traumatic reactions at the site where they persist [22].

Only one report described an association between OHL and oral lichen planus; however, it is probable that the local corticosteroid therapy used to treat OLP has favoured the action of EBV in the determinism of OHL. OHL diagnosis can be clinically made and does not require a confirmatory biopsy if retrieved from the putative causes [23].

On the other hand, the clinical manifestations of a contact allergy to dental materials are not uniform: lichenoid reactions, cheilitis, and oral aphthous stomatitis are the most reported, but, to the best of our knowledge, this is the first report describing an OLL due to amalgam fillings mimicking OHL [24]. Although this is only a single report, the rapid and complete healing observed and the lack of recurrence during follow-up suggests that amalgam restorations, especially those which are outdated, may cause mucosal lesions to be diagnosable as OHL. The diagnosis of OHL induced by an amalgam is performed “a posteriori” since only the removal of the filling and the disappearance of the lichenoid signs can confirm the initial diagnostic hypothesis. The main guidelines suggest that a biopsy should be performed if lesions persist 14 days after removing potential causes and/or treatment [25]. Removal of amalgam fillings must be followed by a close 2-week follow-up, after which OLLs must be surgically removed (with a histopathological evaluation) if they do not heal or improve significantly. However, histopathological examination does not allow for distinguishing between oral lichen planus and OLLs as the two entities share the same pathological aspects [26].

The patch test for the dental metal series is not always of diagnostic support. Topographical congruence between lesions and fillings should guide clinicians in placing the diagnostic suspicion on OLLs [16]. Debate exists about the malignant transforma-



tion of OLLs, but more data are needed about the malignant transformation of OLLs explicitly caused by amalgam fillings [27]. To date, only five cases of malignant transformation of OLLs related to amalgams are reported. The first four cases were described by Larsson et al. [28], who histopathologically documented the neoplastic changes that occurred in a mean time of 8.5 years. All the reported cases arose on the tongue margins.

More recently, Gabusi et al. reported a case of OLLs due to an amalgam, which transformed into oral squamous cell carcinoma 10 years after the initial diagnosis and the amalgam substitution [29]. OLLs and OHL may share clinical aspects but are two different nosological entities. During the diagnostic process, before histopathological sampling, any systemic and local irritative causes must be excluded. Patients should follow up in the following 12 months to evaluate the complete remission of the lesions and monitor any eventual neoplastic derailment.

**Author Contributions:** Conceptualization, M.P.; methodology, F.d.V.; data curation, D.D.S. and D.L.; writing—original draft preparation, M.P.; writing—review and editing, G.C. and D.L.; supervision, M.P. and G.C. All authors have read and agreed to the published version of the manuscript.

**Funding:** This research received no external funding.

**Institutional Review Board Statement:** The study was conducted in accordance with the Declaration of Helsinki, and the local independent ethical committee of "Azienda Ospedaliero-Universitaria Policlinico Consorziiale" of Bari approved our studies on oral mucosal diseases (protocol number is 46815/C.E.).

**Informed Consent Statement:** Informed consent was obtained from all subjects involved in the study.

**Conflicts of Interest:** The authors declare no conflict of interest.

## References

1. Kamath, V.V.; Setlur, K.; Yerlagudda, K. Oral lichenoid lesions—A review and update. *Indian. J. Dermatol.* **2015**, *60*, 102. [[CrossRef](#)] [[PubMed](#)]
2. Al-Hashimi, I.; Schifter, M.; Lockhart, P.B.; Wray, D.; Brennan, M.; Migliorati, C.A.; Axéll, T.; Bruce, A.J.; Carpenter, W.; Eisenberg, E.; et al. Oral lichen planus and oral lichenoid lesions: Diagnostic and therapeutic considerations. *Oral. Surg. Oral. Med. Oral. Pathol. Oral. Radiol. Endod.* **2007**, *103*, S25.e1–S25.e12. [[CrossRef](#)] [[PubMed](#)]
3. Baccaglini, L.; Brennan, M.T.; Lockhart, P.B.; Patton, L.L. World Workshop on Oral Medicine IV: Process and methodology for systematic review and developing management recommendations. Reference manual for management recommendations writing committees. *Oral. Surg. Oral. Med. Oral. Pathol. Oral. Radiol. Endod.* **2007**, *103*, S3.e1–S3.e19. [[CrossRef](#)] [[PubMed](#)]
4. Larsson, A.; Warfvinge, G. The histopathology of oral mucosal lesions associated with amalgam or porcelain-fused-to-metal restorations. *Oral. Dis.* **1995**, *1*, 152–158. [[CrossRef](#)]
5. Warnakulasuriya, S.; Kujan, O.; Aguirre-Urizar, J.M.; Bagan, J.V.; González-Moles, M.Á.; Kerr, A.R.; Lodi, G.; Mello, F.W.; Monteiro, L.; Ogden, G.R.; et al. Oral potentially malignant disorders: A consensus report from an international seminar on nomenclature and classification, convened by the WHO Collaborating Centre for Oral Cancer. *Oral. Dis.* **2021**, *27*, 1862–1880. [[CrossRef](#)]
6. Greenspan, D.; Greenspan, J.S.; Conant, M.; Petersen, V.; Silverman, S.; de Souza, Y. Oral "hairy" leucoplakia in male homosexuals: Evidence of association with both papillomavirus and a herpes-group virus. *Lancet* **1984**, *2*, 831–834. [[CrossRef](#)]
7. Bravo, I.M.; Correnti, M.; Escalona, L.; Perrone, M.; Brito, A.; Tovar, V.; Rivera, H. Prevalence of oral lesions in HIV patients related to CD4 cell count and viral load in a Venezuelan population. *Med. Oral. Patol. Oral. Cir. Bucal.* **2006**, *11*, E33–9.
8. Pastore, L.; De Benedittis, M.; Petrucci, M.; Fiore, J.R.; Serpico, R. Efficacy of famciclovir in the treatment of oral hairy leukoplakia. *Br. J. Dermatol.* **2006**, *154*, 378–379. [[CrossRef](#)]
9. Greenspan, J.S.; Greenspan, D.; Webster-Cyriaque, J. Hairy leukoplakia; lessons learned: 30-plus years. *Oral. Dis.* **2016**, *22* (Suppl. 1), 120–127. [[CrossRef](#)]
10. Warnakulasuriya, S. White, red, and mixed lesions of oral mucosa: A clinicopathologic approach to diagnosis. *Periodontol.* **2000**, *2019*, *80*, 89–104. [[CrossRef](#)]
11. Finne, K.; Göransson, K.; Winckler, L. Oral lichen planus and contact allergy to mercury. *Int. J. Oral. Surg.* **1982**, *11*, 236–239. [[CrossRef](#)] [[PubMed](#)]
12. Gupta, P.; Mallishery, S.; Bajaj, N.; Banga, K.; Mehra, A.; Desai, R. Low Prevalence of Amalgam-Associated Lichenoid Lesions in the Oral Cavity: A Prospective Study. *Cureus.* **2022**, *14*, e22696. [[CrossRef](#)] [[PubMed](#)]
13. Dunsche, A.; Kästel, I.; Terheyden, H.; Springer, I.N.; Christophers, E.; Brasch, J. Oral lichenoid reactions associated with amalgam: Improvement after amalgam removal. *Br J Dermatol.* **2003**, *148*, 70–76. [[CrossRef](#)] [[PubMed](#)]

14. Segura-Egea, J.J.; Bullón-Fernández, P. Lichenoid reaction associated to amalgam restoration. *Med. Oral. Patol. Oral. Cir. Bucal.* **2004**, *9*, 421–424.
15. Suter, V.G.; Warnakulasuriya, S. The role of patch testing in the management of oral lichenoid reactions. *J. Oral. Pathol. Med.* **2016**, *45*, 48–57. [[CrossRef](#)]
16. Rahat, S.; Kashetsky, N.; Bagit, A.; Sachdeva, M.; Lytvyn, Y.; Mufti, A.; Maibach, H.I.; Yeung, J. Can We Separate Oral Lichen Planus from Allergic Contact Dermatitis and Should We Patch Test? A Systematic Review of Chronic Oral Lichenoid Lesions. *Dermatitis.* **2021**, *32*, 144–150. [[CrossRef](#)]
17. McParland, H.; Warnakulasuriya, S. Oral lichenoid contact lesions to mercury and dental amalgam—A review. *J. Biomed. Biotechnol.* **2012**, *2012*, 589569. [[CrossRef](#)]
18. Lind, P.O.; Hurlen, B.; Strømme Koppang, H. Electrogalvanically-induced contact allergy of the oral mucosa. Report of a case. *Int. J. Oral. Surg.* **1984**, *13*, 339–345. [[CrossRef](#)]
19. Vale, D.A.; Martins, F.M.; Silva, P.H.; Ortega, K.L. Retrospective analysis of the clinical behavior of oral hairy leukoplakia in 215 HIV-seropositive patients. *Braz. Oral. Res.* **2016**, *30*, e118. [[CrossRef](#)]
20. Kanduc, D.; Serpico, R.; Lucchese, A.; Shoenfeld, Y. Correlating low-similarity peptide sequences and HIV B-cell epitopes. *Autoimmun. Rev.* **2008**, *7*, 291–296. [[CrossRef](#)]
21. Alramadhan, S.A.; Bhattacharyya, I.; Cohen, D.M.; Islam, M.N. Oral Hairy Leukoplakia in Immunocompetent Patients Revisited with Literature Review. *Head. Neck. Pathol.* **2021**, *15*, 989–993. [[CrossRef](#)] [[PubMed](#)]
22. Woo, S.B.; Lin, D. Morsicatio mucosae oris—A chronic oral frictional keratosis, not a leukoplakia. *J Oral Maxillofac Surg.* **2009**, *67*, 140–146. [[CrossRef](#)]
23. Flores-Hidalgo, A.; Lim, S.O.; Curran, A.E.; Padilla, R.J.; Murrach, V. Considerations in the diagnosis of oral hairy leukoplakia-an institutional experience. *Oral. Surg. Oral. Med. Oral. Pathol. Oral. Radiol.* **2018**, *125*, 232–235. [[CrossRef](#)] [[PubMed](#)]
24. Cifuentes, M.; Davari, P.; Rogers, R.S., 3rd. Contact stomatitis. *Clin. Dermatol.* **2017**, *35*, 435–440. [[CrossRef](#)] [[PubMed](#)]
25. Available online: <https://oralcancerfoundation.org/cdc/early-detection-diagnosis-staging/> (accessed on 4 April 2022).
26. Netto, J.N.S.; Pires, F.R.; Costa, K.H.A.; Fischer, R.G. Clinical features of oral lichen planus and oral lichenoid lesions: An oral pathologist's perspective. *Braz. Dent. J.* **2022**, *33*, 67–73. [[CrossRef](#)] [[PubMed](#)]
27. Gilligan, G.; Garola, F.; Piemonte, E.; Leonardi, N.; Panico, R.; Warnakulasuriya, S. Lichenoid proliferative leukoplakia, lichenoid lesions with evolution to proliferative leukoplakia or a continuum of the same precancerous condition? A revised hypothesis. *J. Oral. Pathol. Med.* **2021**, *50*, 129–135. [[CrossRef](#)]
28. Larsson, A.; Warfvinge, G. Oral lichenoid contact reactions may occasionally transform into malignancy. *Eur. J. Cancer. Prev.* **2005**, *14*, 525–529. [[CrossRef](#)]
29. Gabusi, A.; Rossi, R.; Gissi, D.B. Malignant transformation of a clinically and histologically healed lichenoid lesion after amalgam removal: A case report and literature review. *J. Stomatol. Oral. Maxillofac. Surg.* **2021**, *122*, 208–211. [[CrossRef](#)]