



- best practice. *Contact Dermatitis*. 2015;73(4):195-221. doi:10.1111/cod.12432 PMID: 26179009.
12. Mowitz M, Zimerson E, Svedman C, Bruze M. Stability of fragrance patch test preparations applied in test chambers. *Br J Dermatol*. 2012; 167:822-827.
  13. Fregert S. *Manual of Contact Dermatitis*. 2nd ed. Munksgaard Copenhagen; 1981.

**How to cite this article:** Bruze M, Antelmi A, Dahlin J, et al. Should acetophenone azine be inserted in a baseline patch test series? *Contact Dermatitis*. 2023;89(4):295-297. doi:10.1111/cod.14378

# Allergic contact dermatitis due to $\alpha$ -lipoic acid in a topical over-the-counter product: A case report

Monica Corazza<sup>1</sup> | Edoardo Arlotti<sup>1</sup>  | Natale Schettini<sup>1</sup>  | Lucrezia Pacetti<sup>1</sup> | Anna Bianchi<sup>2</sup> | Alessandro Borghi<sup>1</sup>

<sup>1</sup>Department of Medical Sciences, Section of Dermatology, Section of Dermatology and Infectious Diseases, University of Ferrara, Ferrara, Italy

<sup>2</sup>Department of Chemical, Pharmaceutical and Agricultural Sciences, University of Ferrara, Ferrara, Italy

## Correspondence

Edoardo Arlotti, Department of Medical Sciences, Section of Dermatology and Infectious Diseases, University of Ferrara, Via L. Ariosto 35, 44121 Ferrara, Italy.  
Email: edoardo96.arlotti@gmail.com

**KEYWORDS:** 1,2-dithiolane-3-pentanoic acid, 6,8-thiotic acid, allergic contact dermatitis, case report,  $\alpha$ -lipoic acid

Alfa-lipoic acid ( $\alpha$ -LA), also known as 1,2-dithiolane-3-pentanoic acid or 6,8-thiotic acid (CAS number 1077-28-7), is a pale-yellow crystalline powder with antioxidant properties. Despite its large use in cosmetics and topical products, few reports are found in the literature concerning its sensitizing potential.<sup>1-3</sup>

## CASE REPORT

A 86-year-old woman presented with an acute dermatitis of her lower limbs.

Prior to this, the patient suffered from chronic leg venous insufficiency for which she was advised to use Tiobec<sup>®</sup> cream (produced by Laborest, Milan, Italy), containing  $\alpha$ -LA at 5% concentration, by the Pharmacist. The dermatitis developed after she began the topical use of the product.

Tiobec<sup>®</sup> cream is an over-the-counter topical product typically used for cutaneous inflammation, dermatitis and for post-surgical scar care due to its antioxidant, anti-inflammatory and emollient properties.

The patient showed a severe itching erythematous, oozing dermatitis of her lower legs and thighs (Figure 1).

The patient was advised to stop the use of the Tiobec<sup>®</sup> cream and topical and systemic corticosteroids were prescribed.

Six months later, the patient was patched-tested with the Società Italiana Dermatologia Allergologica Professionale Ambientale baseline series (SmartPractice, Rome, Italy) and the topical product Tiobec<sup>®</sup> cream, tested 'as is'.<sup>4</sup> Patch tests were applied on her back and left in

occlusion for 2 days, using the AllergEAZE<sup>®</sup> skin patch test chambers (Smart Practice) on Soffix tape (Artsana, Grandate, Italy). Readings were performed on day (D) 2 and D3, and a positive reaction (++++) at D2 and D3 was observed only to Tiobec<sup>®</sup> cream.

Additional patch tests were performed with its main component,  $\alpha$ -LA (ALA 22121 supplied by ACEF SpA, Fiorenzuola d'Arda [PC], Italy). The component  $\alpha$ -LA was tested at the 0.5%, 1% and 5% concentrations in petrolatum. All the three concentrations gave a strong positive reaction (++++) at D2 and D3 (Figure 2).

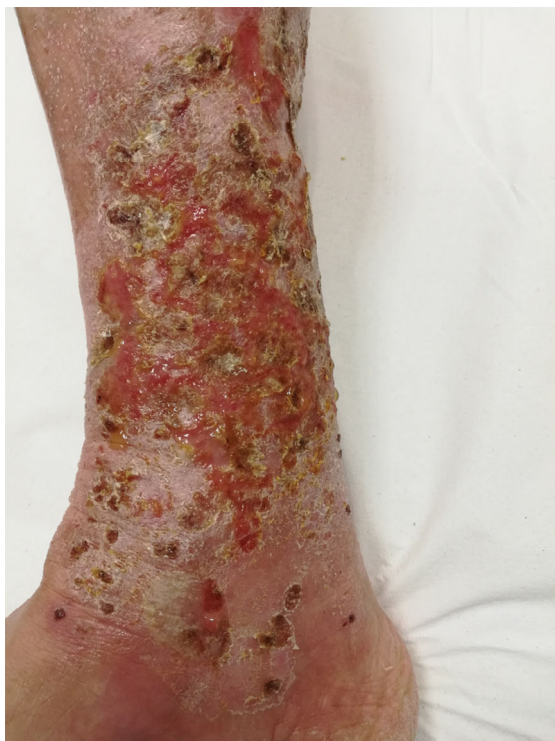The patient declined further patch tests with lower concentrations.

Patch tests with  $\alpha$ -LA 0.5%, 1% and 5% in petrolatum were successively performed in seven healthy controls, with negative results.

## DISCUSSION

$\alpha$ -LA was first isolated in 1951 as part of the enzymatic complex involved in oxidative metabolism. It has antioxidant properties due to its role as inhibitor of the activation of transcription factor nuclear factor kappa-light-chain-enhancer of activated B cells.<sup>5</sup> It is also a powerful anti-inflammatory agent, acting as both a free radical scavenger and a modulator of the inflammatory response. This makes it a logical choice for cosmetic and medical industries, mainly in 'anti-age' products and for treating various inflammatory dermatitis.

Three patients with severe facial dermatitis caused by an 'anti-age' cream newly launched in Sweden were reported in 2006. Further testing with all ingredients of the cream demonstrated a clear



**FIGURE 1** Blistering and erythematous-exudative dermatitis of the legs where the patient had repeatedly applied Tiobec<sup>®</sup> cream.

positivity to  $\alpha$ -LA 5% petrolatum in all three patients; serial dilution of the substance gave a positive reaction down to a concentration of 0.025% in two out of three patients.<sup>1</sup> A further case of severe facial dermatitis caused an anti-ageing cream containing  $\alpha$ -LA and vitamin C was described in Belgium in 2016. Initially, patch tests were performed with the Belgian baseline series and the patient's cosmetic products 'as is', including the anti-wrinkle cream, which gave a clear positive reaction; upon further testing with all ingredients of the cream, a strong positivity to  $\alpha$ -LA 5% petrolatum was demonstrated.<sup>2</sup>

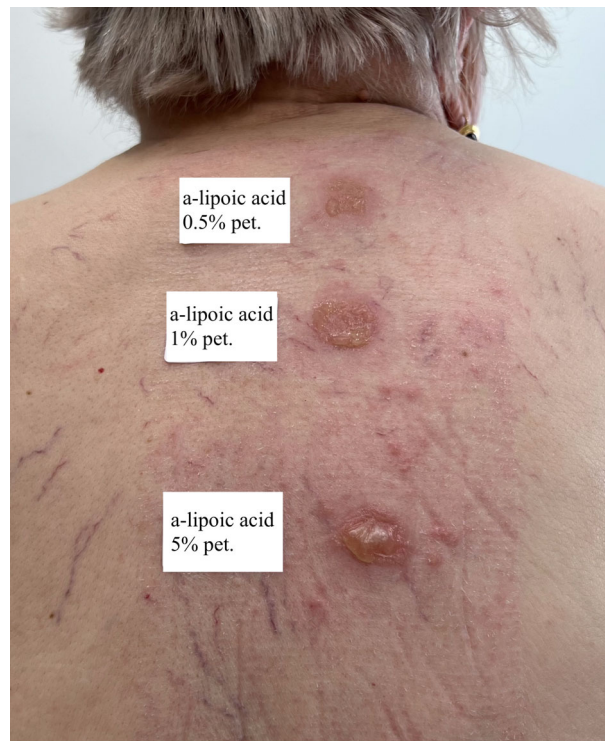Recently, a further case of allergic contact dermatitis caused by  $\alpha$ -LA (tested 3% aq.) in eye drops for dry eyes (containing 0.1%  $\alpha$ -LA) has been reported.<sup>3</sup>

In 2015, Rizzi et al. described a case of a pruritic maculopapular rash on the face and scalp after 10 days of treatment with dietary supplement containing  $\alpha$ -LA and other oral drugs. Patch tests were performed and gave a strong positive result (+++) at D2 and D3 for the dietary supplement and at D3 for all dilutions of  $\alpha$ -LA (0.025% petrolatum, 2.5% petrolatum and 5% petrolatum). Prick tests were also performed but resulted negative.<sup>6</sup>

To our knowledge, this is the first report of allergic contact dermatitis to  $\alpha$ -LA as a constituent of a topical treatment.

This case confirms the sensitizing properties of  $\alpha$ -LA and underlines the risk of using this molecule especially in areas at high risk of developing contact sensitization such as legs with chronic venous insufficiency or ulcers.

Performing patch tests with the patient's own products and their ingredients, may represent the key for identifying unusual relevant allergens.



**FIGURE 2** Strong positive reaction to  $\alpha$ -lipoic acid diluted, from top to bottom, in 0.5%, 1% and 5% petrolatum, at D3.

The most appropriate dilution/concentration for  $\alpha$ -LA to be used in patch tests deserves more studies.

#### AUTHOR CONTRIBUTIONS

**Monica Corazza:** Conceptualization; project administration; supervision; validation. **Edoardo Arlotti:** Conceptualization; data curation; validation; writing – original draft. **Natale Schettini:** Data curation; investigation; validation. **Lucrezia Pacetti:** Data curation; validation; writing – original draft. **Anna Bianchi:** Formal analysis; investigation; resources; validation. **Alessandro Borghi:** Conceptualization; project administration; supervision; validation.

#### CONFLICT OF INTEREST STATEMENT

The authors declare no conflicts of interest.

#### ORCID

Edoardo Arlotti  <https://orcid.org/0009-0008-4897-3633>

Natale Schettini  <https://orcid.org/0000-0002-6693-766X>

#### REFERENCES

1. Bergqvist-Karlsson A, Thelin I, Bergendorff O. Contact dermatitis to alpha-lipoic acid in an anti-wrinkle cream. *Contact Dermatitis*. 2006;55:56-57.
2. Leysen J, Aerts O. Further evidence of thioctic acid ( $\alpha$ -lipoic acid) being a strong cosmetic sensitizer. *Contact Dermatitis*. 2016;74:182-184.
3. Craig S, Urwin R, Wilkinson M. Contact allergy to thioctic acid present in Hypromellose<sup>®</sup> eye drops. *Contact Dermatitis*. 2017;76:361-362.
4. Stingeni L, Bianchi L, Hansel K, et al. Italian guidelines in patch testing—adapted from the European Society of Contact Dermatitis (ESCD). *G Ital Dermatol Venereol*. 2019;154:227-253.

5. Podda M, Zollner TM, Grundmann-Kollmann M, Thiele JJ, Packer L, Kaufmann R. Activity of alpha-lipoic acid in the protection against oxidative stress in skin. *Curr Probl Dermatol*. 2001; 29:43-51.
6. Rizzi A, Nucera E, Buonomo A, Schiavino D. Delayed hypersensitivity to  $\alpha$ -lipoic acid: look at dietary supplements. *Contact Dermatitis*. 2015; 73:62-63.

**How to cite this article:** Corazza M, Arlotti E, Schettini N, Pacetti L, Bianchi A, Borghi A. Allergic contact dermatitis due to  $\alpha$ -lipoic acid in a topical over-the-counter product: A case report. *Contact Dermatitis*. 2023;89(4):297-299. doi:10.1111/cod.14381

# The bitter side of nail art: A teenage girl's encounter with (meth)acrylate-induced allergic contact dermatitis from nail glue

Anna Sophie Quaade<sup>1</sup>  | Anne Birgitte Simonsen<sup>1,2</sup> 

<sup>1</sup>National Allergy Research Centre, Department of Dermatology and Allergy, Herlev-Gentofte University Hospital, Hellerup, Denmark

<sup>2</sup>Department of Dermatology and Allergy, Herlev-Gentofte University Hospital, Hellerup, Denmark

## Correspondence

Anna Sophie Quaade, National Allergy Research Centre, Department of Dermatology and Allergy, Herlev-Gentofte University Hospital, Hellerup, Denmark.  
Email: [anna.sophie.quaade@regionh.dk](mailto:anna.sophie.quaade@regionh.dk)

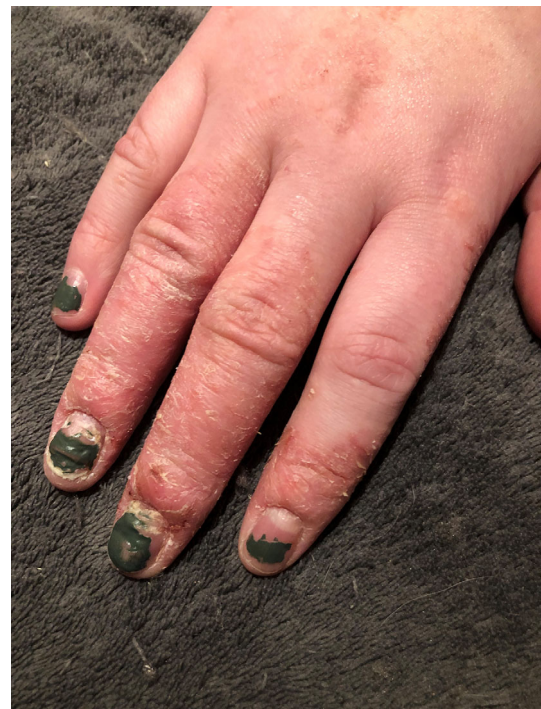**KEYWORDS:** acrylates, case report, contact allergy, cosmetics, ECA, ethyl cyanoacrylate, glue, nails

Cosmetic glues, widely available as home kits, are known to cause (meth)acrylate contact allergies in adults.<sup>1</sup> However, their impact on children and adolescents is less clear.

## CASE REPORT

A 13-year-old girl was referred to our dermatology clinic on suspicion of acrodermatitis continua of Hallopeau. For the past 9 months, she suffered from a painful rash on her fingers and disfiguring nail changes. Her medical history included grass allergy, but not atopic dermatitis. When asked about exposure, she described enjoying creative hobbies, including nail art. She regularly applied nail polish and pre-formed, press-on nails which were attached with nail glue. As the rash and nail changes appeared, she increased the use of press-on nails and nail polish to conceal the unsightly nail changes. Physical examination revealed severe pulpitis, with erythema, oedema, fissures, and scaling around the nails and dorsal aspects of her fingers and severe nail dystrophy (Figure 1). Mild nummular dermatitis was noted on the forearms but no skin changes on the elbows or knees.

According to the ingredient list, the nail glue (Super Strong Nail glue from Depend Cosmetic AB<sup>®</sup>) contained several allergens: poly methyl methacrylate (MMA), poly ethylene glycol dimethacrylate (EGDMA), 2-bromo-2-nitropropane-1,3-diol/bronopol, 2-tert-butyl-



**FIGURE 1** Severe pulpitis and nail dystrophy in a 13-year-old girl allergic to (meth)acrylates contained in a nail glue.