



## Clinical Management of Oral Lichen Planus: A Systematic Review



Luca Oberti<sup>1</sup>, Lucchese Alberta<sup>2</sup>, Petruzzi Massimo<sup>3</sup>, Carinci Francesco<sup>4</sup> and Lauritano Dorina<sup>1,\*</sup>

<sup>1</sup>Department of Medicine and Surgery, Centre of Neuroscience of Milan, University of Milano-Bicocca, 20126 Milan, Italy; <sup>2</sup>Multidisciplinary Department of Medical and Dental Specialties, University of Campania- Luigi Vanvitelli, 80138 Naples, Italy; <sup>3</sup>Interdisciplinary Department of Medicine, University of Bari, 70121 Bari, Italy; <sup>4</sup>Department of Morphology, Surgery and Experimental Medicine, University of Ferrara, 44121 Ferrara, Italy

**Abstract: Aim:** The clinical management of OLP represents a considerable challenge for the oral physician. The aim of this review is to assess the main intervention used in the management of OLP and the efficacy of every type of treatment.

**Materials and Methods:** We searched and analyzed PubMed database for articles on OLP management. Only randomized controlled trials, comparing an active treatment with placebo, or between different active treatments, were considered in this systematic review. Only patients with symptomatic OLP were included and interventions of all types were considered (topical treatment, systemic drugs, non pharmacological intervention).

**Results:** A total of 25 randomized controlled trials were examined and included in this review. Steroids are the most frequently employed drug in the treatment of OLP and their efficacy and safety are demonstrated. Also calcineurin inhibitors and photo-dynamic therapy are used in different studies for OLP management, with positive results.

**Conclusion:** Topical steroids remain the first-line treatment for symptomatic OLP, however, many different pharmacological and non-pharmacological therapies would represent a valid alternative for its management, but, nowadays they require further investigations.

### ARTICLE HISTORY

Received: April 17, 2018  
Revised: February 12, 2019  
Accepted: February 22, 2019

DOI:  
10.2174/1389557519666190301144157



CrossMark

**Keywords:** Calcineurin inhibitors, cytochrome P450, OLP randomized controlled trials, OLP treatment, oral lichen planus, Photo-dynamic therapy, steroids, cytokine, gene regulation, inflammation, interleukin-6.

### 1. INTRODUCTION

Oral lichen planus (OLP) is a chronic inflammatory immuno-mediated disorder that affects the epithelium of oral mucous membranes [1]. OLP has an overall prevalence of 0.2-2% [2], with a higher incidence in the female population (M:F = 1:2) [3]. The pathogenesis of OLP relates to an abnormal activation of CD8+ T-lymphocytes, which causes the destruction of basal cells of the epithelium [3].

OLP has different clinical presentations: the reticular form, which has characteristic white striae (Wickham striae); the atrophic-erosive type, with erythematous and ulcerated areas, often surrounded by white striae; the plaque-like form; the papular type and the bullous type. The most affected areas are the buccal mucosa and the dorsal surface of the tongue [4].

The main symptoms associated with OLP are pain and a localized burning sensation; lesions are typical of the

atrophic-erosive type, but are rarely present in reticular forms [3].

It is important to distinguish OLP from oral lichenoid lesions, which can be similar in appearance, but the latter represent a reaction to specific causal factors (e.g. dental materials, traumas, drugs) [5].

Managing OLP is aimed at reducing symptoms and the manifestation of lesions, characterized by periods of exacerbation and quiescence. The first-line treatment is represented by the use of topical corticosteroids, although other effective therapies, like photodynamic therapy and the use of calcineurin inhibitors have recently been made available.

### 2. MATERIALS AND METHODS

We examined the main publications related to OLP management, identified by searching the PubMed electronic database. We used the following search items: *oral lichen planus, oral lichen planus management, oral lichen planus treatment, oral lichen planus therapy, randomized trial oral lichen planus, oral lichen planus placebo, oral lichen planus*

\*Address correspondence to this author at the Department of Medicine and Surgery, Centre of Neuroscience of Milan, University of Milano-Bicocca, 20126 Milan, Italy; Tel: 00393356790163; E-mail: [dorina.lauritano@unimib.it](mailto:dorina.lauritano@unimib.it)

*steroids, oral lichen planus laser, oral lichen planus photodynamic therapy, oral lichen planus calcineurin inhibitors, and oral lichen planus curcumin.*

The search was run in September 2017 and a limited update literature search was performed in December 2017.

The results were automatically filtered in order to include only studies published in English, in the last 5 years (2013-2017). Literature reviews and case-reports were discarded, and only randomized clinical trials (RCTs) conducted in humans were considered.

Finally, we used the following eligibility criteria:

- Types of studies: randomized controlled trials.
- Publishing date: from 2013 to 2017.
- Publishing language: English language.
- Types of participants: patients over 18 years old with symptomatic, clinically or histologically diagnosed OLP, with no signs of dysplasia of lesions and without severe or uncontrolled systemic diseases.
- Types of intervention: comparison between different active treatments or between an active treatment and placebo.
- Types of outcome measures: symptoms and/or clinical aspects of lesions.

A total of 25 studies were included in our review. Excluding the literature reviews, 216 citations remained from the first search. Of these, 158 studies were selected, which were related to OLP treatment. After then excluding all the case-reports, cohort studies and non-randomized trials, 44 studies remained; 7 additional studies were discarded because the full texts were not available and 2 trials were excluded because they were not conducted in humans. Finally, 35 studies were examined, and 10 of these were not included in this review because they did not meet the eligibility criteria. Detailed procedures of the literature search and article screening are shown in Fig. (1).

Data on the characteristics of the population sample (number of patients, sex, age, clinical form of OLP), the therapeutic interventions (drugs used in the trial, route of administration, side effects, duration of follow-up) and on the results of each treatment were extracted from all the studies.

A total of 1060 patient samples were considered: the number of patients in each study was quite homogeneous, with an average of about 40-50 patients per study. The smallest sample was that examined by Kapoor *et al.* (2014), limited to 15 patients, while the largest trial was that conducted by Kazancioglu *et al.* (2015), consisting of 120 subjects.

Regarding the gender and age of patients, there was a similar distribution in all the studies: the sample predominantly contained females (the average percentage of female patients was 60-70%), with the average age of patients between 40 and 60 years old. This confirms the typical distri-

bution of the disease, with a higher prevalence in women after 40-50 years [7].

Concerning the clinical forms of OLP examined in the trials, it was observed that the majority of patients recruited for receiving different treatment were affected by atrophic-erosive lichen, which is the main symptomatic form of OLP. This is, moreover, in accordance with the main literature reviews, with our previous research articles and with the consensus conferences on the subject, which establish that OLP treatment is only recommended in cases of symptomatic lesions [6, 8, 9].

In detail, among all the trials considered, 13 exclusively concerned atrophic-erosive forms of OLP; 11 examined any form of symptomatic OLP, and only one study concerned exclusively symptomatic reticular forms.

## 2.1. Inclusion Criteria

The main inclusive criteria were:

- Clinical diagnosis of OLP.
- Histological diagnosis of OLP (according to WHO criteria, the characteristic histological features include infiltration of T-cells in a band-like pattern in the basal and subepithelial layer; thickening of the epithelium with superficial hyperkeratosis and parakeratosis; and vacuolar degeneration of the basal cells with the presence of numerous Civatte bodies);
- Presence of symptomatic lesions.

Apart from two studies, for which the diagnosis of OLP was only clinical [10, 11], all the trials examined also included histological confirmation of OLP in addition to the clinical diagnosis.

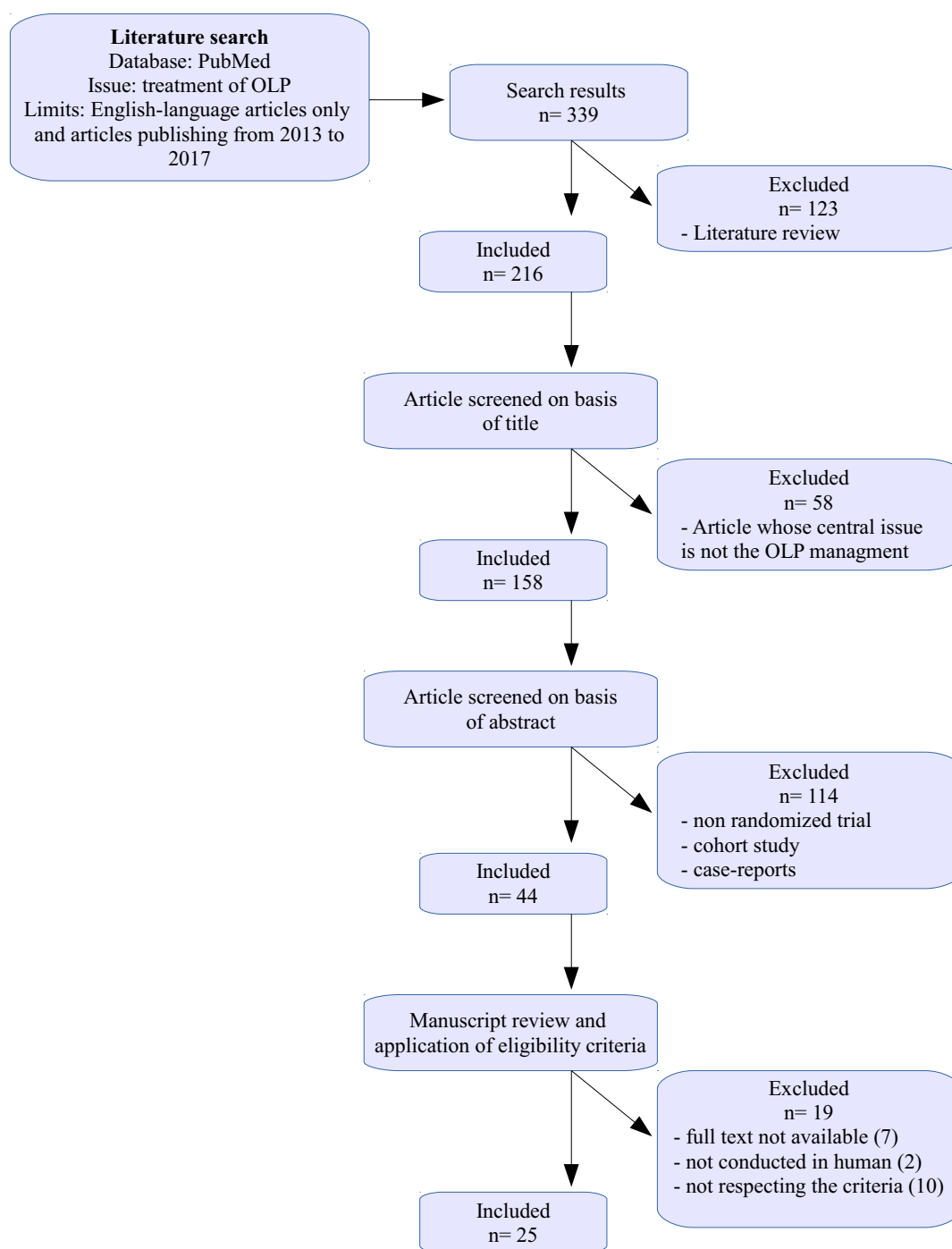
Furthermore, most of the studies conducted without the use of topical corticosteroids (first-choice therapy), but with a second-line therapy, recruited only patients who were previously subjected – unsuccessfully – to conventional treatment for OLP.

Finally, three studies also introduced a temporal inclusion criterion: the persistence of lesions (at least 2 months for Liu *et al.* and Amirchaghmaghi *et al.*, at least 1 year for Bacci *et al.*).

## 2.2. Exclusion Criteria

The exclusion criteria were much more varied; some studies were more restrictive and excluded patients with systemic diseases or who were undergoing any pharmacological therapy, while others selected larger samples of patients. In general, the main exclusion criteria were:

- Age < 18 years.
- Pregnancy or lactation.
- Uncontrolled systemic diseases (hepatopathies, coagulopathies, immune or haematological diseases, diabetes).



**Fig. (1).** Flow chart showing selection of studies for the review.

- History of allergic reactions to the active ingredient used in the clinical trial.
- Presence of histological signs of dysplasia in the biopsy specimen.
- Evidence of lichenoid lesions due to specific causes (dental materials, drugs inducing lichenoid reactions, *etc.*).
- Previous therapy for OLP in the period preceding experimentation (from 2 weeks to 3 months before

the trial; on average 2 weeks for topical treatments and 4 weeks for systemic therapy, as reported in the studies of Lee *et al.*, Lopez Jornet and Aznar-Cayuela, and Amirchaghmaghi *et al.*).

- Incompletion of the trial.

It should be noted that some studies also excluded smokers [11-13] or heavy drinkers of alcohol [11] and patients with genital or skin lichenoid lesions [14-18], or patients affected by other types of oral lesions, different from those caused by OLP [19-21].

Finally, all trials using curcumin excluded patients with a history of gastric or duodenal ulcers, due to the irritative effect of turmeric on gastro-intestinal mucosa, and patients undergoing orthodontic treatment [22, 23].

### 3. RESULTS

All 25 examined studies were randomized controlled trials; 22 of these were parallel group studies, 1 was a cross-sectional study [21] and 2 were split-mouth design studies [11, 12]. Furthermore, 4 were single-blind studies [14, 19, 24, 25] and 9 were double-blind studies [10, 16, 20-23, 26-28].

Table 1 and Fig. (1) show the main characteristics of the included studies.

#### 3.1. Study Design

Among all the studies, 7 compared active treatment with a placebo [10, 20, 21, 23, 28, 29], and one of these studies compared placebos with multiple treatments [30]. A total of 14 clinical trials compared two different active treatments [11-13, 15-18, 22, 26, 27, 31-34]; 3 studies compared two different drugs belonging to the same class [19, 26, 27]; finally, one study compared two different routes of administration of the same drug [14].

In these clinical trials, different therapeutic approaches to OLP were considered and compared, ranging from the more conventional treatments to the less consolidated ones.

In the analysed literature, the most frequently recurrent therapy was based on the use of topical corticosteroids [12-19, 22, 24, 25, 30-34], followed by photo-dynamic therapy [13, 17, 30, 32-34], then by treatment with calcineurin inhibitors, such as tacrolimus and pimecrolimus [15, 16, 26, 27, 31], and finally by topical therapy with curcumin gel [18, 22, 23]. We also observed the use of various other types of intervention, namely cryotherapy [12], ozone therapy [30], excisional surgery [11], inhibitors of neo-angiogenesis [24], tocopherol [21], hydroxychloroquine [10], chamomile [28], hyaluronic acid [29], and Glucosides of Paeony Capsule (GPC) [25].

#### 3.2. Outcomes

To evaluate the treatment efficacy, almost all the studies used the criteria of Carrozzo and Gandolfo, who divided treatment success according to: complete remission, partial resolution and non-success.

The outcomes evaluated regarding these therapeutic approaches were different; in relation to the symptomatology - generally characterized by a burning sensation and pain - the majority of studies evaluated symptoms by using the Visual Analog Scale (VAS), and 4 studies used the Numerical Rating Scale (NRS) [10, 11, 18, 19]. Only two studies did not consider symptomatology as an outcome [15, 27], while the results of one study were based exclusively on evaluating the improvement of symptoms, using the VAS [13].

The improvement of the clinical aspect of the lesions was assessed using the Thongprasom scale (5 = white striae with erosive area  $>1\text{ cm}^2$ , 4 = white striae with erosive area  $<1$

$\text{cm}^2$ , 3 = white striae with atrophic area  $>1\text{ cm}^2$ , 2 = white striae with atrophic area  $<1\text{ cm}^2$ , 1 = only white striae, 0 = no lesions); the principal exceptions are represented by some studies that used alternative scales, but were still comparable to the classification system of Thongprasom [15, 18, 20, 27], and three studies only recorded the dimensional change of the lesion without using any classification system [10, 19, 29].

In all the studies, measurements were made using a periodontal probe, a calibre, or a calibrated tongue depressor.

Alternative outcomes were the evaluation of histological changes [24]; the analysis of plasma IL-6 and IL-8 levels [27]; and the observation of an improvement in the quality of life after treatment using the Oral Health Impact Profile (OHIP-14, a scale that evaluates the functional alteration caused by the disease) [14, 28], the functional alteration scale of Lilleby [32] and the Hospital Anxiety-Depression Scale [28].

### 4. DISCUSSION

#### 4.1. Steroids

Topical application of corticosteroids is considered the first treatment for symptomatic OLP, due to their effectiveness and safety. Steroids have an important local anti-inflammatory action and they are able to suppress the immune activity of T lymphocytes [14].

There are many different corticosteroids that can be used in managing OLP, however, nowadays, the most widely recommended are triamcinolone acetonide 0.1%, which has the mildest action, clobetasol propionate 0.05% and dexamethasone 0.05%, which instead have greater anti-inflammatory activity [6].

In the examined trials, the most frequently used formulations were oral paste and oral gel for both triamcinolone and clobetasol while, dexamethasone was used as an oral solution for rinses, in the totality of these studies.

Topical application of the drug is always performed after oral hygiene, and in the 30 minutes following application the patient should not eat, drink or smoke [15, 26, 31].

In relation to treatment duration, studies have set different protocols; some of these, such as that conducted by Bakthiari *et al.* (2017) scheduled 2 weeks of treatment, others, such as that by Lee *et al.* (2013), instead continued treatment for 6 weeks, and others still for 2 months (Mostafa *et al.*, 2017). In general, most of the trials examined proposed an average duration of therapy for 4 weeks, with 2-4 applications per day. The majority of literature reviews recommend treatment of 1 month, as confirmed by Lodi *et al.* and Scully *et al.* [6, 8].

According to the study by Sivaraman *et al.* (2016), where the efficacy of topical triamcinolone and clobetasol was compared, the latter was observed to have a significantly greater efficacy and was able to improve symptoms and reduce the clinical appearance of lesions after treatment of just 1 week. This observation is in line with the literature on the subject; Gupta *et al.* described that clobetasol is the first-choice drug in the treatment of OLP, because of its major efficacy compared to triamcinolone [8, 35].

Table 1. Characteristics of included studies.

Study (First Author, Year)	No. of Patients and Intervention	Outcomes	Duration and Follow-up
Lee, 2013	20= 0,4% triamcinolone acetonide mouth rinse 20= 0,5 ml intralesional triamcinolone acetonide	VAS, OHIP-14, Escudier Scoring System	6 weeks (1 year follow-up)
Liu, 2013	30= 1,4 mg intralesional betamethasone 31= 8 mg intralesional triamcinolone acetonide	NRS, Extension of the lesion	14 days
Arduino, 2013	15= 1% pimecrolimus cream + miconazole gel + chlorhexidine 15= 0,1% tacrolimus ointment + miconazole gel + chlorhexidine	VAS, Thongprasom clinical grading	2 months (6 months follow-up)
Bendas, 2013	11= 20 mg hydroxychloroquine niosomes 5= placebo	NRS, Extension of the lesion	4 months
Siviero-Dillinburg, 2014	21= 0,05% clobetasol propionate gel + nystatin rinses 21= laser phototherapy (660 nm)	VAS, Thongprasom clinical grading, Lilleby scores	30 days (90 days follow-up)
Amanat, 2014	30= one side lesion: 0,1% triamcinolone acetonide paste + nystatin rinses, other side lesion: cryotherapy (max -89 °C)	VAS, Thongprasom clinical grading	6 weeks
Kapoor, 2014	15= right side lesion: excisional biopsy with resorbable membrane, left side lesion: excisional biopsy without membrane	Extension of the lesion, symptoms record	24 weeks follow up
Arunkumar, 2015	15= 1% pimecrolimus cream 15= 0,1% triamcinolone acetonide paste	VAS, Thongprasom clinical grading	2 months (4 months follow-up)
Vohra, 2015	20= 0,1% tacrolimus ointment 20= 1% pimecrolimus cream	NCS (modified Piboonnnyom scale), serum IL-6, IL-8 levels	8 weeks (12 weeks follow up)
Jajarm, 2015	11= laser phototherapy (630 nm) with toluidine blue 14= 0,5 mg/ml dexamethasone mouth-wash + nystatin rinses	VAS, Thongprasom clinical grading	4 weeks (8 weeks follow-up)
El Shenawy, 2015	12= laser phototherapy (970 nm) 12= 0,1% triamcinolone acetonide orobase	VAS	8 and 4 weeks respectively
Kazancioglu, 2015	30= low level laser therapy (808 nm) 30= ozone therapy (60% ozone) 30= dexamethasone mouth-wash + nystatin rinses 30= placebo	VAS, Thongprasom clinical grading	1 months (6 months follow-up)
Kia, 2015	25= 5% curcumin paste 25= 0,1% triamcinolone acetonide paste	VAS, Thongprasom clinical grading	4 weeks
Amirchaghmaghi, 2015	15= 250 mg quercetin capsules + dexamethasone + nystatin 15= placebo + dexamethasone + nystatin	VAS, Extension of the lesion	4 weeks (8 weeks follow-up)
Sivaraman, 2016	10= 0,1% triamcinolone acetonide paste 10= 0,05% clobetasol propionate paste 10= 0,03% tacrolimus paste	Modified Thongprasom clinical grading	6 weeks (3 months follow-up)
Hettiarachichi, 2016	34= 0,1% tacrolimus cream + nystatin rinses 34= 0,05% clobetasol propionate cream + nystatin rinses	VAS, Thongprasom clinical grading	3 weeks (5 weeks follow-up)
Amirchaghmaghi, 2016	12= 95% curcuminoid tablets + dexamethasone + nystatin 8= placebo + dexamethasone + nystatin	VAS, Thongprasom clinical grading	4 weeks
Mahmoud, 2016	20= 2,5 mg intralesional bevacizumab 20= 0,1% triamcinolone acetonide ointment	VAS, Thongprasom clinical grading, histopat. examination	3 weeks (12 weeks follow-up)
Raviraj-Shetty, 2016	25= 0,2% hyaluronic acid paste 25= placebo	VAS, Extension of the lesion	14 days (28 days follow-up)
Lopez-Jornet, 2016	26= 2% <i>Chamaemelum nobile</i> gel 29= placebo	VAS, Thongprasom clinical grading, OHI-14, HAD scale	4 weeks
Zhou, 2016	17= 0,1% dexamethasone powder 22= 0,1% dexamethasone powder + 400 mg TGPC (paeony) 17= 15 mg oral prednisolone 17= 15 mg oral prednisolone + 400 mg TGPC (paeony)	VAS, Thongprasom clinical grading	Till resolution of symptoms (6 months follow-up)
Bakhtiari, 2017	15= 0,5 mg/ml dexamethasone mouth-wash + nystatin rinses 15= LED phototherapy with methylene blue	VAS, Thongprasom clinical grading	2 weeks (90 days follow-up)
Mostafa, 2017	10= 0,1% triamcinolone acetonide paste 10= laser phototherapy (660 nm) with methylene blue	VAS, Thongprasom clinical grading	2 months
Thomas, 2017	25= 0,1% triamcinolone acetonide paste 25= 1% curcumin gel (3vv/die) 25= 1% curcumin gel (6 vv/die)	NRS, MOMI scale	3 months
Bacci, 2017	16= first placebo and then tocopherol acetate gel 17= first tocopherol acetate gel and then placebo	VAS, Thongprasom clinical grading, length of striae	8 weeks (10 weeks follow-up)

Intralesional injections of corticosteroids represent an effective treatment for OLP, which can guarantee a significant improvement of symptoms, and lead to the healing of lesions, but it is only reserved for the most serious cases that do not respond to topical therapy [6]. The analysed articles show a protocol for this treatment characterized by one injection per week, which should be performed in the sub-epithelial connective tissue, for about 2-4 weeks [14, 19]; in particular Liu *et al.* (2013) compared injections with triamcinolone and injections with betamethasone and they highlighted that betamethasone is significantly more effective [19]. Moreover, Lee *et al.* (2013) observed that there were no statistically significant differences between the topical application and the intralesional injections of triamcinolone. Lodi *et al.* reported the efficacy of steroid injections, and confirmed that triamcinolone is the most used drug [6].

Thongprasom and Dhanuthai found that intralesional injection of steroids gave variable results; in addition, they can be painful and have localized side effects such as mucosal atrophy [36]. It should be noted that the use of topical steroids is associated with various side effects, probably more so than those induced by many other second-line drugs, but not too serious to prevent their use [8]; the analysed studies demonstrated two main adverse effects, namely a burning sensation and irritation of the mucous membranes, and oral candidiasis [14], the latter is easily resolvable by adding antifungal drugs to the therapy, such as rinsing with nystatin (100000 U/ml, 3 times a day) or application of miconazole gel (2%, once a day) [16, 26].

Gonzalez-Moles reported that the only adverse effect with long-term use of topical steroids is oral candidiasis [37]. Alrashdan *et al.* reported that systemic absorption of topical steroids has been described in different studies but, in almost all cases, it has no clinical relevance [3]. Ramadas *et al.* conducted a clinical trial on the systemic absorption of 0.1% triamcinolone acetonide and they found that, at the indicated doses, the drug is completely safe and does not cause any systemic absorption [38].

The side effects of corticosteroids in injection solutions are, instead, less frequent [14], but much more serious, as when they are systemically absorbed, they can possibly cause transient hyperglycaemia and cushingoid features [19].

Topical corticosteroid therapy thus remains the first-line treatment for OLP [3, 6, 8, 35]. The percentage of complete remission of lesions after topical steroid therapy varies between 47 and 75%, with a high number of cases of partial remission [30, 32].

Lodi *et al.* reported that there is insufficient evidence to establish that a specific corticosteroid is more effective than others in the treatment of OLP [39]. Furthermore, Farhi e Dupin described that there is no reliable evidence to support a greater efficacy of certain topical steroid formulations compared to others [40].

#### 4.2. Calcineurin Inhibitors

Calcineurin inhibitors are immunomodulatory drugs with inhibitory activity towards calcineurin, a calcium-dependent

protein with phosphatase activity, responsible for the immune response [16, 31].

This group of drugs includes tacrolimus, pimecrolimus and cyclosporine.

Tacrolimus (0.1%) and pimecrolimus (1%) represent alternatives for patients who are refractory to steroid therapy. Conrotto *et al.* and Yoke *et al.* found that cyclosporine did not provide any additional benefit compared to steroids, and responses were comparable to those of steroids. For this reason, cyclosporine cannot be used as a first-line treatment for OLP [41, 42].

Tacrolimus and pimecrolimus are well-tolerated drugs, especially pimecrolimus [31]; the most common side effects associated with this therapy are hyperpigmentation of the mucous membranes, a transient burning sensation immediately after application [16], xerostomia, and gastro-oesophageal reflux [26]. Guo *et al.* reported no adverse effects, while Resende *et al.* described mild and transient side effects [43, 44]. Ribero *et al.* also found that patients reported a transitory burning sensation and altered taste sensation [45].

Our review of randomized controlled trials shows discordant results; according to Sivaraman *et al.* (2016), corticosteroids are significantly more effective than tacrolimus, while Arunkumar *et al.* (2015) showed that there were no statistically significant differences; Hettiarachchi *et al.* (2016) instead reported that tacrolimus was more effective in the treatment of OLP [15, 16, 31].

Radfar *et al.* and Guo *et al.* both reported that there was no evidence to support that topical tacrolimus was more effective and safer than topical corticosteroids for OLP management [43, 46], while Resende *et al.* reported an improvement in all 15 patients treated with tacrolimus, with a complete remission in 86% of cases [44]. Sonthalia *et al.* described a 95% of either complete or partial remission after a 2-month treatment with tacrolimus [47]. After the same therapy period Malik *et al.* found a complete remission in 55% cases of patients treated with tacrolimus [48].

Conversely, in the retrospective analysis conducted by Ribero *et al.*, only 20% of patients achieved complete remission at 2 months, and 33% achieved remission after a 6-month treatment with tacrolimus [45]. The average duration of tacrolimus treatment is 2 months, with four applications per day.

It is evident, both from the study by Arduino *et al.* (2013) and from the trial conducted by Vohra *et al.* (2015), that both tacrolimus and pimecrolimus have been shown to be efficient in improving symptoms and in reducing the clinical appearance of lichenoid lesions, but that there are no statistically significant differences between these two drugs in relation to their efficacy [26, 27]. However, it seems that treatment with pimecrolimus tends to guarantee more stable results over time, with a lower risk of relapse, according to that described by Arduino *et al.* [26]. In contrast with the analysed trials, Lodi *et al.* reported that there is no reliable evidence to show that pimecrolimus is more effective than a placebo [39].

These drugs must be investigated further to solve two main problems related to their use, namely the possible systemic absorption observed in some studies [26], and the potential malignant transformation that the drug may possibly induce [26, 31].

For these reasons, the majority of the studies published on this issue do not consider calcineurin inhibitors as a suitable first-line therapy. In contrast, Resende *et al.* and Shipley and Spivakovsky concluded that tacrolimus 0.1% could be used as a first-line therapy because it is a safe and effective medication that improves the clinical appearance of the lesion and reduces pain, as well as the histopathological features of OLP [44, 49].

#### 4.3. Comparison between Corticosteroids and Photodynamic Therapy

Photodynamic therapy for treating OLP exploits two different actions, namely biostimulation induced by a laser, generally a diode laser with variable wavelength (630-980 nm), and the release of reactive oxygen species (ROS) by the irradiated photosensitive substance [6, 34, 50, 51].

Thus, photodynamic therapy functions by enhancing phagocytic activity, increasing the number of lymphatic vessels and their diameter, through the normalization of capillary permeability and by rebalancing the microcirculation [30].

This is a safe procedure that does not expose the patient to bleeding or to scar formation [17, 32]. A burning sensation and local oedema are the only known side effects [17]. The treatment protocol is very similar in all the studies carried out, and is characterized by one-three sessions of 2-2.5 minutes per week for 2 months [13, 17, 30, 32, 34]. Jajarm *et al.* (2015) advised performing two sessions of photodynamic therapy per day instead of just one [34].

Among the six studies using this treatment method, four of them use only a laser and two combine the action of the laser with that of the photosensitive agent; Jajarm *et al.* used toluidine blue, while Mostafa *et al.* (2017) used methylene blue [17, 34].

Kvaal *et al.* found that topical methyl 5-aminolevulinate (MAL) photodynamic therapy showed lasting improvement after a single treatment [50], while Sobaniec *et al.* obtained excellent results using a gel containing 20% chlorin e6-polyvinylpyrrolidone and 10% dimethyl sulfoxide, which was applied directly onto the lesion [52].

Comparing the effectiveness between photodynamic treatment and application of topical steroids, some authors, including Dillenburg *et al.* (2014), Bakhtiari *et al.* (2017), and Jajarm *et al.* reported that there were no statistically significant differences [32-34], but rather, according to Jajarm *et al.* dexamethasone would be significantly more effective than laser therapy in improving the symptoms due to OLP [34]. According to El Shenawy and Eldin (2015) and Kazancioglu and Erisen (2015), photodynamic therapy is significantly less efficient than topical application of corticosteroids for treating OLP [13, 30]. Conversely, the study by Mo-

stafa *et al.* reported that the effectiveness of photodynamic therapy was significantly greater than that of steroid therapy for OLP [17].

Al-Maweri *et al.* confirmed that low-level laser therapy is effective in managing symptomatic OLP, and can be used as an alternative to corticosteroids. However, due to various methods and substantial variations in laser parameters, more RCTs with larger sample sizes are highly warranted [53]. Spanemberg *et al.* concluded that the use of laser treatment for OLP lesions has already been consolidated and is safe; nevertheless, further research is needed, especially randomized, controlled clinical trials with long-term follow-up in order to create care protocols for managing oral disorders [54].

This therapeutic approach, therefore, does not represent a first-line treatment, but may play an important role in OLP patients who do not tolerate topical corticosteroid therapy, or those who are unresponsive to this treatment [6].

#### 4.4. Curcumin

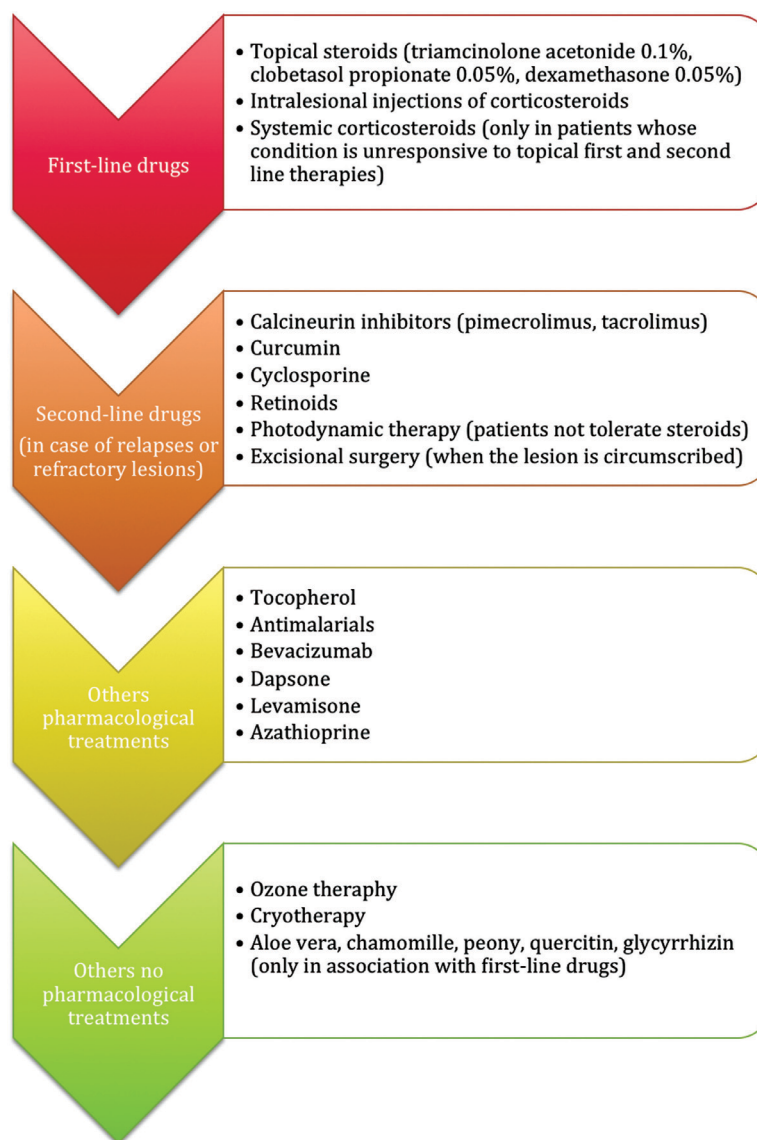
Curcumin is one of the three curcuminoids contained in *Curcuma Longa*, a plant often used in oriental medicine due to its well-known anti-inflammatory, antioxidant, biostimulant and anti-cancer properties [22, 35]. Its anti-inflammatory activity is expressed by inhibiting arachidonic acid metabolism that reduces the synthesis of prostaglandins and leukotrienes; moreover, it can modulate the immune response by stimulating the activation of macrophages, T lymphocytes and natural killer lymphocytes [18]. The analysed studies show that there are no statistically significant differences between the use of a 5% curcumin oral paste and the use of topical triamcinolone [22]. Singh *et al.* described curcumin as a new safe option for treating OLP, but they found that its effectiveness is lower than that of steroids [55].

Chainani-Wu *et al.* conducted two studies using two different doses of curcuminoid; with a low-dose of curcumin, no significant effects were observed in patients, so they could not conclude whether curcumin is effective for managing OLP. The second trial, with an increased dose of curcumin, reported a greater reduction in clinical signs and symptoms compared to the placebo. For this reason, they concluded that curcumin - at a dose of 6 g per day - is efficacious in managing OLP, with no side effects [56, 57].

According to Thomas *et al.* (2017), the use of lower percentages of curcumin (for example 1%) is significantly less efficient compared to topical corticosteroids [18]. Finally, the study conducted by Amirchaghmaghi *et al.* (2016) reported no significant differences between the use of soluble tablets of curcumin and placebo [23].

#### 4.5. Other Pharmacological Treatments

In recent years, many experimental treatments have been proposed for managing OLP, however, only a few of them have been shown to be really effective and, even then, it is still necessary to carefully study their effects, evaluating their efficacy through more clinical trials on larger samples.



**Fig. (2).** List of therapies according to effectiveness for OLP treatment.

The most used drugs are:

- Cyclosporine (topical application or rinses), which are able to reduce inflammation by inhibiting synthesis of cytokines; however, they have a high cost, a bad taste and they cause a transient burning sensation immediately after application [6, 35].
- Topical retinoids or, rarely, systemic retinoids, that have antioxidant action [51, 58]. Scardina *et al.* reported that, with isotretinoin, none of the cases of reticular OLP showed improvement, while 35% patients with erosive OLP responded favourably to a high concentration of isotretinoin. Dalirsani *et al.* compared vitamin A as a mouthwash with triamcinolone for managing OLP, and it was seen that combining triamcinolone and vitamin A mouthwash was more effective in the clinical resolution of lesions compared to triamcinolone mouthwash alone. However, topical retinoids should be considered as a second-line therapy for treating OLP [59, 60].
- Tocopherol, an important antioxidant, is able to contribute to the integrity of the cell membrane. According to a cross-sectional study conducted by Bacci *et al.* (2017), tocopherol could significantly reduce the extent of the lesions in OLP, without, however, leading to an improvement in symptoms [21].
- Antimalarial drugs can induce improvements in patients with OLP [61], although they may be involved in the genesis of lichenoid reactions [6]. The most used antimalarial drug is hydroxychloroquine, which seems to be significantly effective in treating OLP, as shown by a study by Bendas *et al.* (2013), where, after a 4-month treatment, an evident improvement of the lesions was obtained without collateral effects and without relapse [10]. Rivas-Tolosa *et al.* confirmed with their trial that antimalarial drugs could be useful for treating oral erosive lichen planus, because they are easily administered and affordable, with few adverse effects [61].



In the examined clinical trials, the use of different drugs was tested; Raviraj-Shetty *et al.* (2016) obtained significant results using a 0.2% hyaluronic acid paste [29]; Lopez Jornet and Aznar-Cayueta (2016) conducted a study on patients with OLP treated with chamomile gel (*Chamaemelum nobile*), and observed a complete remission in 20% of patients, obtaining (in relation to the improvement of symptoms) statistically significant results [28].

Zhou *et al.* (2016) demonstrated that the use of topical dexamethasone associated with total GPC, a substance typical of Chinese medicine with anti-inflammatory, immunoregulatory and antioxidant properties, allows better results to be obtained compared to the exclusive use of corticosteroids. These findings only emerge when the total GPCs are taken for a long time, at least 4 months [25].

Mahmoud and Afifi (2016) instead proposed the use of intralesional injections of bevacizumab, an anti-angiogenic agent, in patients suffering from atrophic-erosive lichen planus, and they obtained histological and clinical improvements, which were significantly greater than those treated with topical triamcinolone [24].

Finally, a study conducted by Amirchaghmaghi *et al.* (2015) on quercetin, a flavonoid with anti-inflammatory, antioxidant and anti-cancer properties, showed that it had no statistically significant efficacy [20].

#### 4.6. Other Non-pharmacological Treatments

Kazancioglu and Erisen (2015) proposed ozone therapy as a treatment for OLP; this method was effective in both reducing the symptoms and improving the clinical appearance of the lesions, with significantly better results than those treated with placebo or with laser therapy, and comparable to those obtained with topical application of corticosteroids [30].

Moreover, Amanat *et al.* (2014) showed that cryotherapy (-89°C under local anaesthesia of the affected mucosa), which could be a proposed method for treating OLP, does not show better results than patients treated with topical steroids [12]. Evidence-based data on the use of these techniques for managing OLP are lacking as there are insufficient RCTs in the literature, but these modalities may serve as potential therapies for treating refractory OLP [35].

Nowadays, therefore, the preferential non-pharmacological treatment, in addition to photodynamic therapy, is surgical excision [6]. In this case, application of resorbable membranes after excision does not seem to achieve better results, as demonstrated by Kapoor *et al.* (2014).

Axell and Henriksen conducted a study in which, after surgical excision of the lesion, the surgical site received a soft tissue graft; the healthy graft remained free of lesions and appeared clinically healthy at follow-up visits [62].

#### CONCLUSION

The examined studies confirm that the most efficient and effective therapy in patients with symptomatic OLP is topical treatment with corticosteroids, which, nowadays, remains the first-line therapy for this type of lesion [35]. The use of

intralesional steroids, although fairly uncommon, can represent a valid alternative in cases that only partially respond to topical steroid therapy [6], while the use of systemic corticosteroids is only indicated in patients whose condition is unresponsive to topical first- and second-line therapies, or with a relevant involvement of oral mucosa [8].

From our review of RCTs of OLP, which can also be seen from other literature reviews, it can be concluded that, in the case of relapses or refractory lesions, second-line therapy consists of the use of calcineurin inhibitors, and in the use of topical preparations of curcumin and retinoids [51]. Photodynamic therapy is another valid choice in all these cases [50] and, when the lesion is circumscribed, excisional surgery also represents an important alternative in OLP [6].

Fig. (2) shows the main treatment modalities for managing OLP. Numerous nutraceutical treatments need to be investigated further with other randomized trials; they can now only be applied in association with the common first-line therapies.

None of the other therapies have been found to be better than topical steroids for managing OLP; for this reason, the use of other therapies should only be reserved for extensive lesions and refractory cases, and should only be prescribed by a specialist physician.

#### CONSENT FOR PUBLICATION

Not applicable.

#### STANDARDS FOR REPORTING

The authors confirm that all procedure have been reported according to PRISMA guidelines.

#### FUNDING

None.

#### CONFLICT OF INTEREST

The authors declare no conflict of interest, financial or otherwise.

#### ACKNOWLEDGEMENTS

Declared none.

#### REFERENCES

- [1] Mustafa, M.B.; Porter, S.R.; Smoller, B.R.; Sitaru, C. Oral mucosal manifestations of autoimmune skin diseases. *Autoimmun Rev.*, **2015**, *14*, 930-951.
- [2] Bascones-Martinez, A.; Garcia-Garcia, V.; Meurman, J.H. Requena-Caballero L. Immune-mediated diseases: What can be found in the oral cavity? *Int. J. Dermatol.*, **2015**, *54*, 258-270.
- [3] Alrashdan, M.S.; Cirillo, N.; McCullough, M. *Oral lichen planus: A literature review and update. Arch. Dermatol. Res.*, **2016**, *308*, 539-551.
- [4] Andreasen, J.O. Oral lichen planus: A clinical evaluation of 115 cases. *Oral Surg. Oral Med. Oral Pathol.*, **1968**, *25*, 31-41.
- [5] Gissi, D.B.; Venturi, M.; Gabusi, A.; De Martino, A.; Montebugnoli, L. Le patologie autoimmunitarie del cavo orale. *Rev. Health Care*, **2011**, *2(2)*, 33-55.
- [6] Lodi, G.; Scully, C.; Carrozzo, M.; Griffiths, M.; Sugarman, P.B.; Thongprasom, K. Current controversies in oral lichen planus: Re-

- port of an international consensus meeting. Part 2. Clinical management and malignant transformation. *Oral Surg. Oral Med. Oral Pathol. Oral Radiol. Endod.*, **2005**, *100*, 164-178.
- [7] Lodi, G.; Scully, C.; Carrozzo, M.; Griffiths, M.; Sugerma, P.B.; Thongprasom, K. Current controversies in oral lichen planus: report of an international consensus meeting. Part 1. Viral infections and etiopathogenesis. *Oral Surg. Oral Med. Oral Pathol. Oral Radiol. Endod.*, **2005**, *100*(1), 40-51.
- [8] Scully, C.; Beyli, M.; Ferreira, M.C.; Ficarra, G.; Gill, Y.; Griffiths, M.; Holmstrup, P.; Mutlu, S.; Porter, S.; Wray, D. Update on oral lichen planus: Etiopathogenesis and management. *Crit. Rev. Oral Biol. Med.*, **1998**, *9*(1), 86-122.
- [9] Al-Hashimi, I.; Schifter, M.; Lockhart, P.B.; Wray, D.; Brennan, M.; Migliorati, C.A.; Axéll, T.; Bruce, A.J.; Carpenter, W.; Eisenberg, E.; Epstein, J.B.; Holmstrup, P.; Jontell, M.; Lozada-Nur, F.; Nair, R.; Silverman, B.; Thongprasom, K.; Thornhill, M.; Warnakulasuriya, S. Van der Waal I. Oral lichen planus and oral lichenoid lesions: Diagnostic and therapeutic considerations. *Oral Surg. Oral Med. Oral Pathol. Oral Radiol. Endod.*, **2007**, *103*(1), 1-25, 12.
- [10] Bendas, E.R.; Abdullah, H.; El-Komy, M.H.M.; Kassem, M.A.A. Hydroxychloroquine niosomes: A new trend in topical management of oral lichen planus. *Int. J. Pharm.*, **2013**, *458*, 287-295.
- [11] Kapoor, A.; Sikri, P.; Grover, V.; Malhotra, R.; Sachdeva, S. Evaluation of efficacy of a bioresorbable membrane in the treatment of oral lichen planus. *Dent. Res. J.*, **2014**, *11*(3), 386-394.
- [12] Amanat, D.; Ebrahimi, H.; Zahedani, M.Z.; Zeini, N.; Pourshahidi, S.; Ranjbar, Z. Comparing the effects of cryotherapy with nitrous oxide gas versus topical corticosteroids in the treatment of oral lichen planus. *Indian J. Dent. Res.*, **2014**, *25*(6), 711-716.
- [13] El Shenawy, H.M.; Eldin, A.M. A comparative evaluation of low-level laser and topical steroid therapies for the treatment of erosive-atrophic lichen planus. *Maced. J. Med. Sci.*, **2015**, *3*(3), 462-466.
- [14] Lee, Y.C.; Shin, S.Y.; Kim, S.W.; Eun, Y.G. Intralesional injection versus mouth rinse of triamcinolone acetonide in oral lichen planus: a randomized controlled study. *Otolaryngology-Head and Neck Surgery*, **2013**, *148*(3), 443-449.
- [15] Sivaraman, S.; Santham, K.; Nelson, A.; Laliytha, B.; Azhalvel, P.; Deepak, J.H. A randomized triple-blind clinical trial to compare the effectiveness of topical triamcinolone acetonate (0.1%), clobetasol propionate (0.05%), and tacrolimus orabase (0.03%) in the management of oral lichen planus. *J. Pharm. Bioall. Sci.*, **2015**, *8*(5), 86-89.
- [16] Hettiarachchi, P.V.K.S.; Hettiarachchi, R.M.; Jayasinghe, R.D.; Sitheequ, M. Comparison of topical tacrolimus and clobetasol in the management of symptomatic oral lichen planus: A double-blinded, randomized clinical trial in Sri Lanka. *J. Invest. Clin. Dent.*, **2016**, *2016*, 1-6.
- [17] Mostafa, D.; Moussa, E.; Alnouaem, M. Evaluation of photodynamic therapy in treatment of oral erosive lichen planus in comparison with topically applied corticosteroids. *Photodiagnosis Photodyn. Ther.*, **2017**, *19*, 56-66.
- [18] Thomas, A.E.; Varma, B.; Kurup, S.; Jose, R.; Chandy, M.L.; Kumar, S.P.; Aravind, M.S.; Ramadas, A.A. Evaluation of efficacy of 1% curcuminoids as local application in management of oral lichen planus: interventional study. *J. Clin. Diagn. Res.*, **2017**, *11*(4), ZC89-ZC93.
- [19] Liu, C.; Xie, B.; Yang, Y.; Lin, D.; Wang, C.; Lin, M.; Ge, L.; Zhou, H. Efficacy of intralesional betamethasone for erosive oral lichen planus and evaluation of recurrence: A randomized, controlled trial. *Oral Surg. Oral Med. Oral Pathol. Oral Radiol.*, **2013**, *116*, 584-590.
- [20] Amirchaghmaghi, M.; Delavarian, Z.; Iranshahi, M.; Taghi, Shakeri, M.; Mozafari, P.M.; Mohammadpour, A.H.; Farazi, F.; Iranshahi, M. A randomized placebo-controlled double blind clinical trial of quercetin for treatment of oral lichen planus. *J. Dent. Res. Dent. Clin. Dent. Prospect.*, **2015**, *9*(1), 23-28.
- [21] Bacci, C.; Vanzo, V.; Frigo, A.C.; Stellini, E.; Sbricoli, L.; Valenti, M. Topical tocopherol for treatment of reticular oral lichen planus: A randomized, double-blind, crossover study. *Oral Diseases*, **2017**, *23*, 62-68.
- [22] Kia, S.J.; Shirazian, S.; Mansourian, A.; Fard, L.K.; Ashnagar, S. Comparative efficacy of topical curcumin and triamcinolone for oral lichen planus: A randomized, controlled clinical trial. *JDTUMS.*, **2015**, *12*, 11.
- [23] Amirchaghmaghi, M.; Pakfetrat, A.; Delavarian, Z.; Ghalavani, H.; Ghazi, A. Evaluation of the efficacy of curcumin in the treatment of oral lichen planus: A randomized controlled trial. *J. Clin. Diagn. Res.*, **2016**, *10*(5), ZC134-ZC137.
- [24] Mahmoud, M.M. Afifi, M.M. Anti-angiogenic therapy (bevacizumab) in the management of oral lichen planus. *Eur. J. Oral Sci.*, **2016**, *124*, 119-126.
- [25] Zhou, L.; Cao, T.; Wang, Y.; Yao, H.; Du, G.; Tian, Z.; Tang, G. Clinical observation on the treatment of oral lichen planus with total glucosides of peony capsule combined with corticosteroids. *Int. J. Immuno. pharmacol.*, **2016**, *36*, 106-110.
- [26] Arduino PG, Carbone M, Della Ferrera F, Elia A, Conrotto D, Gambino, A.; Comba, A.; Calogiuri, P.L.; Broccoletti, R. Pimecrolimus vs. tacrolimus for the topical treatment of unresponsive oral erosive lichen planus: an 8 week randomized double-blind controlled study. *JEADV*, **2014**, *28*, 475-482.
- [27] Vohra, S.; Singal, A.; Sharma, S.B. Clinical and serological efficacy of topical calcineurin inhibitors in oral lichen planus: A prospective randomized controlled trial. *Int. J. Dermatol.*, **2016**, *55*, 101-105.
- [28] Lopez, J.P.A.C.C. Efficacy of topical chamomile management vs placebo in patients with oral lichen planus: A randomized double-blind study. *JEADV.*, **2016**, *30*, 1783-1786.
- [29] Raviraj-Shetty, R.; Burde, K.N.; Guttal, K.S. The efficacy of topical hyaluronic acid 0.2% in the management of symptomatic oral lichen planus. *J. Clin. Diagn. Res.*, **2016**, *10*(1), ZC46-ZC50.
- [30] Kazancioglu, H.O.; Erisen, M. Comparison of low-level laser therapy versus ozone therapy in the treatment of oral lichen planus. *Ann. Dermatol.*, **2015**, *27*(5), 485-491.
- [31] Arunkumar, S.; Kalappanavar, A.; Annigeri, R.G.; Kalappa, S.G. Relative efficacy of pimecrolimus cream and triamcinolone acetonide paste in the treatment of symptomatic oral lichen planus. *Indian J. Dent.*, **2015**, *6*(1), 14-19.
- [32] Dillenburg, C.S.; Martins, M.A.T.; Munerato, M.C.; Marques, M.M.; Carrard, V.C.; Filho, M.S.A.; Castilho, R.M.; Martins, M.D. Efficacy of laser phototherapy in comparison to topical clobetasol for the treatment of oral lichen planus: A randomized controlled trial. *J. Biomed. Opt.*, **2014**, *19*(6), 068002-1,1-9.
- [33] Bakhtiari, S.; Mojahedi, S.M.; Azari-Marhabi, S.; Namdari, M.; Rankohi, Z.E. Comparing clinical effects of photodynamic therapy as a novel method with topical corticosteroid for treatment of oral lichen planus. *Photodiagnosis Photodyn. Ther.*, **2017**, *20*, 159-164.
- [34] Jajarm, H.H.; Falaki, F.; Sanatkhan, M.; Ahmadzadeh, M.; Ahrari, F.; Shafae, H. A comparative study of toluidine blue-mediated photodynamic therapy versus topical corticosteroids in the treatment of erosive-atrophic oral lichen planus: A randomized clinical controlled trial. *Lasers Med. Sci.*, **2015**, *30*, 1475-1480.
- [35] Gupta, S.; Ghosh, S. Interventions for the management of oral lichen planus: A review of the conventional and novel therapies. *Oral Dis.*, **2017**, *23*(8), 1029-1042.
- [36] Thongprasom, K.; Dhanuthai, K. Steroid in the treatment of lichen planus: A review. *J. Oral Sci.*, **2008**, *50*, 377-385.
- [37] Gonzalez-Moles, M.A. The use of topical steroids in oral pathology. *Med. Oral Patol. Oral Cir. Bucal.*, **2010**, *16*, 827-831.
- [38] Ramadas, A.A.; Jose, R.; Arathy, S.L.; Kurup, S.; Chandy, M.L.; Kumar, S.P. Systemic absorption of 0.1% triamcinolone acetonide as topical application in management of oral lichen planus. *Indian J. Dent. Res.*, **2016**, *27*(3), 230-235.
- [39] Lodi, G.; Carrozzo, M.; Furness, S.; Thongprasom, K. Interventions for treating oral lichen planus. *Cochrane Database Syst. Rev.*, **2011**, *7*, CD001168.
- [40] Farhi, D.; Dupin, N. Pathophysiology, etiologic factors, and clinical management of oral lichen planus, part I: Facts and controversies. *Clin Dermatol.*, **2010**, *28*, 100-108.
- [41] Conrotto, D.; Carbone, M.; Carrozzo, M.; Arduino, P.; Broccoletti, R.; Pentenero, M.; Gandolfo, S. Ciclosporin vs clobetasol in the topical management of atrophic and erosive oral lichen planus: A double-blind, randomized controlled trial. *Br. J. Dermatol.*, **2006**, *154*, 139-145.
- [42] Yoke, P.C.; Tin, G.B.; Kim, M.J.; Rajaseharan, A.; Ahmed, S.; Thongprasom, K.; Chaimusik, M.; Suresh, S.; Machin, D.; Bee, W.H.; Seldrup, J. A randomized controlled trial to compare steroid with cyclosporine for the topical treatment of oral lichen planus. *Oral Surg. Oral Med. Oral Pathol. Oral Radiol. Endod.*, **2006**, *102*, 47-55.

- [43] Guo, C.L.; Zhao, J.Z.; Zhang, J.; Dong, H.T. Efficacy of topical tacrolimus for erosive oral lichen planus: A meta-analysis. *Chin. Med. Sci. J.*, **2015**, *30*(4), 210-217.
- [44] Resende, J.P.M.; Chaves, M.D.G.A.M.; Aarestrup, F.M.; Aarestrup, B.V.; Olate, S.; Netto, H.D. Oral lichen planus treated with tacrolimus 0.1%. *Int. J. Clin. Exp. Med.*, **2013**, *6*(10), 917-921.
- [45] Ribero, S.; Stieger, M.; Quaglino, P.; Hongang, T.; Bornstein, M.M.; Naldi, L.; Borradori, L. Efficacy of topical tacrolimus for oral lichen planus: real-life experience in a retrospective cohort of patients with a review of the literature. *J. Eur. Acad. Dermatol. Venereol.*, **2015**, *29*, 1107-1113.
- [46] Radfar, L.; Wild, R.C.; Suresh, L. A comparative treatment study of topical tacrolimus and clobetasol in oral lichen planus. *Oral Surg. Oral Med. Oral Pathol. Oral Radiol.*, **2008**, *105*(2), 187-193.
- [47] Sonthalia, S.; Singal, A. Comparative efficacy of tacrolimus 0.1% ointment and clobetasol propionate 0.05% ointment in oral lichen planus: a randomized double-blind trial. *Int. J. Dermatol.*, **2012**, *51*, 1371-1378.
- [48] Malik, U.; Gupta, S.; Malik, S. D.; Vashishth, S.; Zaheeruddin, R.M.S. Treatment of symptomatic oral lichen planus (OLP) with 0.1% tacrolimus powder in Oraguard-B - A pilot prospective study. *Saudi. Dent. J.*, **2012**, *24*, 143-148.
- [49] Shipley, C.A.; Spivakovsky, S. Tacrolimus or clobetasol for treatment of oral lichen planus. *Evid. Based. Dent.*, **2016**, *17*(1), 16.
- [50] Kvaal, S.I.; Angell-Petersen, E.; Warloe, T. Photodynamic treatment of oral lichen planus. *Oral Surg. Oral Med. Oral Pathol. Oral Radiol.*, **2013**, *115*, 62-70.
- [51] Yang, H.; Wu, Y.; Ma, H.; Jiang, L.; Zeng, X.; Dan, H.; Zhou, L.C.Q. Possible alternative therapies for oral lichen planus cases refractory to steroid therapies. *Oral Surg. Oral Med. Oral Pathol. Oral Radiol.*, **2016**, *121*(5), 496-509.
- [52] Sobaniec, S.; Bernaczyk, P.; Pietruski, J.; Cholewa, M.; Skurska, A.; Dolinska, E.; Duraj, E.; Takajuk, G.; Paniczko, A.; Olszewska, E.; Pietruska, M. Clinical assessment of the efficacy of photodynamic therapy in the treatment of oral lichen planus. *Lasers Med. Sci.*, **2013**, *28*(1), 311-316.
- [53] Al-Maweri, S.A.; Kalakonda, B.; Al-Soneidar, W.A.; Al-Shamiri, H.M.; Alakhali, M.S.; Alaizari, N. Efficacy of low-level laser therapy in management of symptomatic oral lichen planus: A systematic review. *Lasers. Med. Sci.*, **2017**, *32*, 1429-1437.
- [54] Spanemberg, J.C.; de Figueiredo, M.A.Z.; Cherubini, K.; Salum, F.G. Low-level laser therapy: A review of its applications in the management of oral mucosal disorders. *Altern. Ther. Health Med.*, **2016**, *22*(6), 24-31.
- [55] Singh, V.; Pal, M.; Gupta, S.; Tiwari, S.K.; Malkunje, L.; Das S. Turmeric – a new treatment option for lichen planus: A pilot study. *Natl. J. Maxillofac. Surg.*, **2013**, *4*(2), 198-201.
- [56] Chainani-Wu, N.; Silverman, S. Jr.; Reingold, A.; Bostrom, A.; McCulloch, C.; Lozada-Nur, F. A randomized, placebocontrolled, double-blind clinical trial of curcuminoids in oral lichen planus. *Phytomedicine*, **2007**, *14*, 437-446.
- [57] Chainani-Wu, N.; Madden, E.; Lozada-Nur, F.; Silverman, S. High-dose curcuminoids are efficacious in the reduction in symptoms and signs of oral lichen planus. *J. Am. Acad. Dermatol.*, **2012**, *66*, 752-760.
- [58] Petrucci, M.; Lucchese, A.; Lajolo, C.; Lauritano, D.; Serpico, R. Topical retinoids in oral lichen planus treatment: An overview. *Dermatology*, **2013**, *226* (1), 61-67.
- [59] Scardina, G.A.; Messina, P.; Carini, F.; Maresi, E. A randomized trial assessing the effectiveness of different concentrations of isotretinoin in the management of lichen planus. *Int. J. Oral Maxillofac. Surg.*, **2006**, *35*, 67-71.
- [60] Dalirsani, Z.; Taghavi, Z. A.; Mehdipour, M.; Alavi, F.; Javazadeh, Y. Comparison of the effect of combination of triamcinolone acetone and vitamin a mouthwash with triamcinolone mouthwash alone on oral lichen planus. *J. Dent. Res. Dent. Clin. Dent. Prospects.*, **2010**, *4*, 21-24.
- [61] Rivas, T.N.; Requena, C.; Lombart, B.; Alcalá, R.; Serra, G.C.; Calomarde, L.; Nagore, E.; Guillén, C.; Sanmartín, O. Antimalarial drugs for the treatment of oral erosive lichen planus. *Dermatology*, **2016**, *232*(1), 86-90.
- [62] Axell, T.; Henriksen, B.M. Treatment of gingival lichen with free palatal grafts. *J. Oral Pathol. Med.*, **2007**, *36*, 105-109.